

# NUCLEAR MEDICINE APPROACHES FOR DEMENTIA

## Abstract

Nuclear medicine radiotracers and specific biomarkers for Alzheimer's disease (AD) and other degenerative dementias have been developed as a result of advances in the molecular biology, pathology, and genetics of these disorders. Dementia is among the neurodegenerative disorders. The gradual loss of a person's mental and cognitive abilities is a hallmark of dementia, a clinical condition and major neurocognitive disorder. These neurodegenerative illnesses can now be accurately and objectively diagnosed and evaluated because of advancements in neuroimaging. Very early detection of these diseases has been made possible by imaging and non-imaging markers, which have also significantly altered the criteria of these disorders. Dopamine transporter single photon emission computerized tomography (SPECT), which marks dopaminergic terminals, tau positron emission tomography (PET), which is a molecular imaging technique, and [F18] Fluorodeoxyglucose (FDG) PET, which shows the pattern of glucose metabolism in the brain, are all useful tools for the early recognition and differentiation of AD and its atypical variants, frontotemporal dementias, and dementia with Lewys bodies. While molecular imaging enables the visualization of altered function or abnormally elevated or decreased concentrations of disease-specific markers, high-spatial-resolution MRI enables the detection of subtle morphologic alterations, as well as potential consequences and alternate diagnoses. These approaches complement one another. An integrated, multimodal, multidisciplinary strategy is necessary for the proper workup and interpretation of diagnostic findings.

## Authors

### **Kamica Yadav**

Department of Pharmacy  
Starex University Gurugram  
Haryana, India

### **Prof. (Dr.) Arun Mittal**

SRM Modinagar College of Pharmacy  
SRMIST, Delhi- NCR Campus, Modi  
Nagar Ghaziabad, India.

### **Parveen Kumar Goyal**

Department of Pharmacy  
Panipat Institute of Engineering and  
Technology (PIET) Samalkha, Panipat  
Haryana, India.

### **Rupa Gupta**

Department of Pharmacy  
Sushant University, Gurugram  
Haryana, India.

**Keywords:** Dementia, Nuclear Medicine,  
Molecular imaging, neurodegenerative  
disorders.

## I. INTRODUCTION

Nuclear Medicine is a specified field of radiology in which Small doses of radioactive chemicals, or radiopharmaceuticals, are employed for diagnostic and therapeutic purposes [1]. In 1978, The harmless and efficient use of radioactive substances is the focus of the nuclear pharmacy, a subspecialty of pharmacy that was first introduced on behalf of the Board of Pharmaceutical Specializations. There are over a hundred radioactive employed for therapeutic applications, such as determining where tumors are located, the treatment of toxic diffuse goiter and hyperthyroidism, the reduction of bone pain caused by skeletal metastases, and cerebral perfusion. These radioactive medications are also used to diagnose renal failure and various infection imaging [2].

Single photon emission computed tomography (SPECT) examinations are a part of general nuclear medicine. While positron emission tomography (PET) and general nuclear medicine have some ideas in common, PET is a distinct modality that deserves its own examination, potentially comparable to magnetic resonance imaging (MRI) as an extension beyond basic X-ray principles [1]. There are many distinct radiopharmaceuticals with various targeting mechanisms, forms, and administration routes. They can be delivered as simple salts or coupled to more complicated compounds [3]. Radiopharmaceuticals can be administered in a variety of ways, including by mouth, by injection into the eyes, or both. About 95% of radiopharmaceuticals are utilized for diagnostic purposes, and the remaining 5% are used for therapeutic purposes [2].

The radiopharmaceuticals provide a minimally intrusive, low-side-effect approach of guiding therapeutic radiations. Additionally, radioactive medications serve as non-invasive imaging agents for diagnostics, providing details on the composition and functionality of diseased organs and tissues [4]. In order to image infections, a variety of radiopharmaceuticals are now used. Each is chosen depending on the clinical situation and the suitability of the patient. The following is a summary of the most frequently used radiotracers.

- Indium-111
- Technetium-99m
- Gallium-67 ( $^{67}\text{Ga}$ )
- FGD PET/CT

A wide range of diagnostic possibilities is made possible by the variety of isotopic formulations employed in NM. Notably, when cross-sectional imaging is insufficiently specific and/or sensitive for diagnosis, NM investigations are distinctly instructive [5]. Rubidium is a naturally occurring chemical and a micronutrient, like selenium. It would be helpful to compare the amounts of rubidium in biological samples between cancer patients and healthy control patients in order to judge its anticancer effectiveness. It is also crucial to understand how rubidium is used as a biomarker in risk assessment. Rubidium is eliminated through the urine, and the amount of Rubidium in the urine is a reliable sign that someone has been exposed to it. Rubidium is eliminated through the urine, and urine concentration is a reliable measure of Rubidium exposure. The acid toxins that were seeping out of the tumor mass were neutralized, making them harmless. This is because the poison was neutralized by Rubidium salts found in the bodily fluids In comparison to individuals who are healthy

controls, colorectal patients have significantly lower levels of rubidium in their whole blood. Little rubidium is present in the patient's serum or urine because the tumor sucked up the Rubidium [6].

Dementia is among the neurodegenerative disorders. The gradual loss of a person's mental and cognitive abilities is a hallmark of dementia, a clinical condition and major neurocognitive disorder. The gradual, enduring, and progressive nature of dementia symptoms has been acknowledged. 90% of dementia patients have a cognitive impairment, which makes them more likely to display behavioral and psychological symptoms like psychosis, violence, agitation, and depression [7].

Since a few years ago, it has been seen that cases of dementia at a young start are increasingly being recognized. Dementia is often an illness that affects older individuals, and it is a major cause of dependency and disability among the older population. Forecasts call for mostly rapid growth in the proportion and quantity of elderly people in nations like China, India, and Latin America. According to estimates, by 2050 there will be 1.25 billion more individuals over the age of 60, or 22% of the world's population, with 79% of them residing in less developed parts of the world [8]. The most common type of dementia is caused by a neurodegenerative disorder such as AD, PD, HD, or Amyotrophic Lateral Sclerosis (ALS), and Vascular Cognitive Impairments (VCI) are another type of dementia. These diseases frequently coexist with neurodegenerative dementia [9].

All forms of cognitive disorder associated with cerebrovascular disease are referred to as vascular cognitive impairment resulting in structural and functional connectivity loss, compromising functional networks within the brain. Vascular dementia has overtaken AD as the second most common type of dementia [10]. Drugs that target diseases in their early stages may potentially benefit patients the most. This emphasizes how crucial it is to make a proper clinical diagnosis early on in the course of the disease. Lifetime "probable" diagnosis can be made with a fair amount of accuracy if done carefully and in accordance with established clinical standards. Only postmortem, following necropsy, can a definitive diagnosis of Alzheimer's disease (AD) or the majority of other disorders that cause dementia be made [11].

It has been demonstrated that neuropathological characteristics, which eventually contribute to the clinical picture of dementia, may be present as early as 20 years before the first symptoms become overt. Neuropathology develops gradually. Therefore, a diagnosis cannot be made based solely on clinical criteria until the disease has progressed to a rather advanced stage. It is obvious that there is a need for sensitive and trustworthy biologic indicators that can show the presence of neuropathology before a patient has progressed to the stage of clinical dementia. Although there are currently no biomarkers that can definitively identify AD or the majority of other dementias, neuroimaging, and laboratory indicators may help to support the existence of neuropathology [11].


Clinical, psychiatric, and neurological evaluations, psychometric tests, and anatomic imaging, such as computed tomography, are all part of the conventional diagnostic process for AD. The ability to identify and track age- and disease-related changes in the human brain by neuroimaging with radiopharmaceuticals is a unique capability that aids in the study of the pathophysiology of dementia [12]. However, there is ongoing debate concerning the use of

using functional brain imaging techniques like positron emission tomography (PET) and single photon computed tomography (SPECT) to routinely diagnose Alzheimer's disease [13].

These neurodegenerative illnesses can now be accurately and objectively diagnosed and evaluated because of advancements in neuroimaging. High-resolution MRI is frequently available, enabling detailed analysis of occasionally subtle structural changes. Additionally, nuclear medicine's use of pathophysiology-specific radiotracers enables visualization of the underlying mechanisms of these disease processes. Early diagnosis can be obtained by integrating the clinical presentation with complementing radiologic and nuclear medicine techniques. This gives patients and their families the chance to confront the disease and begin earlier care [14]. In this chapter, we overview the role of nuclear medicine approaches to dementia.

## II. TYPES OF BRAIN IMAGING

The types of brain imaging are listed below [15].



**1. Structural Imaging in Dementia:** Structural imaging describes methods that are focused on analyzing and visualizing the anatomical characteristics of the brain. For finding brain injury and anomalies, structural techniques are especially helpful. Additionally, investigations can be done to calculate geometric structural features like a particular structure's size and volume or the thickness of a cortical region [15]. The objective of structural imaging is to identify curable disorders like tumors and Normal Pressure Hydrocephalus (NPH), as well as cerebrovascular conditions crucial to cognition impairment, like infarcts and hemorrhages. In these situations, computed tomography was the first method that was consistently employed. [16].

According to the Swedish national guidelines for health and welfare in dementia, dementia examinations are divided into two phases, basic dementia investigation, and extended investigation. Since patients with cognitive failure typically initially visit primary care, the majority of fundamental examinations are conducted there. The first investigation strongly emphasises and suggests a CT of the skull. It is recommended that an MRI be performed during the protracted dementia inquiry, which is frequently carried out at a memory clinic, either in addition to or instead of a CT. It is advised to perform an MRI in addition to or instead of a CT scan [17]. Structural imaging can enhance differential diagnosis by evaluating atrophy both regionally and globally, the presence of

vascular damage, and the presence of curable diseases (tumors and NPH) and cerebrovascular injury (hemorrhages and severe infarcts) [18]. As a result, in primary care, a CT can provide a fairly accurate picture of the patient's brain structure, and effective radiological assessment and consequently differential diagnostic reasoning are also made possible [17].

The contrast between the white and grey matter in the MRI scans is superior to that in the computed tomography pictures. As a result, examination of smaller brain regions is more difficult than it is with MRI. Evaluation of structures near the bone, such as those around the skull's base, is more difficult with CT. The lack of automated image analysis methods equivalent to those used in MRI represents a significant drawback as well. This is because the grey and white matter must be distinguished clearly in these techniques, which CT cannot do. Studies on structural imaging in dementia have focused a lot of emphasis on MRI and Alzheimer's disease [19].

Since CT is less noisy, the examination takes only a few seconds as opposed to the MRI's tens of minutes, and the patient can lie more comfortably, it is superior to MRI for elderly patients with cognitive impairment. Today, it is possible to reconstruct the coronary parts of CT scans, making it able to evaluate disorders such medial temporal lobe atrophy similarly to MRI. MRI makes it straightforward to detect even minute changes, such as hyper-intense variations in FLAIR pictures. Cerebrovascular abnormalities can be easily recognised with MRI. In a 2001 study, it was demonstrated that MRI was superior at identifying mild injuries when compared to visual evaluation of white matter damage and age-related white matter changes, in visual estimation of white matter damage. There was high agreement between estimates for bigger injuries [17].

Alzheimer's disease patients , who underwent PET by 18-fluorodeoxyglucose (18FDG) displayed the characteristic pattern of diminished cortical uptake in the posterior and lateral temporal areas, medial parietal regions, particularly in the posterior cingulate gyrus and precuneus, and medial temporal lobes, including the hippocampus [20]. PET shows aberrant uptake in AD patients when it uses insoluble fibrillar A-targeting tracers, such as the best studied Pittsburgh Compound-B (PiB) and more recently found fluorine-18-labeled tracers, florbetaben, florbetapir, and flutemetamol. While the occipital cortex, globus pallidus, and thalamus displayed dramatically reduced tracer uptake, the prefrontal cortex, precuneus, posterior cingulate cortex, lateral parietal and temporal cortex, and striatum displayed high uptake [21].

- 2. Systematic Assessment of Structural Imaging:** In addition to excluding surgical pathology, structural MRI in patients with suspected dementia should be thoroughly assessed with reference to signal change on MRI and brain atrophy. The assessment of signal change with T2-weighted imaging or fluid-attenuated inversion recovery (FLAIR) can show inflammatory, metabolic, toxic, or viral processes that may be producing cognitive deficits in addition to aiding to identify vascular injury. According to pathology research, the presence of brain shrinkage and its topographical structure can positively predict dementia. [22].

### III. FUNCTIONAL IMAGING

Functional neuroimaging techniques can be used to examine how illness or brain damage affects cognition- and behavior-related brain systems as well as how treatment alters these systems. These include transcranial magnetic stimulation (TMS), electroencephalography (EEG), magnetoencephalography (MEG), near-infrared spectroscopy (NIRS), and functional magnetic resonance imaging (fMRI) [23]

Estimating brain activity is the first step in functional imaging. Both magnetoencephalography (MEG) and electroencephalography (EEG), which measure changes in magnetic fields linked with changes in electrical activity, have limitations as methods for assessing neural activity. EEG records changes in electrical activity as clusters of neurons become active. It is difficult to detect changes in magnetic or electrical fields in the deep brain due to its structural complexity. These techniques have a number of limitations, but they do provide real-time assessments of brain cluster activity. It is difficult to monitor changes in magnetic or electrical activity in the deep brain because of its architecture [24].

Changes in metabolism occur when neurons become active because they need energy to function. In order to quantify these metabolic changes as a substitute for neural activity, another type of functional imaging is used. Fluorodeoxyglucose (FDG) has been tagged with a positron-emitting isotope ( $^{18}\text{F}$ ) or with a positron-emitting isotope of oxygen ( $^{15}\text{O}$ ) in order to measure regional metabolic changes using positron emission tomography (PET). In reality, it takes several minutes to absorb enough labeled glucose to assess metabolic activity, and it has been difficult to measure oxygen metabolism [25].

### IV. POSITRON EMISSION TOMOGRAPHY

The accurate and sensitive method for visualizing molecular interactions and routes within the human body is positron emission tomography (PET). The variety of positron-emitting radionuclides, which can be utilized to label particular biomarkers, biochemical, and medications without impairing their biological function, is what gives the specificity. Furthermore, the radiation generated from a radiolabeled tracer is unique to that tracer and may be seen above the negligible background radiation from natural sources. The requirements to account for the effect of scatter and the attenuation of photons by tissue are the key confounding issues [26].

These two elements are necessary for the tracer concept, for which George de Hevesy won the 1943 Nobel Prize in Chemistry. PET, which depends on two factors, can detect the tracer's low molecular mass. The ability of radiochemistry to produce labelled compounds with high specific activity—measured radioactivity per gramme of chemical—enables a large portion of the injected substance to be radiolabeled. The second factor is the capability of coincidence counting to discover and identify positron-emitting nuclei in order to gather the paired annihilation photons generated following positron annihilation with an electron [26].

**1. Detectors in Positron Emission Tomography:** The detectors in a PET scanner play a crucial role in the system because they are in charge of both absorbing the 511 keV photons and accurately reporting the position of the interaction, the energy of the detected photon, and the time of interaction—all of which are important factors affecting the

scanner's overall sensitivity, spatial resolution, ability to reject random and scatter events, and time-of-flight capabilities [27].

There are essentially two categories that can be used to categorize the detection technique for identifying the incoming annihilation photons:

- Indirect Detection
- Direct Detection

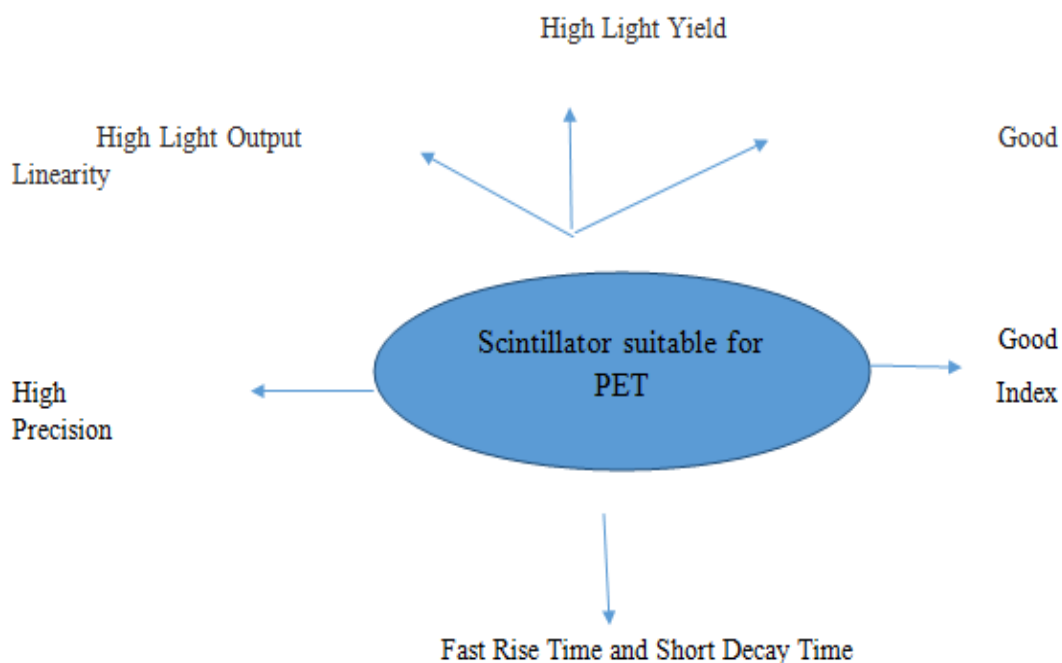
Each incoming annihilation photon interacts with the scintillation crystal during indirect (scintillation) detection through photoelectric or Compton scatter interactions. Using one or more photodetectors, the deposited energy is first transformed into a stream of visible (lower-energy) light photons, and subsequently into an electrical current. Every PET system that is now on the market in the commercial sector uses this detection technique. In direct detection, semiconductor crystals are used to transform each incoming photon interaction directly into electrical signals. This approach has been explored only in research [28].

- 2. Indirect Detection Method (Scintillation Detection):** Each 511-keV annihilation photon that enters a scintillation detector for PET interacts with the inorganic crystal by Compton scatter or the photoelectric action to produce a recoil electron that is immediately expelled. Through coulombic interactions, each ejected electron moves through the material and ionizes it, leaving a trail of secondary electrons that are released from the crystal's inherent electrical valence band and moved into the conduction band. The resulting ionization charge is transformed into a flash of isotropically emitted visible light through a subsequent de-excitation process in which those excited electrons sink into accessible energy levels of the host crystal or those of an added impurity. The photodetector element, which captures light and transforms it into an electrical signal, is connected to the crystal, and readout electronics come next [29].

Inorganic scintillation materials should have a high effective atomic number ( $Z_{\text{eff}}$ ), a high density, and quick rise and decay durations for the resulting signals for the best coincidence timing resolution. A modest concentration of an impurity known as an activator is introduced to the inorganic scintillation crystal, with the exception of a few intrinsic scintillators like bismuth germanium oxide (BGO), to help with the production of visible-light photons (i.e., optical photons) [30]. Discrete array and monolithic crystal configurations are the two most popular types utilised in PET detectors. There are no inter-element gaps since the monolithic scintillator design, which is currently only used to one commercial scanner model, consists of a sizable single piece of scintillation material. The majority of discrete crystal arrays used in commercial PET scanners are made up of an array of small, individual scintillation elements in the form of a matrix [31].

A Scintillator suitable for PET should have the properties are depicted in figure 2 [32].





**Figure 1:** The properties of the Scintillator suitable for PET

**3. Direct Detection Method:** PET is now researching the use of semiconductor detectors, which are frequently employed in the field of radiation detection for the direct conversion of incoming radiation into electrical signals (without the intermediate process of generation, transport, and collection of light) [33]. The 511-keV photon interaction physics in semiconductor photon detectors is identical to the indirect detection (scintillation) situation, in which the ionising interactions produce a track of electron-hole pairs.. The procedure for signal creation and collecting, however, differs. In a semiconductor detector, mobile charge carriers drift towards and induce a current on either electrode under the effect of an applied bias voltage on electrodes placed on opposite sides of the crystal (electrons drift towards the anode while holes drift towards the cathode) [34].

Aside from charge-attenuating effects, the overall induced charge on each electrode is determined by the integral of the induced current over time, and this charge is directly proportional to the energy of the 511-keV photon interaction. Electronic circuitry with great sensitivity and low noise is used to read the resulting current signal [31].

## V. ADVANCES OF NUCLEAR MEDICINE IN DEMENTIA

A devastating set of ailments known as neurodegenerative diseases can be challenging to correctly identify. An early and accurate diagnosis can help in managing symptoms and coping with these disease processes in their later stages, despite the fact that many disorders are challenging to manage due to the relatively few therapeutic options available. Both physiologic molecular imaging and anatomic structural imaging have advanced to the point where it is now possible to accurately and early detect these neurodegenerative processes [35].

The radiologist should be aware of the various distributions and pathophysiologic processes involved in order to identify the underlying disease. While molecular imaging enables the visualization of altered function or abnormally increased or decreased concentration of disease-specific markers, high-spatial-resolution MRI enables the detection of subtle morphologic alterations, as well as potential consequences and alternate diagnosis. These approaches complement one another. An integrated, multimodal, multidisciplinary strategy is necessary for the proper workup and interpretation of diagnostic findings [36].

Clinical and neuropsychological evaluation, structural imaging should be recommended as a first step because it enables the identification of additional pathologies that may be responsible for cognitive decline, aids in determining the presence and severity of co-morbidities, and is related to both topographical patterns and the degree of atrophy with particular neurodegenerative conditions and their severity. However, compared to, say, FDG-PET for neurodegeneration, sensitivity is lower and specificity is worse, therefore additional biomarker testing is frequently needed [37].

**1. PET imaging in dementia:** A normal FDG-PET scan would suggest clinical stability while an abnormal FDG-PET would imply cognitive decline, regardless of the outcome of the amyloid tetramer, which has proven increased utility in predicting clinical outcomes in persons with MCI and positive amyloid-PET. People with MCI and positive amyloid-PET have showed improved clinical outcome prediction with FDG-PET imaging [38].

The patterns of brain hypometabolism are distinct in different neurodegenerative illnesses, and they are helpful for disease staging and differential diagnosis since they are closely related to the kind and severity of cognitive deficits. Its fundamental drawback, however, is that the identified hypometabolism patterns prevent conclusive inferences about the underlying neuropathology. Only in circumstances when an FDG-PET pattern characteristic for a certain diagnosis is absent, where atypical AD is a possibility, or when the amyloid status is necessary might an amyloid-PET scan be recommended [39].

On the other hand, amyloid-PET imaging offers very high sensitivity and specificity non-invasive *in vivo* detection of amyloid plaques—one of the key neuropathological markers of AD. It is regarded as being extremely valuable in accurately determining the etiological diagnosis of AD in dementia patients, particularly clinically atypical types of AD [40]. On the other hand, a negative amyloid-scan can rule out AD as the cause of cognitive impairment. Amyloid imaging has been shown to change management in more than half of the patients tested in major prospective trials [42]. FDG-PET is thought to have higher specificity and better accuracy for short-term progression, while amyloid-PET is thought to have higher sensitivity than FDG-PET for predicting progression from MCI to AD dementia [42].

Amyloid imaging does not distinguish between discrete amyloid-positive illnesses, and roughly one-third of cognitively healthy older people have positive amyloid scans with unknown clinical significance [43].

**2. FDG-PET in Alzheimer's disease:** Due to distinctive patterns of hypo metabolism (lower FDG uptake), FDG-PET is a crucial tool in the early and differential diagnosis of

AD. Studies conducted in the past have shown that FDG-PET is 94% sensitive and 73% specific in detecting AD pathology. FDG-PET scans of the parietal-temporal association cortices, posterior cingulate, and precuneus have shown hypo metabolism in Amyloid plaque deposition and glucose metabolism has been studied in multimodal imaging investigations employing FDG and amyloid PET. Results from this research have been mixed, with some indicating a connection between local amyloid plaque load and hypometabolism. With a sensitivity of 89%, FDG-PET can help with the clinical diagnosis of FTLD utilizing a visual rating scale of brain metabolism. The early stages of AD [44].

- 3. Frontotemporal Lobar Degeneration (FTLD) spectrum in dementia:** Frontotemporal lobe degeneration (FTLD), which includes numerous different disorders including frontal and/or anterior temporal lobe degeneration as well as related dementia, is linked to aggregated tau, as well as Pick bodies. Semantic dementia, behavioral frontotemporal dementia (FTD), and progressive non-fluent aphasia are examples of frontotemporal lobar degenerative illnesses [45].

FDG-PET has a well-established role in the FTLD spectrum based on distinctive patterns of hypo metabolism linked to particular clinical syndromes, but amyloid-PET has shown promise in separating AD from FTLD since amyloid plaques are often not a component of the FTLD neuropathological spectrum. As a result, amyloid-PET is helpful when a differential diagnosis between AD and non-AD causes of dementia is required [46].

In contrast, FDG-PET can further address differential diagnosis within the FTLD spectrum in patients who are amyloid-negative. After amyloid-PET or CSF tests, it is still uncertain if PIB PET can be used to distinguish between FTD and AD because FTD patients do not retain PIB, according to PIB (Pittsburgh Compound-B) PET studies. The detection of frontotemporal lobe atrophy in PIB-positive patients may indicate a mimicking of AD disease. Furthermore, the diagnosis of semantic dementia from AD can be distinguished using amyloid PET imaging [47].

## VI. AMYLOID PET IMAGING

There are currently disease-specific PET tracers for clinical usage to distinguish between AD and MCI, such as tracers for amyloid-plaques to demonstrate or rule out brain amyloid burden; florbetapir (18F), florbetaben (18F), and flumemetal (18F) [48].

Over the past ten years, [<sup>11</sup>C] Pittsburgh Compound-B (PIB) has been the most frequently utilized PET tracer for amyloid imaging. However, [<sup>11</sup>C] PIB's limited clinical application is due to its short half-life, which necessitates an on-site cyclotron and manufacturing apparatus [49]. Because of their longer half-lives, second-generation <sup>18</sup>F-labelled amyloid tracers including <sup>18</sup>F-AV-45 (florbetapir), [<sup>18</sup>F] AZD4694, [<sup>18</sup>F] florbetaben, and [<sup>18</sup>F] flutemetamol have a larger potential to aid in the accurate identification of dementia disorders and the evaluation of disease-modifying therapy [50]. High-affinity PIB and 18F-labelled PET tracers bind to the fibrillary amyloid's "sheet structure," specifically binding to amyloid-peptide aggregates and no other misfolded proteins like tau or  $\alpha$ -synuclein [51].

Additionally, amyloid immunotherapies do not slow the progression of dementia unless they substantially reduce tau pathology. Thus, in a patient with MCI, amyloid deposition may have already peaked and plateaued by early AD [52]. In healthy-aged adults, there is amyloid deposition, thus AD is not the only condition that causes it. [<sup>11</sup>C] PIB According to PET scans, one-third of healthy older people exhibit increased amyloid accumulation [53].

## VII. AMYLOID IMAGING IN PARKINSONIAN DEMENTIA

In individuals with DLB and PDD, amyloid deposits measured with PIB-PET have been linked to AD-like atrophy. Early amyloid deposition in DLB may be responsible for dementia's early onset. Patients with DLB have a larger amyloid load than those with PDD, although it is not as high as the PIB levels seen in AD [54]. PDD can be distinguished from DLB by having a reduced overall amyloid plaque load. Typically, PIB binding in people with PDD is the same as it is in people with PD or in healthy people. However, it has been demonstrated that cortical PIB retention in PD can foretell cognitive impairment. Consequently, amyloid deposition may influence when dementia first appears in people with Lewy body diseases [55].

## VIII. TAU IMAGING IN ALZHEIMER'S DISEASE

For the first time, *in vivo* examination of tau pathology in dementias is now possible obligation to advancements in the production of PET tracers that are specific for tau. The THK series—[<sup>18</sup>F] THK523, [<sup>18</sup>F] THK5105, [<sup>18</sup>F] THK5117, and [<sup>18</sup>F] THK5351—as well as [<sup>18</sup>F] AV1451 (also known as [<sup>18</sup>F] T807) are examples of first-generation tau selective PET tracers [56]. Compared to amyloid- fibrils, these tau tracers have a greater propensity for binding to NFTs. First-generation tau tracers have limitations, though, because they bind to MAO-A/B off-target [57]. Additionally, even in cognitively normal patients, [<sup>18</sup>F] AV1451, [<sup>18</sup>F] THK5117, and [<sup>18</sup>F] THK5105 have significant retention in striatal regions. This is in contrast to neuropathological studies and could cause the tau burden in nearby cortical regions to be overestimated [58].

First-generation tau PET tracers mostly identify paired helical filaments with a mixture of 3- and 4-repeat tau isoforms, which are hallmarks of AD-like tau pathology [59]. According to autoradiography experiments, [<sup>18</sup>F] AV1451 binds less strongly in non-AD brains than it does in AD, raising questions about the potential of the compound to identify 4R-tau isoforms, which are prevalent in CBS and PSP [60].

Early PET investigations using [<sup>18</sup>F] THK523 revealed that AD patients had increased retention in the hippocampus, temporal, parietal, and orbitofrontal cortices compared to healthy controls [61]. However, [<sup>18</sup>F] THK523's significant white matter retention makes it difficult to accurately interpret signals visually, precluding usage in clinical or research contexts [62]. Higher binding affinities were demonstrated by [<sup>18</sup>F] THK5105 and [<sup>18</sup>F] THK5117 than [<sup>18</sup>F] THK523. PET experiments with enhanced derivatives, [<sup>18</sup>F] THK5105 and [<sup>18</sup>F] THK5117 showed binding in the temporal lobe that was unique from amyloid-PET imaging with PIB and clearly distinguished AD patients from healthy older participants [63]. The absorption of [<sup>18</sup>F] AV1451 in AD patients, according to *in vivo* investigations, is consistent with Braak staging. Therefore, it appears that tau aggregation is closely related to

patterns of neurodegeneration and clinical symptoms of AD, according to supportive evidence from post-mortem and animal studies [64].

It may be determined through additional research combining tau and amyloid-PET imaging if the buildup of amyloid initiates and expedites the spread of tau deposition outside the mesial temporal cortex. The [ $^{18}\text{F}$ ] PI-2620 preliminary data show unique uptake patterns in PSP compared to AD and high signals in brain areas with established tau pathology in AD. In pilot research with five AD patients and four healthy controls, [ $^{18}\text{F}$ ]MK-6240 was highly uptake in areas associated with NFT deposition, but tracer binding in healthy subjects was barely detectable [65].

## IX. TAU IMAGING IN PARKINSONIAN DEMENTIA

Tau PET imaging offers the potential to separate DLB from PD and other parkinsonian tauopathies according to patterns of tau disruption and shed light on how tau aggregates contribute to cognitive decline in these disorders [66]. Tau deposition in DLB, PSP, and CBS has so far been studied using PET imaging. CBS patients exhibit [ $^{11}\text{C}$ ] PBB3 uptake in neocortical and subcortical areas according to preliminary findings in PSP and CBS [67].

While *in vitro* research has demonstrated that [ $^{18}\text{F}$ ] AV1451 binds mostly to the paired helical filament (PHF) of 3R-tau in AD brains, autoradiography research has showed low but specific [ $^{18}\text{F}$ ] AV1451 binding in post-mortem CBS brains [68]. Studies using the tracer [ $^{18}\text{F}$ ] AV1451 have revealed retention patterns in CBS patients that are consistent with the known location of tau pathology, with significant uptake in the frontal and parietal cortices. In CBS patients, [ $^{18}\text{F}$ ] AV1451 uptake was higher on the side that had more parkinsonism and cortical dysfunction [69]. Tau pathology in CBS has also been investigated using PET with [ $^{18}\text{F}$ ] THK5351. In five CBS patients, frontal, parietal, and globus pallidus absorption of [ $^{18}\text{F}$ ] THK5351 was higher than in healthy controls, with higher binding on the side that was clinically the least affected [70].

Two studies that were recently published looked on the patterns of tau distribution in DLB patients. In comparison to healthy controls, DLB has been shown to have increased [ $^{18}\text{F}$ ] AV1451 uptake in the posterior temporoparietal, occipital cortex, and precuneus [71]. The medial temporal cortex's increased [ $^{18}\text{F}$ ] AV1451 uptake was able to differentiate between likely DLB and AD dementia [71]. Cross-sectional studies have also examined the absorption of [ $^{18}\text{F}$ ] AV1451 and [ $^{11}\text{C}$ ] PIB in patients with DLB in comparison to PD patients without cognitive impairments (PD-CI), PD patients with cognitively normal PD symptoms, and individuals with AD [72].

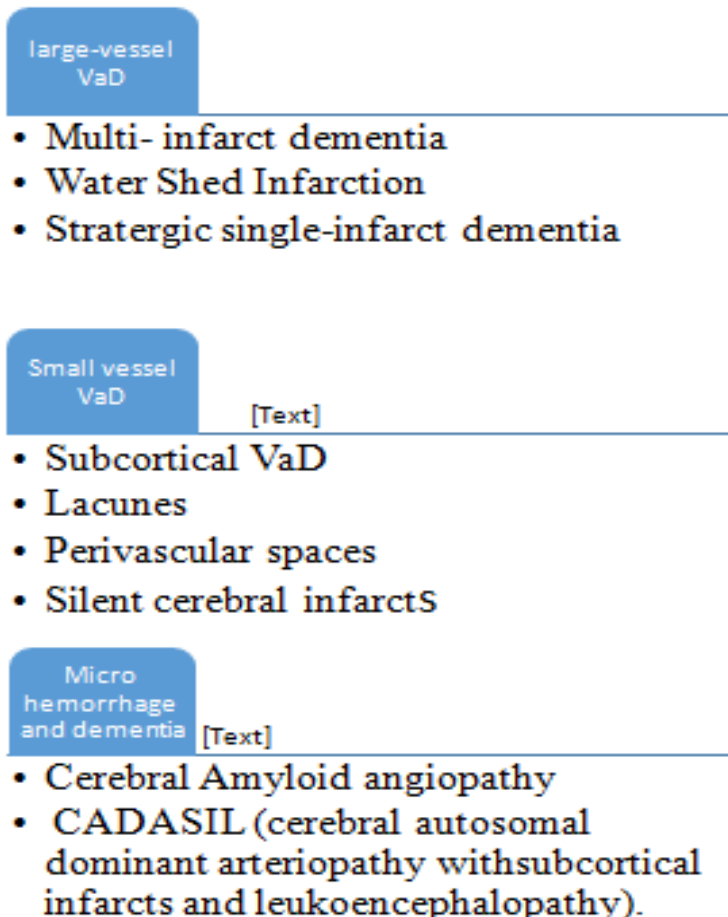
When compared to healthy controls, individuals with DLB and PD with cognitive impairment showed higher cortical [ $^{18}\text{F}$ ] AV1451 uptake, especially in the inferior temporal and precuneus regions [71]. The existence of tau deposits and a low amyloid load suggested that tau pathology is still feasible in DLB without the presence of amyloid. Additionally, in DLB and PD patients with cognitive impairment, higher [ $^{18}\text{F}$ ] AV1451 uptake but not [ $^{11}\text{C}$ ] PIB retention was connected with more severe cognitive impairment [72].

The white matter pathways analyzed by MRI with diffusion tensor imaging (DTI), which connects the hippocampus to the posterior cingulate gyrus, exhibit damage. Volumetric alterations can be found using structural scans, such as an MRI, in preclinical AD, MCI caused by AD, and AD patients with dementia. Increased grey matter atrophy can be visible on MRI, primarily in the cingulate and hippocampal regions, which are also where amyloid deposits have been found on an amyloid PET scan [74].

## X. FLUID-ATTENUATED INVERSION RECOVERY (FLAIR) IN VASCULAR DEMENTIA (VAD)

Following AD, VaD is the second most frequent cause of dementia. Stepwise cognitive decline with interspersed periods of stability and acute symptom deterioration are frequent characteristics[76]. The imaging appearance of VaD can be broadly divided following [76].

- Large-vessel VaD,
- Small-vessel VaD



**Micro Hemorrhage and Dementia:** Vascular insults in numerous small or big vessels over a lengthy period of time can be blamed for the pathogenesis. The vascular insult seen in both small vessel and big vessel illnesses is denoted by a hyper-intense signal on T2-weighted and

fluid-attenuated inversion recovery (FLAIR) imaging. Micro hemorrhages seen in VaD can also be found with T2/FLAIR imaging [77].

The imaging methods used to assess patients with VaD now include cross-sectional imaging with CT and MR as well as CT angiography or MR angiography. These diagnostic techniques are fairly accurate in determining the magnitude and site of both symptomatic and asymptomatic (silent) strokes [78]. Microbleeds, anoxic/hypoxic brain damage, and recognising the alterations of gliosis and encephalomalacia can all be diagnosed with great success using magnetic resonance imaging (MRI) [79]. MRI or CT perfusion techniques can also be used to determine the parenchymal perfusion status. The use of DWI-apparent diffusion coefficient (ADC) in the diagnosis of hyperacute infarction is well-established [80].

## XI. SPECT IMAGING IN DLB

DLB is a relatively prevalent type of dementia that can also manifest as parkinsonism, visual abnormalities, and neurocognitive deterioration. According to volumetric studies, DLB patients had higher retained hippocampus, amygdala, and temporal lobe volumes than AD patients. Patients with DLB exhibit considerably less uptake of FDG on FDG-PET in the visual cortex [81]. Performing a dopaminergic transporter (DAT) scan with a radiotracer like (123I) FP-CIT can be useful in evaluating dopaminergic function in DLB [82]. This demonstrates that DLB patients have much lower dopaminergic activity. The efficacy of 123I-metaiodobenzylguanidine (MIBG) cardiac scintigraphy in separating DLB from AD may be constrained by interference with results caused by co-existing heart diseases and diabetes mellitus [83].

With the help of medial temporal lobe uptake and a substantial difference in AV-1451 uptake between patients with AD and those with possible DLB, AD and probable DLB were entirely differentiable in a tau PET research utilizing 18F-flortaucipir (AV-1451) [84].

**Metabolic studies involved in DLB imaging:** By measuring metabolic activity in *in vivo* with the appropriate radiotracers, molecular imaging modalities such as single-photon emission tomography (SPECT) and fluorine-18-fluorodeoxyglucose positron emission imaging (FDG-PET) have been instrumental in understanding the complex pathophysiology of DLB [85]. In a study that also linked cerebral hypometabolism to visual hallucination symptoms, patients with DLB who experienced visual hallucinations had higher levels of hypo metabolism than those who did not—mostly in visual association areas as opposed to the primary visual cortex [86].

The cingulate island sign (CIS) in FDG-PET is also regarded by the Dementia with Lewy Bodies (DLB) Consortium as a positive indicator of DLB [87]. The posterior cingulate of patients with DLB has a brain metabolism that is relatively conserved when compared to individuals with Alzheimer's disease (AD), and it is also known that this metabolism has a negative link with the stages of Braak neurofibrillary tangles. Additionally, several research point to a link between CIS and visual complaints in DLB patients [88].

## XII. IMAGING INVOLVING DOPAMINERGIC ACTIVITY

Dopamine transporter (DAT) imaging with SPECT employing [123I] FP-CIT-SPECT or 2-carbomethoxy-3-(4-iodophenyl)-N-(3-fluoropropyl) nortropine as a radiotracer

can be used to evaluate dopaminergic activity [89]. This demonstrated that in striking contrast to both the AD and healthy control groups, people with DLB had considerably lower FP-CIT binding in the caudate and anterior and posterior putamens [90]. In comparison to the original clinical diagnosis, which had a sensitivity of 75% and specificity of 42%, a study found that an FP-CIT SPECT scan for DLB had a sensitivity of 88% and a specificity of 100% [91].

An abnormal [123I] FP- CIT-SPECT scan has a sensitivity of 77.7% for suspected DLB and a specificity of 90.4% for excluding other aetiologies of dementia that are unrelated to Lewy body pathology, according to a clinical investigation including 326 patients [92]. Furthermore, it has been observed that DLB patients had higher nigroputaminal fractional anisotropy (FA) values than AD or control groups [93].

Another study found that although the [123I] FP- CIT-SPECT scan is quite useful for differentiating between AD and DLB, it only has a 67% specificity when used in frontotemporal dementia (FTD) patients. The majority of DLB patients in this study did exhibit noticeably reduced DAT binding, but a third of the FTD group also displayed similar results [94].

### **XIII. I-METAIODOBENZYLGUANIDINE (MIBG) CARDIAC SCINTIGRAPHY**

Congestive heart failure, ischemic heart disease, coronary artery disease, vasospastic angina pectoris, and cardiomyopathy are some of the various cardiac disorders for which MIBG scintigraphy was initially created to evaluate postganglionic presynaptic cardiac sympathetic nerve terminals [95]. Decreased cardiac (123) I-Metaiodobenzylguanidine uptake has been linked to a number of illnesses with Lewy bodies, and studies have found that MIBG cardiac scintigraphy can effectively differentiate between Alzheimer's disease and dementia with Lewy bodies, two very frequent aetiologies of dementia [96].

I-metaiodopropylguanidine (123) cardiac scintigraphy can accurately differentiate between two groups of diagnoses: one consisting of AD, multiple system atrophy (MSA), progressive supranuclear palsy (PSP), vascular dementia (VaD), and frontotemporal dementia (FTD) patients are included. which are essentially non-Levy body-related conditions; and others include patients with Parkinson's disease (PD), dementia with Lewy bodies [97].

In a different study, the diagnostic value of the 123I-MIBG scan in DLB was reevaluated after a three-year follow-up following the initial diagnosis. It was found that both early and follow-up imaging of the presence of comorbidities like diabetes or cardiac disease can interfere with the 123I-MIBG scan and might produce false-positive results [98].

**I-Metaiodobenzylguanidine (MIBG) Cardiac Scintigraphy in Parkinson's Disease:** Even in individuals with very early PD, as identified by the Hoehn & Yahr (H&Y) staging method, who do not exhibit clinically significant symptoms or signs of autonomic dysfunction, MIBG uptake is reduced [99]. Reduced MIBG uptake can be a sign of how bad the disease will go in the end. These results imply that MIBG scintigraphy might be an effective PD detection method [100]. The H/M ratios in both the early and delayed photos tended to drop as the H&Y phases advanced, according to a study, however, this link was not statistically significant. The link between MIBG uptake and the PD phenotype was also demonstrated by MIBG scintigraphy [101].



In general, bradykinesia, rigidity, and axial symptoms such as speech, posture, and gait are negatively associated with MIBG uptake or H/M ratio [102]. However, a study on the predictive value of MIBG scintigraphy in relation to the severity and progression of Parkinson's motor symptoms suggested that MIBG scintigraphy does not predict the progression of other motor symptoms, such as resting tremor, postural tremor, and bradykinesia. Instead, it predicts the speed of progression on stiffness and axial symptoms [103].

Patients with PD may have numerous non-motor symptoms prior to developing motor symptoms. Pre-motor PD refers to PD cases that first present these non-motor symptoms, and these instances can also exhibit poor MIBG uptake, suggesting that this is a good measurement to identify PD in its preclinical stages [104]. In the clinical diagnosis of Parkinson's disease (PD), scans without evidence of dopaminergic deficiencies (SWEDDs) are described as instances with normal dopamine transporter scans. SWEDD cases can be difficult to diagnose and are frequently mistaken as PD [105]. Additionally, a recent study found that MIBG scintigraphy may be useful in separating patients with SWEDDs from those with PD [106].

#### **XIV. CONCLUSION**

Nuclear medicine and its many uses seem to have a significant impact on the diagnosis, categorization, management, and potential treatment of AD in the present and the future. According to recent estimates, the number of Americans who will be directly or indirectly affected by AD trauma is increasing at an alarming rate.

For those whose minds are prematurely taken from them, nuclear medicine can help in the diagnosis and prevention of AD. Patients, families, and society can be helped by nuclear medicine to avoid the dreadful toll that AD is predicted to have on the human race. For research and clinical usage, molecular and functional imaging techniques for Alzheimer's disease and other degenerative dementias are being developed at an accelerating rate. These imaging techniques can aid in early diagnosis, prognosis determination, and clinical clarification by demonstrating pathophysiological molecules of disease, detection of neurochemical changes, and physiological selectivity of disease-specific neurodegeneration. These imaging tests are critical for access to prompt and accurate diagnosis and effective treatment today when drugs are being rapidly developed aimed at slowing the progression of the disease.

#### **REFERENCES**

- [1] Pascoe AP, Kordatzakis A. Clinical Applications of Nuclear Medicine.
- [2] Alsharif SH, Alanazi MA, Alharthi FA, Qandil DA, Qushawy MO. Review about radiopharmaceuticals: preparation, radioactivity, and applications. *Int J App Pharm.* 2020;12(3):8-15.
- [3] Pauwels EK, McCready VR, Stoot JH, van Deurzen DF. The mechanism of accumulation of tumor-localizing radiopharmaceuticals. *Eur J Nucl Med* 1998;25:277–305.
- [4] Ferro Flores G, E Ocampo Garcia B, Melendez Alafort L. Development of specific radiopharmaceuticals for infection imaging by targeting infectious micro-organisms. *Curr Pharm Des* 2012;18:1098–106.
- [5] Sureshkumar A, Hansen B, Ersahin D. Role of nuclear medicine in imaging. In *Seminars in Ultrasound, CT and MRI* 2020 Feb 1 (Vol. 41, No. 1, pp. 10-19). WB Saunders.

- [6] Othman SA, Bakar NF, Azman NF, Jasrin NS. Future of nuclear medicine-an overview. In IOP Conference Series: Materials Science and Engineering 2019 Jun 1 (Vol. 555, No. 1, p. 012032). IOP Publishing.
- [7] Hsu, T. J.; Tsai, H. T.; Hwang, A. C.; Chen, L. Y.; Chen, L. K. Predictors of non-pharmacological intervention effect on cognitive function and behavioral and psychological symptoms of older people with dementia. *Geriatrics & gerontology is international*. **2017**, 17, 28-35.
- [8] Nichols, E.; Steinmetz, J. D.; Vollset, S. E.; Fukutaki, K.; Chalek, J.; Abd-Allah; Liu, X. Estimation of the global prevalence of dementia in 2019 and forecasted prevalence in 2050: an analysis for the Global Burden of Disease Study 2019. *The Lancet Public Health*. **2022**, 7(2), e105-e125.
- [9] Zotin, M. C. Z.; Sveikata, L.; Viswanathan, A.; Yilmaz, P. Cerebral small vessel disease and vascular cognitive impairment: from diagnosis to management. *Current Opinion in Neurology*. 2021, 34(2), 246.
- [10] Rosenberg, R. N.; Pascual, J. M.; (Eds.). *Rosenberg's Molecular and Genetic Basis of Neurological and Psychiatric Disease: Volume 1*. Academic press. 2020.
- [11] Lopez JA, González HM, Léger GC. Alzheimer's disease. *Handbook of clinical neurology*. 2019 Jan 1;167:231-55.
- [12] Gao S, Lima D. A review of the application of deep learning in the detection of Alzheimer's disease. *International Journal of Cognitive Computing in Engineering*. 2022 Jun 1;3:1-8.
- [13] Kowalewska B, Drozd W, Kowalewski L. Positron emission tomography (PET) and single-photon emission computed tomography (SPECT) in autism research: Literature review. *Irish Journal of Psychological Medicine*. 2021 Apr 5:1-5.
- [14] Patel KP, Wymer DT, Bhatia VK, Duara R, Rajadhyaksha CD. Multimodality imaging of dementia: clinical importance and role of integrated anatomic and molecular imaging. *Radiographics*. 2020 Jan;40(1):200-22.
- [15] Hirsch GV, Bauer CM, Merabet LB. Using structural and functional brain imaging to uncover how the brain adapts to blindness. *Annals of neuroscience and psychology*. 2015;2.
- [16] Wahlund LO. Structural brain imaging as a diagnostic tool in dementia, why and how?. *Psychiatry Research: Neuroimaging*. 2020 Dec 30;306:111183.
- [17] Lindeberg S, Samuelsson C, Müller N. Swedish clinical professionals' perspectives on evaluating cognitive and communicative function in dementia. *Clinical Gerontologist*. 2022 May 27;45(3):619-33.
- [18] Leinonen V, Vanninen R, Rauramaa T. Cerebrospinal fluid circulation and hydrocephalus. *Handbook of clinical neurology*. 2018 Jan 1;145:39-50.
- [19] Shenton ME, Hamoda HM, Schneiderman JS, Bouix S, Pasternak O, Rathi Y, Vu MA, Purohit MP, Helmer K, Koerte I, Lin AP. A review of magnetic resonance imaging and diffusion tensor imaging findings in mild traumatic brain injury. *Brain imaging and behavior*. 2012 Jun;6:137-92.
- [20] .. Bonifacio G, Zamboni G. Brain imaging in dementia. *Postgraduate medical journal*. 2016 Jun;92(1088):333-40.
- [21] Uzuegbunam BC, Librizzi D, Hooshyar Yousefi B. PET radiopharmaceuticals for Alzheimer's disease and Parkinson's disease diagnosis, the current and future landscape. *Molecules*. 2020 Feb 21;25(4):977.
- [22] Harper L, Barkhof F, Scheltens P, Schott JM, Fox NC. An algorithmic approach to structural imaging in dementia. *Journal of Neurology, Neurosurgery & Psychiatry*. 2014 Jun 1;85(6):692-8.
- [23] Busan P, Battaglini PP, Sommer M. Transcranial magnetic stimulation in developmental stuttering: Relations with previous neurophysiological research and future perspectives. *Clinical Neurophysiology*. 2017 Jun 1;128(6):952-64.
- [24] Mash LE, Reiter MA, Linke AC, Townsend J, Müller RA. Multimodal approaches to functional connectivity in autism spectrum disorders: an integrative perspective. *Developmental neurobiology*. 2018 May;78(5):456-73.
- [25] Barros LF, Bolanos JP, Bonvento G, Bouzier-Sore AK, Brown A, Hirrlinger J, Kasparov S, Kirchhoff F, Murphy AN, Pellerin L, Robinson MB. Current technical approaches to brain energy metabolism. *Glia*. 2018 Jun;66(6):1138-59.
- [26] Jones T, Townsend D. History and future technical innovation in positron emission tomography. *Journal of Medical Imaging*. 2017 Jan 1;4(1):011013-.
- [27] Kratochwil N, Gundacker S, Auffray E. A roadmap for solid Cherenkov radiators with SiPMs in TOF-PET. *Physics in Medicine & Biology*. 2021 Sep 21;66(19):195001.
- [28] Åkesson T, Berlin A, Blinov N, Colegrove O, Collura G, Dutta V, Echenard B, Hiltbrand J, Hitlin DG, Incandela J, Jaros J. Light dark matter eXperiment (LDMX). *arXiv preprint arXiv:1808.05219*. 2018 Aug 15.
- [29] Oliveira J, Correia V, Costa P, Francesko A, Rocha G, Lanceros-Mendez S. Stretchable scintillator composites for indirect X-ray detectors. *Composites Part B: Engineering*. 2018 Jan 15;133:226-31.

- [30] Gektin A, Korzhik M. Inorganic scintillators for detector systems. Berlin: Springer. 2017:20-77.
- [31] Gonzalez-Montoro A, Ullah MN, Levin CS. Advances in detector instrumentation for PET. *Journal of Nuclear Medicine*. 2022 Aug 1;63(8):1138-44.
- [32] Vandenberghe S, Mikhaylova E, D'Hoe E, Mollet P, Karp JS. Recent developments in time-of-flight PET. *EJNMMI physics*. 2016 Dec;3:1-30.
- [33] Kakavelakis G, Gedda M, Panagiotopoulos A, Kymakis E, Anthopoulos TD, Petridis K. Metal halide perovskites for high- energy radiation detection. *Advanced Science*. 2020 Nov;7(22):2002098.
- [34] Caramelo FJ, Guerreiro C, Ferreira NC, Crespo P. Radiation Detectors and Image Formation. In *Nuclear Medicine Physics 2016* Apr 19 (pp. 145-220). CRC Press.
- [35] Samim A, Tytgat GA, Bleeker G, Wenker ST, Chatalic KL, Poot AJ, Tolboom N, van Noesel MM, Lam MG, de Keizer B. Nuclear medicine imaging in neuroblastoma: current status and new developments. *Journal of Personalized Medicine*. 2021 Apr 4;11(4):270.
- [36] Patel KP, Wymer DT, Bhatia VK, Duara R, Rajadhyaksha CD. Multimodality imaging of dementia: clinical importance and role of integrated anatomic and molecular imaging. *Radiographics*. 2020 Jan;40(1):200-22.
- [37] Rahman MM, Mim SA, Islam MR, Parvez A, Islam F, Uddin MB, Rahaman MS, Shuvo PA, Ahmed M, Greig NH, Kamal MA. Exploring the recent trends in management of dementia and frailty: focus on diagnosis and treatment. *Current Medicinal Chemistry*. 2022 Oct 1;29(32):5289-314.
- [38] Iaccarino L, Chiotis K, Alongi P, Almkvist O, Wall A, Cerami C, Bettinardi V, Gianolli L, Nordberg A, Perani D. A cross-validation of FDG-and amyloid-PET biomarkers in mild cognitive impairment for the risk prediction to dementia due to Alzheimer's disease in a clinical setting. *Journal of Alzheimer's Disease*. 2017 Jan 1;59(2):603-14.
- [39] Chételat G, Arbizu J, Barthel H, Garibotto V, Law I, Morbelli S, van de Giessen E, Agosta F, Barkhof F, Brooks DJ, Carrillo MC. Amyloid-PET and 18F-FDG-PET in the diagnostic investigation of Alzheimer's disease and other dementias. *The Lancet Neurology*. 2020 Nov 1;19(11):951-62.
- [40] Ni R, Chen Z, Shi G, Villos A, Zhou Q, Arosio P, Nitsch RM, Nilsson KP, Klohs J, Razansky D. Transcranial in vivo detection of amyloid-beta at single plaque resolution with large-field multifocal illumination fluorescence microscopy. *bioRxiv*. 2020 Feb 2:2020-02.
- [41] Chételat G, Arbizu J, Barthel H, Garibotto V, Lammertsma AA, Law I, Morbelli S, van de Giessen E, Drzezga A. Finding our way through the labyrinth of dementia biomarkers. *European Journal of Nuclear Medicine and Molecular Imaging*. 2021 Jul;48:2320-4.
- [42] Ottoy J, Niemantsverdriet E, Verhaeghe J, De Roeck E, Struyfs H, Somers C, Ceyskens S, Van Mossevelde S, Van den Bossche T, Van Broeckhoven C, Ribbens A. Association of short-term cognitive decline and MCI-to-AD dementia conversion with CSF, MRI, amyloid-and 18F-FDG-PET imaging. *NeuroImage: Clinical*. 2019 Jan 1;22:101771.
- [43] Dubois B, Hampel H, Feldman HH, Scheltens P, Aisen P, Andrieu S, Bakardjian H, Benali H, Bertram L, Blennow K, Broich K. Preclinical Alzheimer's disease: definition, natural history, and diagnostic criteria. *Alzheimer's & Dementia*. 2016 Mar 1;12(3):292-323.
- [44] Alavi A, Barrio JR, Werner TJ, Khosravi M, Newberg A, Høiland-Carlson PF. Suboptimal validity of amyloid imaging-based diagnosis and management of Alzheimer's disease: why it is time to abandon the approach. *European Journal of Nuclear Medicine and Molecular Imaging*. 2020 Feb;47:225-30.
- [45] Mann DM, Snowden JS. Frontotemporal lobar degeneration: Pathogenesis, pathology and pathways to phenotype. *Brain Pathology*. 2017 Nov;27(6):723-36.
- [46] Ricci M, Cimini A, Chiaravalloti A, Filippi L, Schillaci O. Positron emission tomography (PET) and neuroimaging in the personalized approach to neurodegenerative causes of dementia. *International Journal of Molecular Sciences*. 2020 Oct 11;21(20):7481.
- [47] Nobili FL, Arbizu J, Bouwman F, Drzezga A, Agosta F, Nestor P, Walker Z, Boccardi M. EANM-EAN recommendations for the use of brain 18 F-Fluorodeoxyglucose Positron Emission Tomography (FDG-PET) in neurodegenerative cognitive impairment and dementia: Delphi consensus. *European Journal of Neurology*. 2018;25(10):1201-17.
- [48] Krishnadas N, Villemagne VL, Doré V, Rowe CC. Advances in brain amyloid imaging. In *Seminars in nuclear medicine 2021* May 1 (Vol. 51, No. 3, pp. 241-252). WB Saunders.
- [49] Lowe VJ, Lundt ES, Senjem ML, Schwarz CG, Min HK, Przybelski SA, Kantarci K, Knopman D, Petersen RC, Jack CR. White matter reference region in PET studies of 11C-Pittsburgh compound B uptake: effects of age and amyloid- $\beta$  deposition. *Journal of Nuclear Medicine*. 2018 Oct 1;59(10):1583-9.
- [50] Thientunyakit T, Sethanandha C, Muangpaisan W, Chawalparit O, Arunrungvichian K, Siriprapa T, Thongpraparn T, Chanachai R, Gelovani J. Implementation of [18F]-labeled amyloid brain PET imaging

- biomarker in the diagnosis of Alzheimer's disease: first-hand experience in Thailand. *Nuclear Medicine Communications*. 2018 Feb 1;39(2):186-92.
- [51] Declercq L, Celen S, Lecina J, Ahamed M, Tousseyn T, Moechars D, Alcazar J, Ariza M, Fierens K, Bottelbergs A, Mariën J. Comparison of new tau PET-tracer candidates with [18F] T808 and [18F] T807. *Molecular imaging*. 2016 Jan 14;15:1536012115624920.
- [52] Rahimi F, Li H, Sinha S, Bitan G. Modulators of amyloid  $\beta$ -protein ( $A\beta$ ) self-assembly. In *Developing Therapeutics for Alzheimer's Disease* 2016 Jan 1 (pp. 97-191). Academic Press.
- [53] Knezevic D, Verhoeff NP, Hafizi S, Strafella AP, Graff-Guerrero A, Rajji T, Pollock BG, Houle S, Rusjan PM, Mizrahi R. Imaging microglial activation and amyloid burden in amnesic mild cognitive impairment. *Journal of Cerebral Blood Flow & Metabolism*. 2018 Nov;38(11):1885-95.
- [54] Villemagne VL, Doré V, Burnham SC, Masters CL, Rowe CC. Imaging tau and amyloid- $\beta$  proteinopathies in Alzheimer disease and other conditions. *Nature Reviews Neurology*. 2018 Apr;14(4):225-36.
- [55] Delgado- Alvarado M, Gago B, Navalpotro- Gomez I, Jiménez- Urbietta H, Rodríguez- Oroz MC. Biomarkers for dementia and mild cognitive impairment in Parkinson's disease. *Movement Disorders*. 2016 Jun;31(6):861-81.
- [56] Wang YT, Edison P. Tau imaging in neurodegenerative diseases using positron emission tomography. *Current neurology and neuroscience reports*. 2019 Jul;19:1-4.
- [57] Kumar AP, Singh N, Nair D, Justin A. Neuronal PET tracers for Alzheimer's disease. *Biochemical and Biophysical Research Communications*. 2022 Jan 8;587:58-62.
- [58] Hall B, Mak E, Cervenka S, Aigbirhio FI, Rowe JB, O'Brien JT. In vivo tau PET imaging in dementia: pathophysiology, radiotracer quantification, and a systematic review of clinical findings. *Ageing research reviews*. 2017 Jul 1;36:50-63.
- [59] Wilson H, Pagano G, Politis M. Dementia spectrum disorders: lessons learnt from decades with PET research. *Journal of Neural Transmission*. 2019 Mar 14;126(3):233-51.
- [60] Leuzy A, Chiotis K, Lemoine L, Gillberg PG, Almkvist O, Rodríguez-Vieitez E, Nordberg A. Tau PET imaging in neurodegenerative tauopathies—still a challenge. *Molecular psychiatry*. 2019 Aug;24(8):1112-34.
- [61] Valotassiou V, Malamitsi J, Papatriantafyllou J, Dardiotis E, Tsougos I, Psimadas D, Alexiou S, Hadjigeorgiou G, Georgoulas P. SPECT and PET imaging in Alzheimer's disease. *Annals of nuclear medicine*. 2018 Nov;32:583-93.
- [62] Laforce Jr R, Soucy JP, Sellami L, Dallaire-Théroux C, Brunet F, Bergeron D, Miller BL, Ossenkoppele R. Molecular imaging in dementia: Past, present, and future. *Alzheimer's & Dementia*. 2018 Nov 1;14(11):1522-52.
- [63] Harada R, Okamura N, Furumoto S, Furukawa K, Ishiki A, Tomita N, Tago T, Hiraoka K, Watanuki S, Shidahara M, Miyake M. 18F-THK5351: a novel PET radiotracer for imaging neurofibrillary pathology in Alzheimer disease. *Journal of Nuclear Medicine*. 2016 Feb 1;57(2):208-14.
- [64] Beyer L, Brendel M. Imaging of tau pathology in neurodegenerative diseases: an update. In *Seminars in nuclear medicine* 2021 May 1 (Vol. 51, No. 3, pp. 253-263). WB Saunders.
- [65] Kroth H, Oden F, Molette J, Schieferstein H, Capotosti F, Mueller A, Berndt M, Schmitt-Willich H, Darmency V, Gabellieri E, Boudou C. Discovery and preclinical characterization of [18 F] PI-2620, a next-generation tau PET tracer for the assessment of tau pathology in Alzheimer's disease and other tauopathies. *European journal of nuclear medicine and molecular imaging*. 2019 Sep 1;46:2178-89.
- [66] Leuzy A, Chiotis K, Lemoine L, Gillberg PG, Almkvist O, Rodríguez-Vieitez E, Nordberg A. Tau PET imaging in neurodegenerative tauopathies—still a challenge. *Molecular psychiatry*. 2019 Aug;24(8):1112-34.
- [67] Mena AM, Strafella AP. Imaging pathological tau in atypical parkinsonisms: a review. *Clinical Parkinsonism & Related Disorders*. 2022 Jul 16:100155.
- [68] Tezuka T, Takahata K, Seki M, Tabuchi H, Momota Y, Shiraiwa M, Suzuki N, Morimoto A, Nakahara T, Iwabuchi Y, Miura E. Evaluation of [18F] PI-2620, a second-generation selective tau tracer, for assessing four-repeat tauopathies. *Brain Communications*. 2021 Oct 1;3(4):fcab190.
- [69] Smith R, Schöll M, Widner H, van Westen D, Svenningsson P, Hägerström D, Ohlsson T, Jögi J, Nilsson C, Hansson O. In vivo retention of 18F-AV-1451 in corticobasal syndrome. *Neurology*. 2017 Aug 22;89(8):845-53.
- [70] Kikuchi A, Okamura N, Hasegawa T, Harada R, Watanuki S, Funaki Y, Hiraoka K, Baba T, Sugeno N, Oshima R, Yoshida S. In vivo visualization of tau deposits in corticobasal syndrome by 18F-THK5351 PET. *Neurology*. 2016 Nov 29;87(22):2309-16.

- [71] Nedelska Z, Josephs KA, Graff- Radford J, Przybelski SA, Lesnick TG, Boeve BF, Drubach DA, Knopman DS, Petersen RC, Jack Jr CR, Lowe VJ. 18F- AV- 1451 uptake differs between dementia with lewy bodies and posterior cortical atrophy. *Movement Disorders*. 2019 Mar;34(3):344-52.
- [72] Brooks DJ. Imaging familial and sporadic neurodegenerative disorders associated with Parkinsonism. *Neurotherapeutics*. 2021 Apr;18(2):753-71.
- [73] Xia C, Dickerson BC. Multimodal PET imaging of amyloid and Tau pathology in Alzheimer disease and non-Alzheimer disease dementias. *PET clinics*. 2017 Jul 1;12(3):351-9.
- [74] Lo Buono V, Palmeri R, Corallo F, Allone C, Pria D, Bramanti P, Marino S. Diffusion tensor imaging of white matter degeneration in early stage of Alzheimer's disease: a review. *International Journal of Neuroscience*. 2020 Mar 3;130(3):243-50.
- [75] Borenstein A, Mortimer J. Alzheimer's disease: life course perspectives on risk reduction. Academic Press; 2016 Feb 16.
- [76] Kanekar S, Poot JD. Neuroimaging of vascular dementia. *Radiologic Clinics*. 2014 Mar 1;52(2):383-401.
- [77] Choudhary MY, Tivaskar MS, Luharia MA, Dhande R, Pathade A. A Review On Image Segmentation Techniques In MRI Brain Stroke. *Journal of Pharmaceutical Negative Results*. 2022 Oct 27:223-8.
- [78] Divya KP, Menon RN, Varma RP, Sylaja PN, Thomas B, Kesavadas C, Sunitha J, Lekha VS, Deepak S. Post-stroke cognitive impairment-A cross-sectional comparison study between mild cognitive impairment of vascular and non-vascular etiology. *Journal of the Neurological Sciences*. 2017 Jan 15;372:356-62.
- [79] Dhawan P, Goodman B. 2016 ACNS Annual Meeting and Courses February 10e14, 2016, Hilton Orlando Lake Buena Vista, Orlando, Florida. *Journal of Clinical Neurophysiology*. 2016 Jun;33(3).
- [80] Salmela MB, Mortazavi S, Jagadeesan BD, Broderick DF, Burns J, Deshmukh TK, Harvey HB, Hoang J, Hunt CH, Kennedy TA, Khalessi AA. ACR appropriateness criteria@ cerebrovascular disease. *Journal of the American College of Radiology*. 2017 May 1;14(5):S34-61.
- [81] Vernooij MW, van Buchem MA. Neuroimaging in dementia. *Diseases of the brain, head and neck, spine 2020–2023: diagnostic imaging*. 2020:131-42.
- [82] Brooks DJ. Molecular imaging of dopamine transporters. *Ageing research reviews*. 2016 Sep 1;30:114-21.
- [83] Saeed U. Apolipoprotein E Polymorphism and Hippocampal Atrophy Across the Spectrum of Alzheimer's Disease and Dementia with Lewy Bodies. University of Toronto (Canada); 2018.
- [84] Roy S, Banerjee D, Chatterjee I, Natarajan D, Mathew CJ. The Role of 18F-Flortaucipir (AV-1451) in the Diagnosis of Neurodegenerative Disorders. *Cureus*. 2021 Jul 26;13(7).
- [85] Perani D, Caminiti SP, Carli G, Tondo G. PET neuroimaging in dementia conditions. *PET and SPECT in Neurology*. 2021:211-82.
- [86] Mehraram R, Peraza LR, Murphy NR, Cromarty RA, Graziadio S, O'Brien JT, Killen A, Colloby SJ, Firbank M, Su L, Collerton D. Functional and structural brain network correlates of visual hallucinations in Lewy body dementia. *Brain*. 2022 Jun 1;145(6):2190-205.
- [87] Chiba Y, Fujishiro H, Iseki E, Kasanuki K, Sato K. The cingulate island sign on FDG- PET vs. IMP- SPECT to assess mild cognitive impairment in Alzheimer's disease vs. dementia with Lewy bodies. *Journal of Neuroimaging*. 2019 Nov;29(6):712-20.
- [88] Dam DV, Vermeiren Y, D Dekker A, JW Naudé P, P De Deyn P. Neuropsychiatric disturbances in Alzheimer's disease: what have we learned from neuropathological studies?. *Current Alzheimer Research*. 2016 Oct 1;13(10):1145-64.
- [89] Ehrlich DJ, Walker RH. Functional neuroimaging and chorea: a systematic review. *Journal of Clinical Movement Disorders*. 2017 Dec;4:1-5.
- [90] Yoo HS, Lee S, Chung SJ, Lee YH, Lee PH, Sohn YH, Lee S, Yun M, Ye BS. Dopaminergic depletion,  $\beta$ - amyloid burden, and cognition in Lewy body disease. *Annals of Neurology*. 2020 May;87(5):739-50.
- [91] Saha A, Banerjee D. Neuroimaging in dementia with Lewy bodies. *Cureus*. 2021 Jun 16;13(6).
- [92] Clifford S, Purcell YM, Killeen RP. The Utility of Molecular Imaging for Investigating Patients with Visual Hallucinations. *AJNR: American Journal of Neuroradiology*. 2016 Nov;37(11):E77.
- [93] Pardini M, Nobili F, Arnaldi D, Morbelli S, Bauckneht M, Rissotto R, Serrati C, Serafini G, Lapucci C, Ghio L, Amore M. 123I-FP-CIT SPECT validation of nigro-putaminal MRI tractography in dementia with Lewy bodies. *European Radiology Experimental*. 2020 Dec;4(1):1-9.
- [94] Duignan JA, Haughey A, Kinsella JA, Killeen RP. Molecular and anatomical imaging of dementia with Lewy bodies and frontotemporal lobar degeneration. In *Seminars in nuclear medicine 2021 May 1 (Vol. 51, No. 3, pp. 264-274)*. WB Saunders.
- [95] Aimo A, Gimelli A. Myocardial innervation imaging: MIBG in clinical practice. *Imaging*. 2021 Dec 20;13(2):87-97.

- [96] Fujishiro H, Okuda M, Iwamoto K, Miyata S, Torii Y, Iritani S, Ozaki N. Early diagnosis of Lewy body disease in patients with late- onset psychiatric disorders using clinical history of rapid eye movement sleep behavior disorder and [123I]- metaiodobenzylguanidine cardiac scintigraphy. *Psychiatry and Clinical Neurosciences*. 2018 Jun;72(6):423-34.
- [97] Sakuramoto H, Fujita H, Suzuki K, Matsubara T, Watanabe Y, Hamaguchi M, Hirata K. Combination of midbrain-to-pontine ratio and cardiac MIBG scintigraphy to differentiate Parkinson's disease from multiple system atrophy and progressive supranuclear palsy. *Clinical Parkinsonism & Related Disorders*. 2020 Jan 1;2:20-4.
- [98] Kane JP, Roberts G, Petrides GS, Lloyd JJ, O'Brien JT, Thomas AJ. 123I-MIBG scintigraphy utility and cut-off value in a clinically representative dementia cohort. *Parkinsonism & related disorders*. 2019 May 1;62:79-84.
- [99] Miyagi T, Yamazato M, Nakamura T, Tokashiki T, Namihira Y, Kokuba K, Ishihara S, Sakima H, Ohya Y. Power spectral analysis of heart rate variability is useful as a screening tool for detecting sympathetic and parasympathetic nervous dysfunctions in Parkinson's disease. *BMC neurology*. 2022 Dec;22(1):1-9.
- [100] 100Nuvoli S, Spanu A, Fravolini ML, Bianconi F, Cascianelli S, Madeddu G, Palumbo B. [123 I] Metaiodobenzylguanidine (MIBG) Cardiac Scintigraphy and Automated Classification Techniques in Parkinsonian Disorders. *Molecular Imaging and Biology*. 2020 Jun;22:703-10.
- [101] Kawazoe M, Arima H, Maeda T, Tsuji M, Mishima T, Fujioka S, Tsugawa J, Tsuboi Y. Sensitivity and specificity of cardiac 123I-MIBG scintigraphy for diagnosis of early-phase Parkinson's disease. *Journal of the Neurological Sciences*. 2019 Dec 15;407:116409.
- [102] Orimo S, Yogo M, Nakamura T, Suzuki M, Watanabe H. 123I-meta-iodobenzylguanidine (MIBG) cardiac scintigraphy in  $\alpha$ -synucleinopathies. *Ageing research reviews*. 2016 Sep 1;30:122-33.
- [103] Postuma RB, Berg D. Prodromal Parkinson's disease: the decade past, the decade to come. *Movement disorders*. 2019 May;34(5):665-75.
- [104] Berg D, Borghammer P, Fereshtehnejad SM, Heinzel S, Horsager J, Schaeffer E, Postuma RB. Prodromal Parkinson disease subtypes—key to understanding heterogeneity. *Nature Reviews Neurology*. 2021 Jun;17(6):349-61.
- [105] Taylor S, Gafton J, Shah B, Pagano G, Chaudhuri KR, Brooks DJ, Pavese N. Progression of nonmotor symptoms in subgroups of patients with non-dopamine- deficient Parkinsonism. *Movement Disorders*. 2016 Mar;31(3):344-51.
- [106] Feng Y, Yan W, Wang J, Song J, Zeng Q, Zhao C. Local white matter fiber clustering differentiates Parkinson's disease diagnoses. *Neuroscience*. 2020 May 21;435:146-60.