

RECENT ADVANCES IN DIAGNOSTIC ORAL RADIOLOGY

Abstract

Diagnostic oral radiology is crucial for precise dental diagnosis and treatment planning. This chapter explores the evolution of diagnostic oral radiology, traversing from traditional techniques to recent advancements. It elucidates the principles and clinical applications of Magnetic Resonance Imaging (MRI), Computed Tomography (CT), and Cone Beam Computed Tomography (CBCT), emphasizing their pivotal roles in three-dimensional imaging and precise diagnosis with minimal radiation exposure. Dual-Energy Computed Tomography enhances tissue characterization, while Positron Emission Tomography (PET) and Single photon emission computed tomography (SPECT) offer insights into metabolic aspects of oral pathology. Dynamic Contrast-Enhanced Imaging (DCE Imaging), Diagnostic Ultrasound, and Arthrography facilitate real-time assessment and lesion localization. Additionally, Xeroradiography and Sialography continue to provide valuable diagnostic information. The chapter also explores Emerging Technologies and Point to Care Testing, alongside the integration of Artificial Intelligence and Deep Learning, promising streamlined image interpretation and personalized treatment planning. This comprehensive chapter aims to empower clinicians and researchers in navigating oral healthcare with precision and efficacy, bridging traditional methods with cutting-edge technologies.

Authors

Dr. Syeda Arshiya Ara

Professor and HOD
Department of Oral
Medicine and Radiology
Al Badar Rural Dental
College and Hospital
Kalaburagi, Karnataka, India.

Dr. Syed Zakaullah

Professor/Dean/Principal
Department of Oral and
Maxillofacial Surgery
Al Badar Dental college and
Hospital
Kalaburagi, Karnataka, India.

Shaik Afsah Rahman

Intern
Al Badar Rural Dental
College and Hospital
Kalaburagi, Karnataka, India

Dr Pooja N

Post Graduate student
Department of Oral and
Maxillofacial Surgery
Al Badar Dental college and
Hospital
Kalaburagi, Karnataka, India

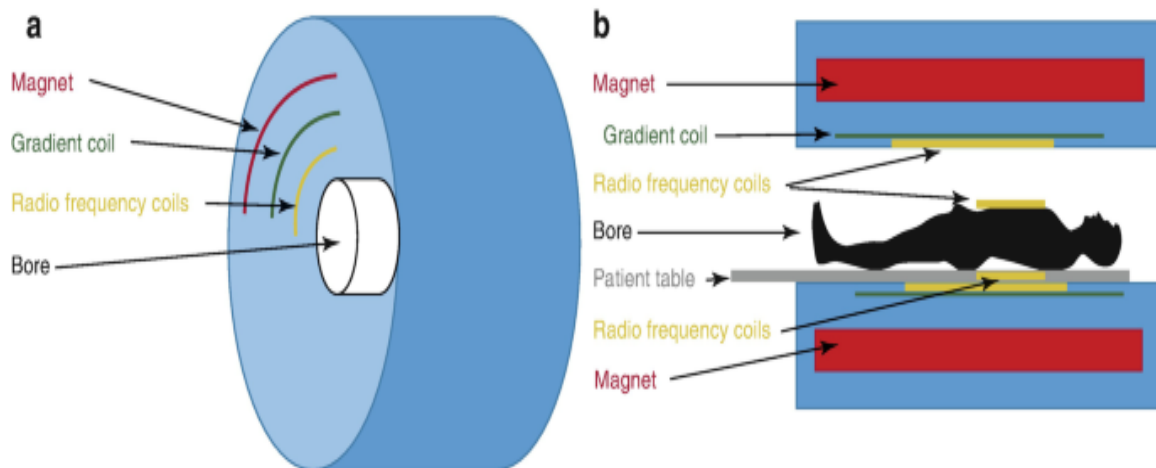
I. INTRODUCTION

In the ever-evolving landscape of dentistry, diagnostic oral radiology stands as a cornerstone for accurate diagnosis and effective treatment planning. As an essential aspect of patient care, diagnostic aids in oral radiology play a pivotal role in providing clinicians with detailed insights into the oral and maxillofacial region. With recent advances and emerging technologies, this field has witnessed a transformative journey, revolutionizing the way dental professionals approach diagnostic challenges.

- 1. Traditional Radiographic Techniques:** Traditional radiographic techniques have long been the cornerstone of dental imaging, providing two-dimensional images of the oral and maxillofacial region for accurate diagnosis and treatment planning. Intraoral radiography involves placing X-ray film or digital sensors inside the mouth to assess individual teeth and detect dental caries, periodontal conditions, and endodontic pathologies. Extraoral radiography, on the other hand, captures images of larger head and neck areas, allowing evaluation of the entire dentition, dental relationships, and developmental abnormalities. While traditional radiographs offer familiarity, ease of use, and cost-effectiveness, they are limited to two-dimensional images and may involve radiation exposure. Despite these limitations, they remain essential diagnostic aids in dental practices worldwide, complementing advanced imaging modalities for comprehensive patient care.
- 2. Recent Advances in Diagnostic Oral Radiology:** Recent advances in diagnostic oral radiology, such as digital radiography, cone beam computed tomography (CBCT), and dynamic imaging techniques, have addressed some of the limitations of traditional radiography. These advanced technologies offer improved image quality, three-dimensional visualization, and reduced radiation exposure, enabling better evaluation of complex anatomical structures, early detection of pathologies, and enhanced treatment planning precision. Additionally, emerging technologies like optical coherence tomography (OCT) and photoacoustic imaging promise non-invasive tissue characterization and novel approaches to diagnosis, further revolutionizing the field of diagnostic oral radiology. As dental professionals embrace these advancements, they can achieve a more comprehensive and accurate approach to patient care, optimizing outcomes and enhancing the overall dental experience for their patients.

II. MRI

- 1. Working Principle:** T1 stands for "longitudinal relaxation time" or "spin-lattice." It is a measurement of the amount of time that protons need to realign with the imaging magnet's field after an RF pulse. A brief signal recovery period followed by a brief RF pulse repetition time results in a T1-weighted image. Since T1 is an exponential growth time constant, a T1 weighted image with a short T1 will show an intense MR signal as white. A long T1 tissue will appear dark on an MRI and produce a low-intensity signal. T2 stands for "transverse relaxation time" or "spin-spin." It is the amount of time needed for an RF pulse brought on by magnetic interactions to cause the tissue proton to de-phase after they are positioned in opposition to the magnetic field outside. A long signal recovery time combined with a long RF pulse repetition interval is used to acquire a T2-weighted image. In an image, a tissue with a long T2 will appear bright and produce a high-intensity signal, while a tissue with a short T2 will appear low-intensity and dark.



Working Principle of MRI

2. Applications

- Assessing disorders of soft tissues, such as the disk in the temporomandibular joint (TMJ).
- Finding the location of the mandibular nerve; assessing soft tissue disease, particularly soft tissue neoplasms; identifying malignant lymph node diseases and determining perineural invasion; visualizing edematous changes in the fatty marrow and the surrounding soft tissue; revealing the extent of carcinoma penetration into the mandibular cortex; and recently describing the use of mid-field MRI for pre-surgical dental implant assessment using a one-tesla scanner.
- Three-dimensional visualization of the periapical, pulp, and dental caries structures.
- The ability to differentiate between the acute, chronic, and transit to fibrous phases histopathologically can be done simultaneously. There is no evidence of dental filling artifact. The high contrast level of MRI renders the use of contrast agents unnecessary in most situations.
- Helpful in figuring out the intramedullary spread; No negative effects have been documented; Image manipulation is possible.

3. Contraindications

- **Vascular Clips:** There may be issues with MR-associated heating with ferromagnetic vascular clips.
- **Foreign Bodies:** When metal foreign bodies shift in a magnetic field, it can cause artifacts and harm important structural elements.
- **Prosthetic Heart Valves and Annuloplasty Rings:** There are some minor interactions with the magnetic field. Coronary and peripheral artery stents/aortic stent grafts: The effect of heating induced by the RF field might cause artifacts, which can impair the evaluation of the stent itself. Sternal wires, which are typically made of stainless steel or an alloy, are not MRI contraindications.
- **Cardiac Occluder Devices, Vena Cava Filters, and Embolization Coils:** These devices have the potential to cause vascular occlusion during MRI imaging. As a result, waiting until six weeks following implantation before doing an MRI examination.

- **Temporary Pacing Devices and Hemodynamic Monitoring/Support Devices:** An RF pulse during an MRI examination may cause currents that could result in thermal injuries.
- **Implantable Defibrillators, Retained Transvenous Pacemakers, and Permanent Cardiac Pacemakers:** These devices should not be used due to the possibility of device dislodgement, programming modifications, asynchronous pacing, activation of anti-tachycardiac therapies, and cardiac stimulation and heating.
- **Permanent Contraceptive Devices:** Intrauterine contraceptive devices are composed of metal components that are weakly ferromagnetic or non-ferromagnetic, such as plastic.

4. Advantages

- It provides tissue with low inherent contrast with the best resolution. There is a maximum 1% variation in the X-ray attenuation co-efficient between soft tissue, a maximum 40% variation in the MR parameters spin intensity and T1 and T2 relaxation times.
- **Non-invasive:** Magnetic resonance imaging (MRI) is non-invasive.
- **Non-ionizing Radiation:** radiofrequency pulses used in MRI do not ionize and have no negative effects, so they can be used on females and children.
- Contrast resolution, which allows the image processing to distinguish between adjacent soft tissues, is the primary benefit of magnetic resonance imaging (MRI). By adjusting the radiofrequency pulse pattern, one can manipulate the contrast resolution of various tissues.
- **Multiplanar Image:** Direct, sagittal, coronal, and oblique images can be obtained with MRI.

5. Limitations

- Claustrophobia, or the dread of enclosed spaces because the patients are in the big magnet
- The strong magnetic field used for patient imaging is electrically and mechanically activated, so patients with implants, cardiac pacemakers, implanted defibrillators, and prosthetic cardiac valves are not suitable candidates for MRIs.
- The presence of metals, such as surgical clips, aneurysm stents, etc., causes the magnetic field to distort the image during an MRI.
- Only the bone marrow can provide an MR signal.
- Even with the best shielding, the strong magnets used in MRIs can pose a major risk to the positioning of equipment; the scanners make a lot of noise.
- MRI is unable to distinguish between disease processes or benign and malignant tumors.
- It is difficult to distinguish between metallic objects, teeth, bone, and air because they all appear black.

III. COMPUTED TOMOGRAPHY

In essence, a CT scan is an X-ray study in which computer-generated cross-sectional images are created by rotating a series of rays around a designated body part. These tomographic images have a significant advantage over plain films over conventional X-rays because they do not require image superimposition and instead provide detailed information about a designated area in cross-section. For a suspected ailment, CT scans offer excellent clinicopathological correlation.

1. Working Principle

- The fundamental idea of CT is that an object's internal structure can be recreated using a number of the object's projections.
- In its most basic configuration, a CT scanner is made up of a radiographic tube that directs a finely collimated, fan-shaped x-ray beam toward a number of scintillation detectors.
- The mechanical geometry of the scanner determines whether the detectors and the radiographic tube rotate simultaneously around the patient or if the detectors form a continuous ring around the patient and the x-ray tube moves in a circle within the detector ring.
- More recently, spiral or helical image data acquisition methods have been developed for CT scanners.
- With these scanners, the patient's table moves continuously through the gantry as the gantry with the x-ray tube and detectors revolves around the patient. As a result, as the x-ray beam descends the patient, a continuous spiral of data is acquired.

2. Applications

- Examining conditions pertaining to the brain, such as tumors, hemorrhages, and infarcts.
- Examining cases of possible spinal cord and brain damage after head and neck trauma.
- Assessment of fractures involving:
 - The orbits and nasoethmoidal complex.
 - The cranial base.
 - The odontoid peg.
 - The cervical spine.
- Tumor staging—assessment of site, size and extent of benign and malignant tumors affecting:
 - The maxillary antra
 - The base of the skull
 - The pterygoid region
 - The pharynx
 - The larynx
- Examining tumors and tumor-like discrete swellings that are both intrinsically and externally related to the salivary glands.
- A TMJ investigation.

- Measurement of the thickness and height of the maxillary alveolar bone prior to surgery in order to place implants.

3. Advantages

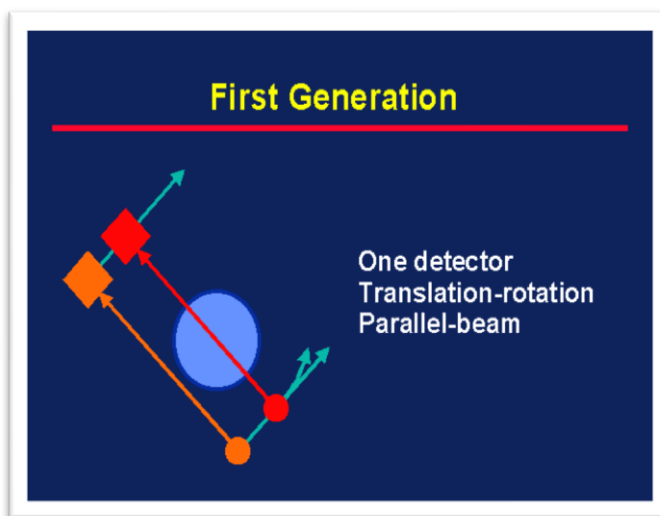
- Direct observation reveals the structural relationships between hard and soft tissues. It is possible to distinguish between tissues with physical density differences of less than 1%.
- The ability to study relationships is made possible by the ability to rotate images and add or subtract structural components.
- It is possible to divide up contiguous structures and thoroughly examine normally hidden surfaces.
- It is possible to make precise volumetric and linear measurements.
- Sequential scans can be used to identify changes in linear or volumetric measures (e.g. remodeling of bone).
- Removes the ability to superimpose images of structures that are not within the area of interest.
- Depending on the diagnostic task, a single CT imaging procedure comprising one helical scan or multiple contiguous scans can be viewed as images in the sagittal, coronal, or axial planes (multi-planar reformatted imaging).

4. Limitations

- Compared to traditional radiography systems, the effect of blurring is significantly larger because the measurements or pixels that make up the image represent discrete subdivisions of space.
- The size of the pixel, which is typically larger than the size of the silver specks that make up conventional radiographs, also limits the resolution of the image.
- A computed tomographic image's detail is not as good as what can be found on other radiographs.
- Its use in implant prosthesis longitudinal monitoring is restricted and not recommended due to metal-induced image artifacts that would distort the data.

FIRST GENERATION SCANNERS (TRANSLATE-ROTATE)

- The x-ray source and detector simultaneously translate along parallel lines on opposite sides of the patient.
- Using a single x-ray detector and a pencil-shaped x-ray beam.
- Only 2 detectors were used. NaI used as detector.
- This system uses parallel ray geometry.
- This was made especially for evaluating the brain; the head was submerged in water.
- Scan time- 5 minutes.



ADVANTAGE

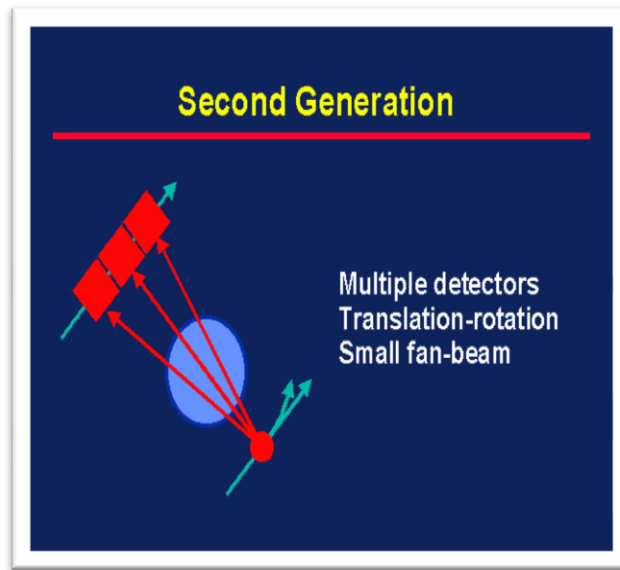
- Pencil beam geometry allowed very efficient scattered reduction.

DISADVANTAGE

- NaI is Hygroscopic
- High scanning time
- Complex mechanical motion of rotate-translate system.
- Poor spatial resolution
- Shorter rotational angle (1degree).

SECOND GENERATION SCANNERS (ROTATE- TRANSLATE SYSTEM)

- Narrow fan beam (ten degrees)
- Linear detector array composed of NaI scintillator (5 to 30).
- This generation saw the introduction of the bowtie filter.
- Rotate and translate the tube-detector combination.
- Since there are more detectors to collect the data, fewer linear movements are required.
- 20–30 second scan times (a benefit over first generation).



ADVANTAGES

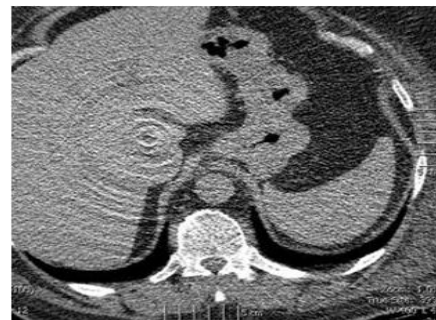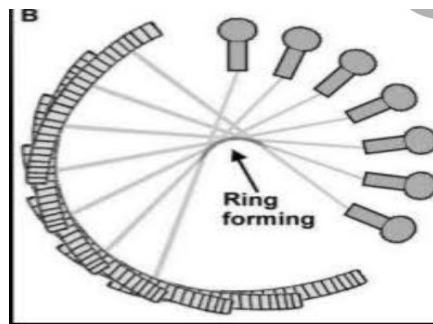
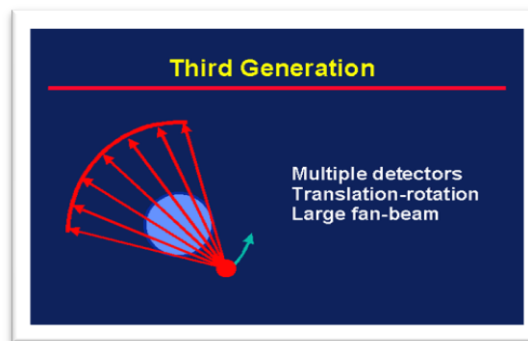
- Shorter scan time.
- Speed increased of scanning due to increased no. of detectors.
- Larger rotational increments (300).

DISADVANTAGES

- Hygroscopic nature of NaI
- Complex mechanical motion of translate-rotate
- Scatter radiation increased due to narrow fan beam.

THIRD GENERATION OF SCANNERS (ROTATE-ROTATE)

- Turn (tube) Rotate in motion (detectors).
- Wide fan beam configuration.
- This generation's arc of detectors (600–900)
- Detectors precisely line up with the X-ray tube
- 'Fan beam' or third generation geometry is the term given to this scanning geometry.
- It can be used with both Xenon and scintillation crystal detectors.
- The scan time is reduced to 1 second.



ADVANTAGES

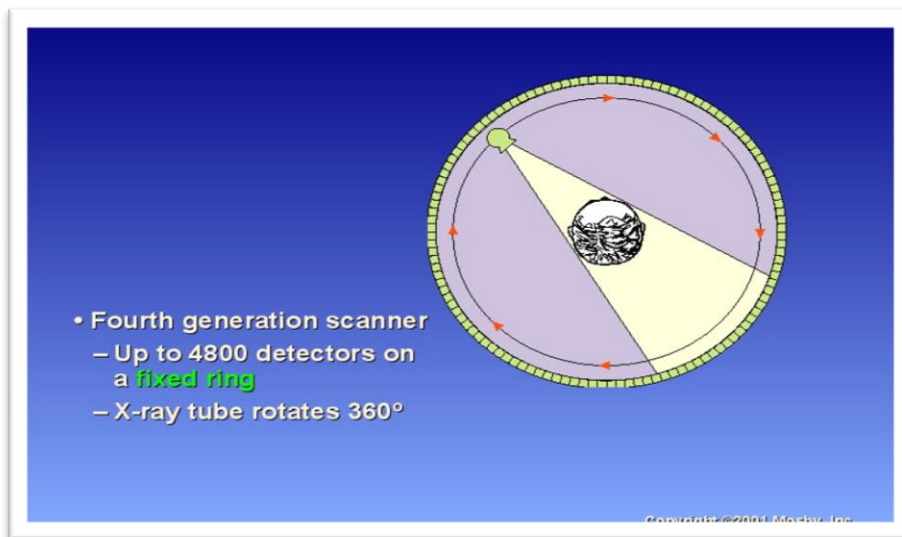
- Elimination of complexity of translate-rotate motion.
- Shorter scan time.
- Less patient dose
- Alignment of detector assembly allows for better x-ray collimation.

DISADVANTAGES

- More scattered radiation due to wide angle fan beam.
- Expensive than previous generation.
- Ring artifact
- If one of the detectors is out of calibration, the detectors will give a consistent erroneous reading at each angular position, resulting in circular artifact called as Ring Artifact.
- It occurs due to miscalibration or failure of one or more detector elements.

FOURTH GENERATION SCANNER (ROTATOR FIXED)

- A single x-ray tube rotates within the circular array of detectors, covering the entire patient, a wide fan beam covers the entire field of vision, and the latest scanners have scan times of ½ s or less.
- Intended to reduce ring artifacts by maintaining the detector assembly's stationary position.



ADVANTAGES

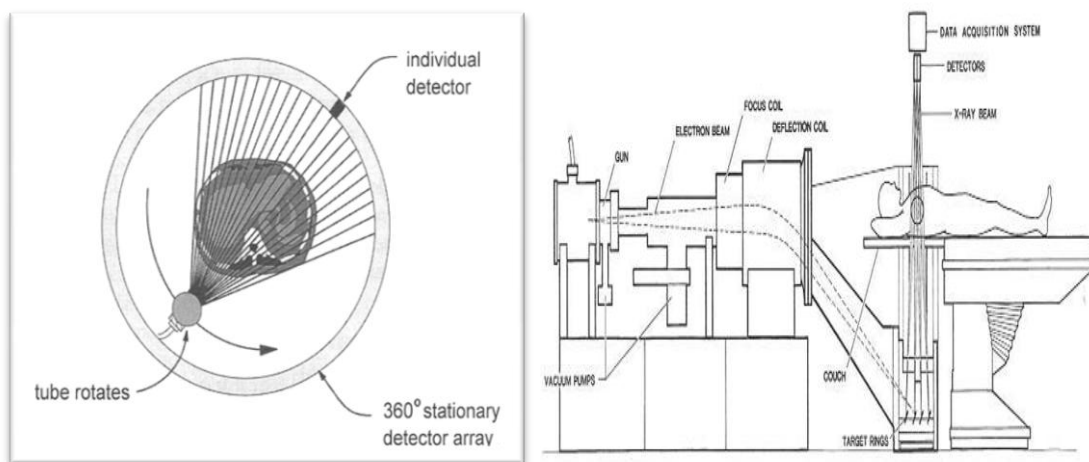
- The ring artifact is eliminated

DISADVANTAGES

- A drawback is the high price.
- More dispersed radiation as a result of the fan beam's large angle.

FIFTH GENERATION SCANNERS (ELECTRON BEAM IMAGING)

- Fixed - Fixed; designed especially for cardiac tomographic imaging; no traditional x-ray tube; a sizable arc of tungsten surrounds the patient and is positioned across from the detector ring
- The patient was positioned so that the electron beam would strike the annular tungsten target.
- Has a 50 msec scan time capability.
- Another name for this generation of CT equipment is Electron Beam Computed Tomography (EBCT).



ADVANTAGES

- It can produce fast frame rate CT with minimum motion artifact.
- Increased speed.
- Shorter scanning time.

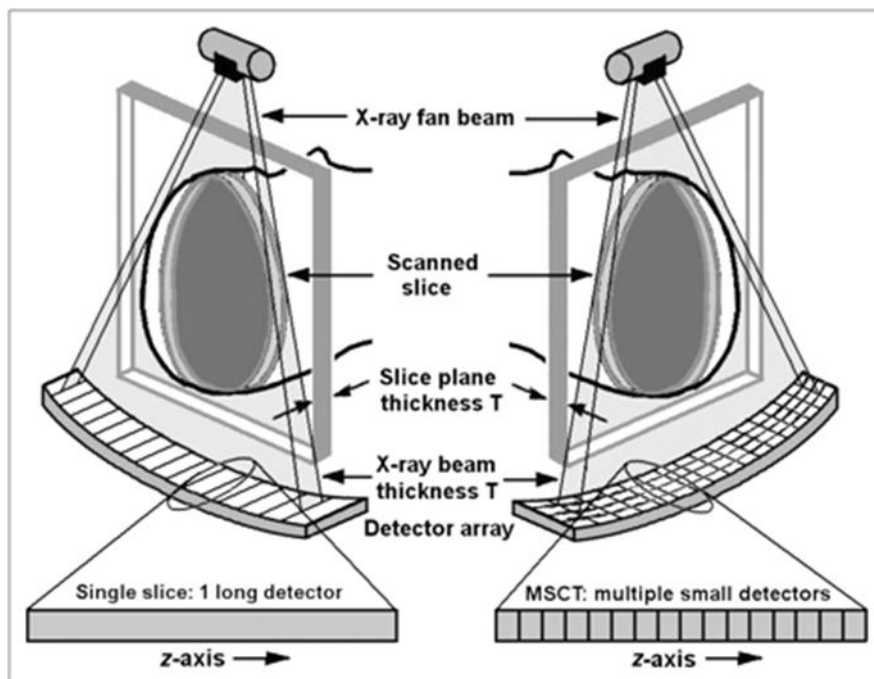
DISADVANTAGES

- Complex circuitry
- Bulky
- High equipment cost
- Image quality poor for general scanning (because of low mAs)

SIXTH GENERATION CT	
<ul style="list-style-type: none"> • Spiral/Helical CT Design: simultaneous source rotation, table translation, and data acquisition; x-ray tube rotates as patient is smoothly moved into the x-ray scan field generates a single continuous volume set of data for the whole area Data from the patient were obtained at one second per slice. <div style="text-align: center; margin-top: 20px;"> </div>	
ADVANTAGES	DISADVANTAGES
<ul style="list-style-type: none"> • Continuous patient movement • Shorter exam duration; 30 seconds for the entire abdomen or chest (1BH) • Better detections: small lesions that fall out of plane for each continuous slice, variations in BHs in standard CT • Better contrast: you can image a region quickly and time the contrast. • Better reconstruction and manipulation: more data was gathered, and transverse data allowed for the reconstruction of any plane by removing muscles, skin, and other components. 	<ul style="list-style-type: none"> • High equipment cost

MULTISLICE CT SCANNERS

- The concept of multislice CT scanners is similar to that of helical or spiral CT scanners, but they have multiple detector rings.
- The faster volume coverage speed is the main advantage of multislice CT.
- Large volumes can now be scanned at the best moment after intravenous contrast is administered; this has been especially helpful for CT angiography methods, which mainly depend on accurate timing to guarantee clear artery demonstration.
- Increased post-processing capabilities on workstations are possible thanks to computer power.
- Bone suppression, real-time volume rendering that allows for the natural visualization of internal organs and structures, and automated volume reconstruction transform CT study diagnostics into a true volumetric scanning experience.
- Studies can be freely viewed in any desired plane, and maximum image quality is not limited to images in the axial plane thanks to multislice scanners' ability to achieve isotropic resolution even on routine studies.



IV. CONE BEAM COMPUTED TOMOGRAPHY (CBCT)

The volumetric image-capture technology known as cone beam computed tomography (CBCT) imaging produces a data set from which digital images are reformatted and displayed on a display device. Clinicians must consequently be conversant with software-assisted volumetric review in order to visualize CBCT data. Images should be prepared and shown dynamically in accordance with task-specific display protocols.

1. Principle

- **X-ray Source:** Unlike traditional CT scanners, which employ fan-shaped X-ray beams, CBCT uses a cone-shaped beam. In a single scan, or rotation, the X-ray source revolves around the patient's head, covering the designated anatomical volume or the area of interest.
- **Detector:** The reciprocating solid-state flat panel detector used in CBCT detects X-rays after they enter the patient's head and are captured. The X-ray intensity is registered by the detector from various angles.
- **Single Scan and Reduced Dose:** Convolutional CT (CBCT) obtains planned data in a single rotation, as opposed to conventional CT, which acquires axial plane slices or continuously spirals motion. When compared to CT, this considerably lowers the absorbed X-ray dose—by as much as six to fifteen times.
- **Image Reconstruction:** The 2D X-ray images are instantly sent to the computer after being taken, much like lateral cephalometric images. Using a modified Feldkamp technique, the computer reconstructs these 2D images into a 3D anatomical volume. One can see the generated three-dimensional volume in orthogonal planes (sagittal, coronal, and axial).
- **X-ray Specifications:** When compared to traditional CT, which requires greater mA and kVp, the X-ray parameters of CBCT are similar to those of panoramic radiography, requiring lower mA (milliamperes) and kVp (kilovolts peak) settings.
- **Data Format:** The Digital Imaging and Communications in Medicine (DICOM) format, which is compatible with various third-party imaging software, is used to produce the data generated by CBCT.

2. Applications

- In dentistry, radiographic examination is essential for both diagnosis and treatment planning.
- The inherent limitations of 2D imaging, such as superimposition, distortion, and magnification, can cause structures to be misrepresented.
- CBCT generates three-dimensional images that are useful for diagnosing, planning, and monitoring oral and maxillofacial conditions.
- **Implantology:** CBCT is ideal for accurate assessment of implant sites, reducing failures and minimizing radiation exposure.
- **Oral and Maxillofacial Surgery:** CBCT permits precise measurement, exploration, and management of various facial fractures, pathologies, and osteomyelitis.
- **Orthodontics:** CBCT offers superimposition-free images for orthodontic analysis and surgical planning.
- **TMJ Disorders:** CBCT provides multiplanar images for TMJ analysis, helping in diagnosing dislocation and other joint-related issues.
- **Endodontics:** CBCT is better compared to 2D imaging in describing Apical lesions, root canals, and detecting fractures and resorption.
- **Periodontics:** CBCT's morphometric analysis is precise, allowing accurate measurement of bone defects and evaluation of periodontal treatments.
- **Rapid Prototyping:** CBCT is used to create surgical guides and anatomically precise models for complex surgeries.

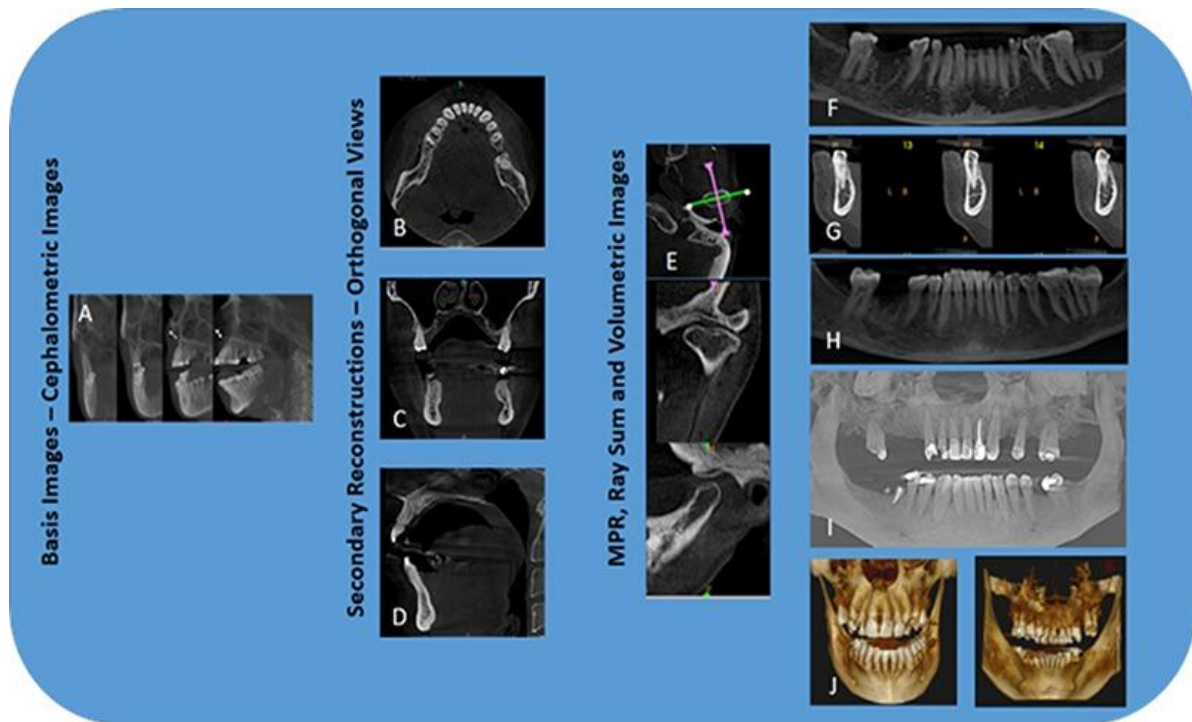
- **CBCT and Stereophotography:** CBCT fused with optical data aids in dentofacial deformity diagnosis and orthognathic surgery planning.
- CBCT has diverse applications in general radiology, otolaryngology, musculoskeletal, breast, respiratory, cardiac imaging, and spinal surgery.

3. Advantages

- **X-ray Beam Limitation:** By efficiently collimating the X-ray beam to the area of interest, CBCT equipment minimize dispersed radiation and spare the patient needless exposure. As a result, radiation exposure is decreased and image quality is enhanced.
- **Image Accuracy:** High-resolution imaging with sub-millimeter precision is possible due to the isotropic voxels (equal in all three dimensions) that CBCT provides. Applications such as orthodontic analysis and implant site assessment require this level of accuracy.
- **Quick Scan Time:** Like panoramic radiography, CBCT scans can be finished quickly, usually in the range of 5 to 40 seconds. As a result, there is a lower possibility of motion artifacts from patient movement during the scan.
- **Dose Reduction:** When compared to traditional CT, CBCT considerably lowers radiation exposure. Depending on the FOV and CBCT apparatus, the effective dose may be substantially lower, protecting patients.
- **Display Modes Unique to Maxillofacial Imaging:** CBCT offers various display modes, such as multiplanar reformation (MPR) for oblique and curved planar images, serial cross-sectional reformation, and true 3D visualization. These features enhance the visualization of complex oral and maxillofacial anatomy.
- **Reduced Image Artifact:** Advancements in CBCT technology, including artifact suppression algorithms and increased projections, have minimized metal artifacts, especially when viewing the jaws and teeth.

4. Limitations

- **Artifacts:** CBCT images can be affected by various artifacts, leading to distortions or errors unrelated to the actual anatomy. The presence of these artifacts may degrade the quality of the images and make it more difficult to visualize the dental and alveolar structures.
- **Image Noise:** CBCT scanning involves a larger volume of irradiation, resulting in scattered radiation and increased image noise, which can degrade image quality.
- **Insufficient Soft Tissue Contrast:** When compared to traditional CT scanners, CBCT machines typically provide lesser soft tissue contrast. This limitation is affected by artifacts, beam divergence, and image noise.



CBCT: Image acquisition and display modes.

V. DUAL-ENERGY COMPUTED TOMOGRAPHY

Dual-Energy Computed Tomography (DECT) has emerged as a powerful and promising diagnostic aid in head and neck imaging, gaining popularity among specialists in recent years. DECT offers distinct advantages over conventional computed tomography, including additional reconstructions with comparable radiation doses. By employing material characterization and differentiation, DECT provides valuable insights into various pathologies in the head and neck region, offering enhanced detection and accurate staging of tumors, differentiation of benign and malignant lymph nodes, reduction of metallic artifacts, and assessment of bone marrow infiltration.

1. Working Principle

- **Dual X-ray Spectra:** DECT uses two different X-ray spectra, typically at high and low energies. These spectra are obtained either by utilizing dual X-ray tubes or a single tube with adjustable kVp settings, filters, or dual-layer detectors.
- **Simultaneous Scanning:** During a DECT scan, both high and low-energy X-rays are simultaneously directed through the patient's body.
- **Attenuation Measurement:** As the X-rays pass through the body, they interact with different tissues. The interaction results in attenuation, which is the reduction of X-ray intensity based on the density and atomic composition of the tissues.
- **Data Acquisition:** The detectors in the DECT scanner capture the attenuated X-rays and generate raw data containing information about tissue attenuation at both high and low energies.
- **Material Differentiation:** The difference in attenuation at different energy levels allows for the calculation of unique linear attenuation coefficients for specific

materials such as iodine, calcium, fat, and water. This enables material-specific images and tissue characterization.

- **Image Reconstruction:** The acquired raw data is processed by sophisticated algorithms to reconstruct images at various virtual monochromatic energies or blended images with enhanced tissue contrast.

2. Applications

- **DECT in Head and Neck Oncology:** In head and neck squamous cell carcinoma (HNSCC) patients, DECT plays a crucial role in detecting and delineating tumors, contributing to more accurate staging. With the capability to differentiate between malignant and benign lymph nodes based on iodine concentration, DECT aids in identifying potential metastases. Additionally, DECT helps distinguish between benign post treatment changes and recurrent disease, guiding appropriate management decisions.
- **Metal Artifact Reduction:** DECT proves highly beneficial in reducing metallic artifacts, particularly in patients with dental restorations or metallic implants. By using virtual monoenergetic imaging at higher keV, DECT enhances image quality and clarity, overcoming challenges posed by metallic objects in the head and neck area.
- **Assessment of Bony Invasion:** DECT offers three material differentiation algorithms for identifying iodine and calcium, making it useful in assessing cartilage and bone marrow infiltration. This novel application in head and neck DECT enables precise evaluation of tumor invasion into bony structures, facilitating treatment planning.
- **Imaging of Infection and Inflammation:** DECT is a valuable tool in mitigating the impact of infection and inflammation in the head and neck region. Its ability to differentiate tissues based on spectral curves aids in distinguishing diseased areas from healthy tissue, allowing for more accurate diagnoses and targeted interventions.
- **Cervical Lymph Nodes Analysis:** In patients with suspected cervical lymph node involvement, DECT provides critical information for accurate diagnosis. The characterization of iodine concentration helps differentiate between malignant and benign lymph nodes, supporting appropriate treatment decisions and optimizing patient outcomes.
- **Applications in Parathyroid Tumors:** DECT has shown promise in the assessment of parathyroid tumors. Its ability to differentiate tissues based on material characteristics assists in identifying and characterizing parathyroid lesions, guiding surgical planning and management.

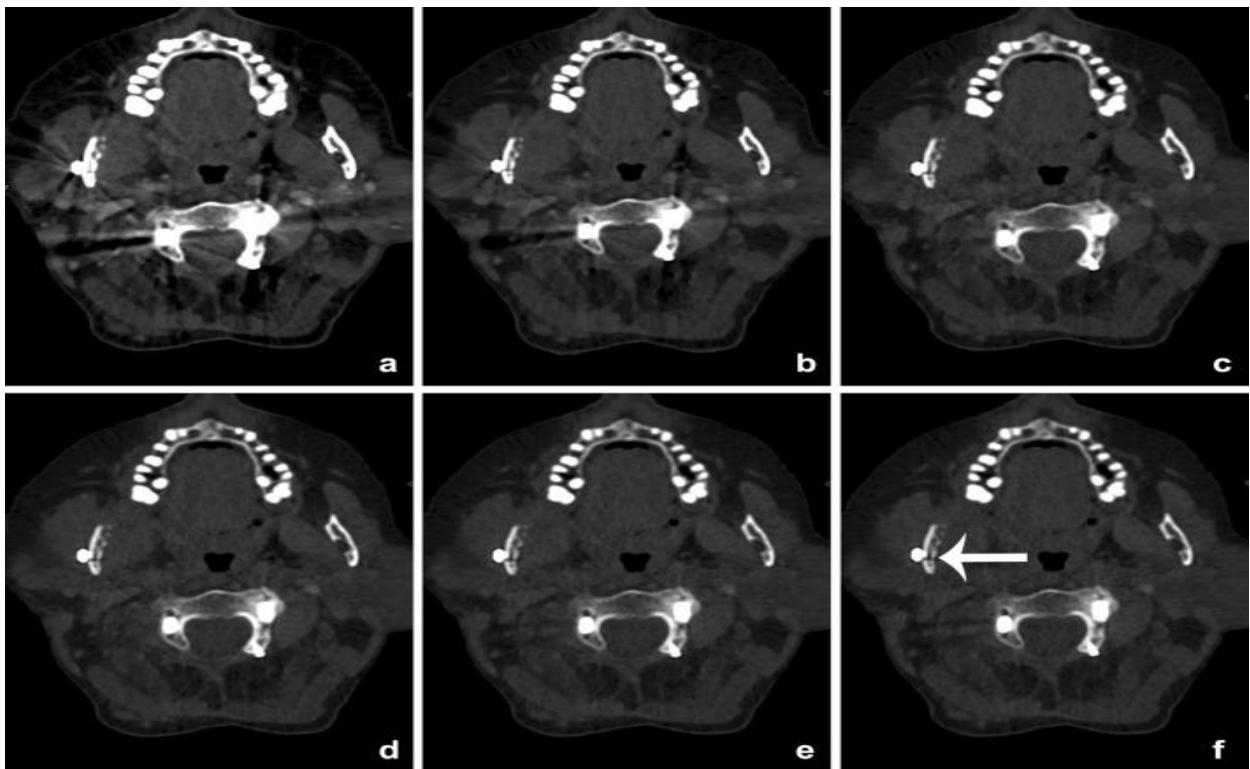
3. Advantages

- **Motion and Beam-Hardening Artifacts:** DECT may suffer from motion artifacts due to patient movement and beam-hardening artifacts caused by the energy dependence of X-ray attenuation in different tissues. Efforts are needed to reduce these artifacts and enhance image quality.
- **Noise Optimization:** Further optimization is required to reduce noise in material decomposition images obtained through DECT, which can improve the overall image quality.

- **Bone or Calcium Segmentation:** The segmentation or removal of bone or calcium artifacts in DECT images needs improvement to ensure accurate interpretation and diagnosis.
- **Workflow Issues:** DECT implementation can result in workflow challenges for radiologists, such as difficulties in scheduling CT scans, longer reconstruction times, increased number of images, and higher interpretation time. These issues hinder the routine use of DECT in daily clinical practice.

4. Limitations

- **Motion and Beam-Hardening Artifacts:** DECT may suffer from motion artifacts due to patient movement and beam-hardening artifacts caused by the energy dependence of X-ray attenuation in different tissues. Efforts are needed to reduce these artifacts and enhance image quality.
- **Noise Optimization:** Further optimization is required to reduce noise in material decomposition images obtained through DECT, which can improve the overall image quality.
- **Bone or Calcium Segmentation:** The segmentation or removal of bone or calcium artifacts in DECT images needs improvement to ensure accurate interpretation and diagnosis.
- **Workflow Issues:** DECT implementation can result in workflow challenges for radiologists, such as difficulties in scheduling CT scans, longer reconstruction times, increased number of images, and higher interpretation time. These issues hinder the routine use of DECT in daily clinical practice



Patient with a cervical spondylodiosis and metallic hardware of the mandible

VI. POSITRON EMISSION TOMOGRAPHY (PET) AND SINGLE PHOTON EMISSION TOMOGRAPHY (SPECT)

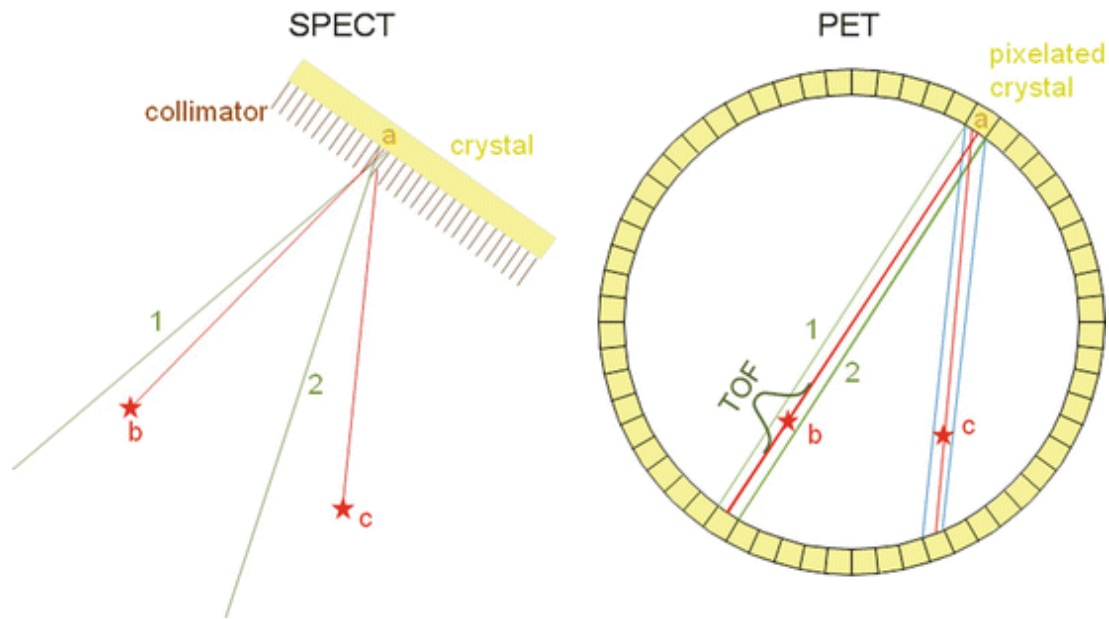
1. Working Principle

• A PET

- PET is based on the detection of very small (picomolar) quantities of biological substances which are labelled with a positron emitter.
- Most commonly used are carbon-11, oxygen-15, nitrogen-13, and fluorine-18. Advantages of positron labelled substances are their very high specificity (molecular targeting), the possibility of using biological active substances without changing their behaviour by the label, and fulfilment of the tracer principle.
- Thus, the process of interest remains unchanged during the measurement. Target structures of these molecules are e.g. glucose metabolism, receptor binding potential, catecholamine transport, amino acid transport, or protein synthesis.
- All the above-mentioned nuclides have very short radioactive half-lives (2 min for O-15, 109 min for F-18), which necessitates a nearby cyclotron and radiochemistry facility.

• B SPECT

- This “electronic collimation” is the reason why PET is much more sensitive (factor >100) than the conventional nuclear medical technique, namely single photon emission tomography (SPECT) using gamma cameras and lead collimators.
- The detector pairs of a PET system are installed in a ring-like pattern, which allows measurement of radioactivity along lines through the organ of interest at a large number of angles and radial distances.
- Subsequently, this angular information is used in the reconstruction of tomographic images of regional radioactivity distribution. State-of-the-art positron emission tomographs consist of multiple, closely packed rings of detectors that enable simultaneous imaging of several image planes.
- Coincident events between rings of the camera are acquired to generate cross-data, which minimizes data gaps between imaging planes. Such data acquisition allows almost complete data sampling in three dimensions (3D PET).
- The raw data are integrals along the line-of-coincidence over the activity distribution. There is no time-of-flight information included since the timing resolution of the current detectors is not good enough.



Working principle of PET and SPECT

2. Applications

- The literature regarding SPECT versus SPECT/CT in evaluation of hyperparathyroidism has been somewhat conflicting, with studies reporting increased value of SPECT/CT], whereas others claim little incremental benefit. However, the consensus seems to be that SPECT/CT has the most utility in patients with ectopic parathyroid adenoma, those with distorted neck anatomy due to prior surgery, and those with prior failed parathyroid surgery. Whereas planar techniques can depict the relative position of the abnormality, cross-sectional multiplanar imaging will precisely specify the depth of the focus and its position with respect to the surrounding and adjacent structures. The addition of the CT component in hybrid SPECT/CT therefore would be expected to improve mediastinal focus localization even further because both the scintigraphic and corresponding CT abnormality can be pinpointed simultaneously. This information should serve to clarify presurgical planning and can potentially decrease intraoperative search time.
- Sentinel lymphoscintigraphy has become a standard procedure used to identify the location of at-risk nodal basins in patients with head and neck, skin, and breast cancers. Although lymphoscintigraphy can be performed successfully using planar gamma camera imaging, precise localization of nodes can nonetheless be difficult in anatomically complex regions such as the head and neck or when in-transit body wall nodes are found during mapping of lymphatic drainage from torso lesions. SPECT/CT offers enhanced preoperative sentinel lymph node (SLN) localization
- Bone scintigraphy is a sensitive technique for detection of bone metastases and assessment of treatment response in neoplastic disease, especially for those with a tendency toward osteoblastic metastases (i.e., prostate, breast). Although many bone foci can be adequately characterized on the basis of location, appearance, and knowledge of preceding trauma, osteomyelitis, surgery or arthritis, or comparison with prior studies, a substantial number of abnormal foci remain indeterminate without the addition of radiographs, CT scans, or MRI. SPECT/CT.

- FDG is taken up by the salivary glands and excreted into the saliva. The parotid and submandibular salivary glands usually show mild uptake. Focal uptake may be seen in both benign and malignant lesions including Warthin tumours, pleomorphic adenomas and lymphoma. Benign granulomatous conditions such as sarcoidosis will also demonstrate increased uptake. FDG-PET cannot be used to differentiate benign from malignant parotid disease. Further investigated. Diffuse symmetrical uptake may be seen in a normal thyroid as well as in autoimmune thyroiditis.

VII. DYNAMIC CONTRAST-ENHANCED IMAGING (DCE IMAGING)

Dynamic Contrast-Enhanced MRI (DCE-MRI) is an advanced imaging technique that has gained significant interest and application in various medical fields, including oral radiology. By utilizing contrast agents and acquiring a series of images over time, DCE-MRI allows for the assessment of perfusion and vascular characteristics in tissues of interest. DCE-MRI in Oral Radiology capitalizes on the administration of contrast agents and dynamic image acquisition to evaluate tissue perfusion and vascular characteristics. Its ability to non-invasively assess oral lesions' vascularity and monitor treatment response makes it a valuable imaging technique in the diagnosis and management of oral cancers and other oral pathologies.

1. Working of Dynamic Contrast-Enhanced Imaging

- **Baseline Image Acquisition:** The DCE-MRI procedure starts with the acquisition of baseline images of the oral region without the administration of the contrast agent. These images serve as a reference for comparison during the subsequent dynamic imaging.
- **Contrast Agent Administration:** Next, a contrast agent, usually a gadolinium-based intravenous injection, is administered to the patient. The contrast agent contains paramagnetic properties that alter the relaxation times of surrounding water protons, leading to enhanced signal intensity in the MRI images.
- **Dynamic Imaging:** Following the contrast agent injection, a series of MRI images are acquired over time, usually at short intervals (seconds to minutes). These sequential images capture the temporal changes in contrast enhancement within the oral tissues, reflecting blood flow and vascular permeability.
- **Quantitative Analysis:** The acquired dynamic image data is subjected to post-processing and quantitative analysis to derive perfusion parameters. These parameters include measures of tissue perfusion, relative blood volume, permeability, and mean transit time, which provide valuable information about the functional status of the vascular system within oral lesions.

2. Advantages

- **Assessment of Tumor Vascularity:** DCE-MRI enables the evaluation of vascularity and perfusion in oral tumors, aiding in their characterization and differentiation from non-neoplastic lesions. This information is valuable for early diagnosis and treatment planning.
- **Monitoring Treatment Response:** DCE-MRI can track changes in tumor vascularity and perfusion in response to various treatments, such as chemotherapy and radiation

therapy. This helps in assessing treatment efficacy and guiding treatment modifications if needed.

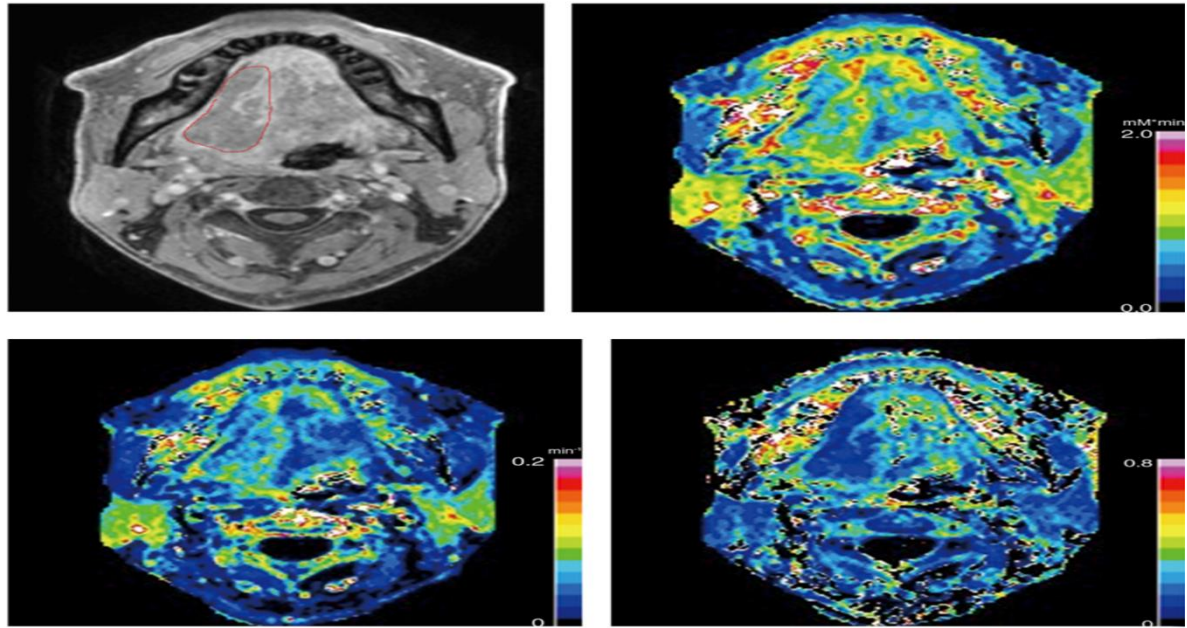
- **Detection of Metastatic Spread:** By providing detailed information about microvascular changes, DCE-MRI assists in the detection of potential metastatic lesions within the oral and maxillofacial region, supporting accurate staging of oral cancers.
- **Non-Invasive Nature:** DCE-MRI is a non-invasive imaging modality, making it a safe and patient-friendly option for assessing oral lesions and vascular characteristics without the need for ionizing radiation.
- **Quantitative Assessment:** DCE-MRI offers the ability to quantitatively analyze perfusion parameters, such as perfusion volume, permeability, and blood flow, providing objective and reproducible measurements.

3. Limitations

- **Limited Temporal and Spatial Resolution:** DCE-MRI requires a series of image acquisitions over time, leading to a trade-off between temporal resolution and spatial resolution. This limitation may impact the ability to capture rapid dynamic changes.
- **Contrast Agent Administration:** The use of contrast agents is necessary for DCE-MRI, which may raise concerns for patients with renal impairment or allergies to contrast media.
- **Data Analysis Complexity:** Proper analysis of DCE-MRI data requires sophisticated post-processing techniques and software, which may be time-consuming and demand expertise.

4. Applications

- **Tumor Characterization:** DCE-MRI aids in differentiating between malignant and benign oral lesions based on their distinctive perfusion patterns. Malignant tumors often exhibit higher vascularity and faster contrast agent uptake compared to benign lesions.
- **Treatment Response Monitoring:** DCE-MRI tracks changes in tumor perfusion and vascularity in response to therapies such as chemotherapy and radiation. It helps assess treatment efficacy and guide treatment modifications.
- **Detection of Metastasis:** DCE-MRI assists in detecting potential metastatic lesions within the oral and maxillofacial region, aiding in accurate staging of oral cancers.
- **Differentiation of Lesions:** DCE-MRI aids in distinguishing malignant oral tumors from benign lesions based on their distinctive perfusion patterns.
- **Preoperative Planning:** DCE-MRI provides detailed information about tumor margins, invasion extent, and proximity to vital structures, supporting surgical planning and reducing potential complications.
- **Evaluation of Angiogenesis:** DCE-MRI provides insights into the angiogenic process in oral tumors, which is crucial for understanding tumor growth and progression.
- **Research and Drug Development:** DCE-MRI is useful in research and drug development, as it can assess the efficacy of novel anti-cancer drugs targeting angiogenesis in oral tumors.



A 46-year-old male with tongue squamous cell carcinoma with TNM stage T4aN2bM0 disease.

VIII. DIAGNOSTIC ULTRASOUND

Ultrasound has emerged as a promising non-invasive, cross-sectional imaging technique in the field of dentistry. As an adjunct tool for diagnosing oral pathologies, ultrasound offers valuable advantages over traditional methodologies such as direct clinical examination, 2D radiographs, and cone beam computerized tomography. The growing demand for soft tissue imaging has spurred continuous advancements in transducer miniaturization and spatial resolution, enhancing the capabilities of ultrasound in dental applications.

1. Working Principle: Diagnostic ultrasound uses high-frequency sound waves that pass through tissues and encounter varying acoustic impedance. The differences in impedance cause sound waves to be reflected back as echoes. These echoes are then converted into electrical signals and processed to generate real-time images of the internal structures of the oral cavity and surrounding tissues.

2. Applications

- **Assessment of Oral Lesions:** Diagnostic ultrasound aids in differentiating between solid and cystic lesions in the oral cavity, assisting in treatment planning and biopsy guidance.
- **Examination of Salivary Glands:** It helps in identifying and characterizing salivary gland masses, detecting calculi in the ducts, and localizing lesions for further evaluation.
- **Evaluation of Neck Masses:** Diagnostic ultrasound is used to examine congenital, inflammatory, and neoplastic neck masses, aiding in diagnosis and guiding appropriate management.

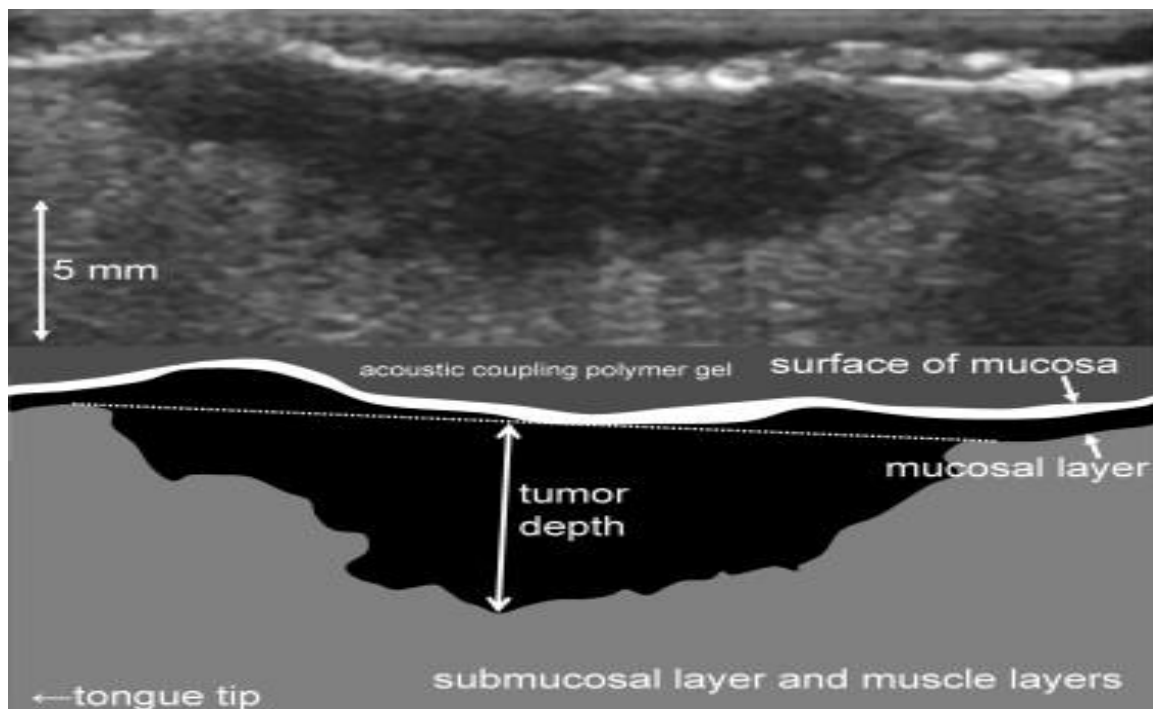
- **Detection of Vascular Abnormalities:** It can screen for atheromatous plaques, aneurysms, venous thrombosis, and stenosis in extracranial vessels of the neck.

3. Advantages

- **Safe Imaging Modality:** Diagnostic ultrasound does not use ionizing radiation, making it a safe imaging option without known harmful effects on tissues at the energy levels and doses used in diagnostics.
- **Soft Tissue Differentiation:** Ultrasound is effective at distinguishing between different soft tissues in the oral region, aiding in the characterization of various lesions and masses.
- **Real-Time Imaging:** Ultrasound provides real-time imaging, enabling dynamic assessments of structures, blood flow, and motion within the oral cavity.
- **Availability and Cost-Effectiveness:** Ultrasound equipment is widely available in medical settings, including dental clinics, and is generally more cost-effective compared to other imaging modalities.

4. Limitations

- **Limited Use in Bony Regions:** Ultrasound waves are absorbed by bone, limiting its application in regions with dense bone, such as the craniofacial area. This may hinder the assessment of bony pathologies.
- **Operator Dependency:** Obtaining high-quality ultrasound images relies heavily on the operator's skills and experience, making the technique operator-dependent.
- **Image Resolution:** Image resolution in ultrasound can sometimes be suboptimal, making it challenging for inexperienced operators to interpret images accurately.



Schematic drawing of the intraoral ultrasound of the tongue carcinoma. Note the three-layer structure (surface of mucosa, mucosal layer, submucosal layer and muscle layers) of the surrounding normal portion.

IX. ARTHROGRAPHY

Arthrography is a diagnostic imaging technique used to evaluate the soft tissue condition of the temporomandibular joint (TM joint). It plays a crucial role in providing valuable information about the integrity and position of the TM joint's disk and its posterior attachment. This non-invasive procedure is particularly useful when there is a suspicion of disk derangement, and conventional imaging methods show limited bony damage. Arthrography aids in differentiating between disk-related issues and other non-bony problems, allowing for more accurate diagnosis and targeted treatment approaches.

1. Working Principle: The arthrography procedure involves catheterizing the upper and lower joint spaces of the TM joint and injecting a small amount (0.5 to 1 ml) of radiographic contrast media, often iodine compounds. The contrast media helps visualize the joint components and the disk during various stages of jaw movement. X-ray images are taken with the jaws closed and progressively open, providing dynamic information about the position and movement of the joint components and the disk. The disk appears as a radiolucent void between the opaque areas of contrast media, indicating its position and integrity.

2. Applications

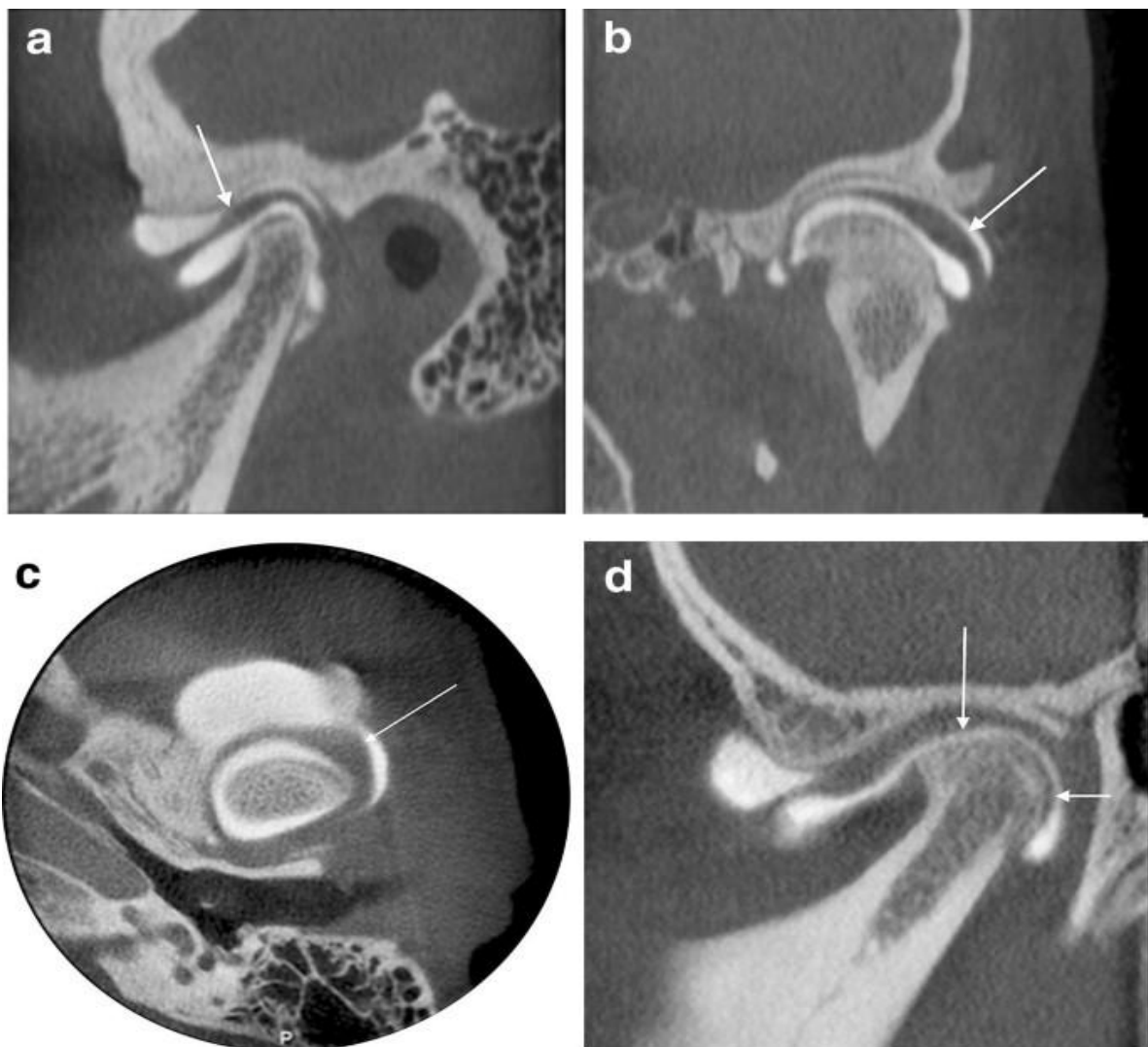
- **Chronic TMJ Pain:** Arthrography is helpful in diagnosing long-standing TMJ pain that does not respond to conventional treatments.
- **Joint Locking:** It is valuable in cases where there is a persistent history of joint locking.
- **Limited Mouth Opening:** Arthrography aids in the evaluation of limited mouth opening of unknown etiology.
- **Disk Integrity Assessment:** The procedure provides crucial information about the disk's integrity and helps differentiate disk derangement from other non-bony issues in the TM joint.

3. Advantages

- **Diagnostic Clarity:** Arthrography allows for dynamic visualization of the TM joint, enabling a more precise assessment of the joint components' movement and the presence of any disk derangement.
- **Soft Tissue Evaluation:** Unlike conventional imaging methods, arthrography specifically focuses on evaluating the soft tissues of the TM joint, providing unique insights into disk-related issues.
- **Disk Perforation Detection:** Arthrography can effectively detect any perforations in the disk, which are essential for accurate diagnosis and treatment planning.

4. Limitations

- **Painful Procedure:** Arthrography can be uncomfortable and painful for some patients, which may limit its use in certain cases.
- **Hypersensitivity to Iodine:** Patients with hypersensitivity to iodine or contrast media may be contraindicated for this procedure.
- **Risk of Fibrosis:** The use of iodine contrast media may lead to fibrosis in some cases, necessitating cautious consideration in certain patients.
- **Aseptic Requirements:** Strict asepsis must be maintained during the procedure to avoid complications and infection.
- **Capsule Rupture Risk:** If too much contrast media is injected, there is a risk of the joint capsule rupturing, causing additional complications.



Arthrography of the TMJ

X. XERORADIOGRAPHY

Xeroradiography, an electrostatic imaging technique similar to xeroxing, offers distinctive features that make it attractive for specific dental diagnostic situations. With pronounced edge enhancement, high contrast, and the option for positive and negative displays, xeroradiography serves as a valuable imaging system in dentistry. By eliminating the need for silver halide films, this method provides a convenient and efficient alternative for various dental applications. In this article, we explore the working principle, advantages, limitations, and applications of xeroradiography, emphasizing its potential impact on dental radiology.

1. Working Principle: Xeroradiography involves replacing the conventional X-ray film with a selenium-coated photoreceptor, known as the Xerox Plate. This photoreceptor uniformly distributes an electrostatic charge. During exposure, X-rays passing through a body part or object are absorbed by the selenium surface, leading to selective discharging. The resulting charged pattern, akin to a latent image, provides information about the distribution and amount of radiation absorbed, enabling the visualization of anatomical structures.

2. Applications

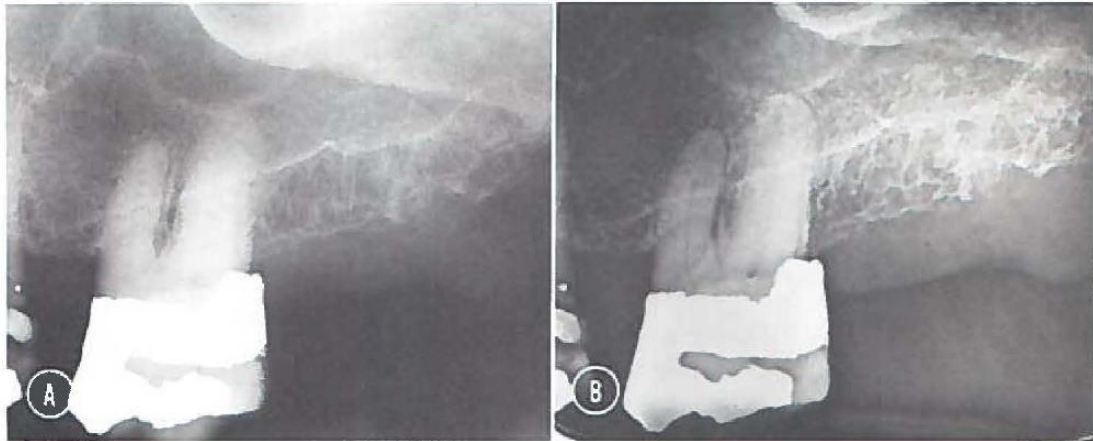
- Xeroradiography is particularly useful for cephalometry, providing accurate assessments of hard and soft tissue landmarks on a single film.
- In periodontal and periapical assessments, xeroradiography excels in revealing bony details with edge enhancement, aiding in diagnosing dental pathologies.
- The technique is valuable for sialography, offering clear visualization of fine duct structures in the salivary glands.
- Xeroradiography can assess soft tissue shadows in the pharynx and larynx, aiding in the diagnosis of various head and neck conditions.

3. Advantages

- Pronounced edge enhancement and high contrast enhance visualization of fine details and structures, making it useful for identifying subtle dental pathologies.
- The choice of both positive and negative displays offers flexibility in image interpretation, allowing clinicians to focus on specific aspects of interest.
- Xeroradiography provides good detail and wide latitude, making it valuable for assessing a variety of dental conditions.
- Elimination of silver halide films reduces costs and environmental impact, while also simplifying the imaging process.
- The technique requires a lower radiation exposure, ensuring patient safety during the diagnostic procedure.
- Xeroradiographs can be produced quickly, providing immediate access to diagnostic information for timely patient care.

4. Limitations

- Edge enhancement artifacts may occur, potentially impacting the accurate interpretation of certain images.
- The initial setup cost for xeroradiography processors can be higher compared to traditional radiography systems.
- Extraoral techniques may require higher radiation doses, which can be a limitation for certain patients.



- A. Conventional radiograph of the maxillary molar periapical region demonstrating poor bone imaging and poor soft-tissue detail.
- B. Similarly projected dental xeroradiography demonstrating superior images of bony structures and gingival soft-tissue structures.

XI. SIALOGRAPHY

Sialography is a valuable radiographic procedure used as a diagnostic adjunct for detecting and monitoring salivary gland diseases. This technique enables the examination of the ductal and acinar systems of major salivary glands by filling them with a radiopaque contrast agent, making them visible on radiographs. Sialography plays a crucial role in identifying the location, integrity, and internal architecture of salivary glands, while also aiding in the detection of various diseases that affect these structures.

1. **Working Principle:** The sialographic procedure involves the insertion of a contrast media-filled cannula into the salivary gland ducts. The contrast media is introduced to visualize the gland's internal structures and highlight any abnormalities. By fluoroscopically monitoring the filling phase, the operator determines the adequate volume of contrast media based on the gland's condition. The radiographic images obtained during the procedure provide valuable information about the gland's excretory function and can be used to study special features with different views.

2. Applications

- Detection of calculi or foreign bodies, whether radiopaque or radiolucent, within the salivary glands.

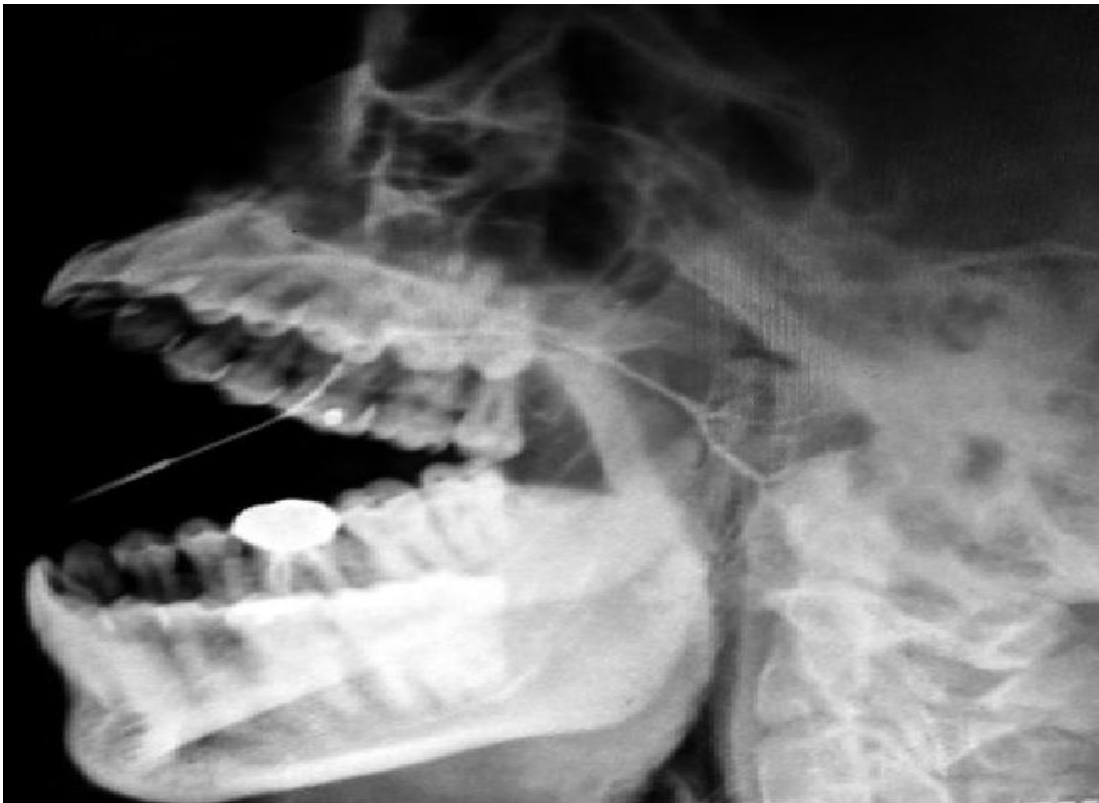- Determination of gland destruction due to obstructing calculi or foreign bodies, helping decide appropriate treatment strategies.
- Diagnosis of recurrent swellings and inflammatory processes in the salivary glands.
- Identification and localization of tumors, aiding in distinguishing between benign and malignant lesions.
- Guidance for selecting biopsy sites and planning dissections, including outlining the plane of the facial nerve.
- Monitoring the effectiveness of surgical procedures and detecting residual stones, tumors, or retention cysts.
- Therapeutic use, such as aiding in ductal debris drainage and producing therapeutic effects through contrast media injection.

3. Advantages

- Sialography offers a non-invasive means to assess the ductal and acinar systems of major salivary glands, aiding in the diagnosis of various salivary gland diseases.
- It provides detailed information about the location, size, and extent of obstructions or lesions, allowing for better treatment planning.
- By using both water-soluble and fat-soluble contrast media, sialography allows flexibility in imaging, enabling visualization of different structures and conditions.
- The procedure offers an efficient means to study the spatial relationships of glands and ducts through stereoscopic and subtraction views.
- Sialography can serve as a therapeutic procedure by aiding in the drainage of ductal debris and producing a therapeutic effect through the contrast media.

4. Limitations

- Sialography is contraindicated in patients with known sensitivity to iodine compounds or a history of severe asthmatic attacks following prior iodine contrast use.
- The procedure is not recommended during acute inflammation of the salivary system, as it can lead to severe foreign body reactions and pain.
- There is a risk of interference with subsequent thyroid function tests due to iodinated contrast material administration and retention.



©Association of Oral and Maxillofacial Surgeons of India

Normal parotid gland in Sialography

XII. EMERGING TECHNOLOGIES AND POINT TO CARE TESTING

1. Photoacoustic Imaging: Photoacoustic Imaging is an innovative and promising technique that addresses the limitations of conventional imaging modalities in dentistry. By enabling non-invasive, radiation-free imaging with high spatial resolution and cost-effectiveness, PAI has the potential to transform dental care significantly. Its applications in detecting oral and dental pathologies, assessing periodontal diseases, and improving veterinary oral health underscore its diverse scope. As research and development in this field continue to progress, PAI is poised to become an indispensable tool in the dental practitioner's arsenal, leading to more precise diagnoses, better treatment planning, and improved patient outcomes.

- **A Applications**

- **Detection of Oral and Dental Pathologies:** PAI holds the potential to detect a wide range of oral and dental problems, including tooth fractures, tooth resorption, dental caries, periodontal and gingival diseases, and missing teeth. By utilizing modulated laser waves, PAI can illuminate the tissue or substance of interest, and when the tissue absorbs the light pulse, it undergoes thermoelastic expansion, generating acoustic waves. These waves carry valuable information about the tissue's optical absorption, enabling precise and early detection of pathologies.

- **Assessment of Periodontal Diseases:** Periodontal diseases affect a substantial portion of the population, leading to severe gum inflammation and potential tooth loss. PAI can be instrumental in assessing the severity of periodontal diseases by visualizing the extent of inflammation and damage to the gum tissue. This non-invasive technique offers high spatial resolution and rapid image acquisition, making it a valuable tool for monitoring disease progression and treatment effectiveness.
- **Oral Health in Veterinary Practice:** Oral health is a growing concern in veterinary medicine, with a significant number of dogs and cats suffering from tooth resorption due to fractured tooth pulp exposure. PAI can play a vital role in evaluating dental health in animals, allowing veterinarians to diagnose and treat oral conditions effectively. The non-ionizing nature of PAI ensures safety during repeated imaging sessions in animals, facilitating comprehensive oral health management.

- **B Scope of Photoacoustic Imaging in Dentistry**

- **Non-Invasive and Radiation-Free Imaging:** One of the most significant advantages of PAI in dentistry is its non-invasive nature. Traditional X-ray and CT imaging involve ionizing radiation, which can be harmful when used frequently. PAI, on the other hand, eliminates this risk, making it an ideal option for regular oral examinations and monitoring of treatment progress without exposing patients to harmful radiation.
- **Enhanced Image Resolution and Tissue Differentiation:** PAI's ability to provide high spatial resolution images enables dentists to visualize intricate structures within the oral cavity with exceptional clarity. The technique offers superior tissue differentiation, allowing for the identification of subtle changes indicative of early-stage pathologies. This early detection can lead to timely intervention and improved treatment outcomes.
- **Cost-Effectiveness and Accessibility:** The cost-effectiveness of PAI compared to conventional imaging modalities makes it a practical choice for dental clinics and healthcare facilities. As the technology advances and becomes more widely available, it has the potential to revolutionize dental care, offering enhanced diagnostic capabilities at affordable costs.

2. Optical Coherence Tomography (OCT): Optical Coherence Tomography (OCT) is a revolutionary non-invasive, non-radiative optical diagnostic tool that has found widespread application in dentistry. Utilizing a low-coherence broadband near-infrared light source, OCT provides exceptional spatial resolution and real-time imaging capabilities. In recent years, it has emerged as a promising imaging technique for detecting qualitative and quantitative changes in dental hard and soft tissues. This review explores the progress and applications of dental OCT, emphasizing its potential for early diagnosis and treatment monitoring in dental health. By offering a non-invasive and real-time approach, OCT holds great promise in advancing oral health and disease management.

- **A Applications**

- **Early Detection of Dental Diseases:** OCT has proven to be highly effective in the early detection of dental diseases, including tooth decay (caries), periodontal diseases,

and oral cancer. Its ability to provide high-resolution images of dental tissues allows dentists to identify subtle changes and begin treatment at the earliest stages, leading to better patient outcomes.

- **Monitoring Dental Treatments:** Dental OCT serves as a valuable tool for monitoring the progress of various dental treatments. Dentists can use OCT imaging to assess the effectiveness of restorative procedures, evaluate the success of orthodontic treatments, and track the healing process after oral surgeries.
- **Assessment of Tooth Structure:** OCT offers a non-invasive method to assess tooth structure, including enamel, dentin, and cementum. Dentists can use OCT images to measure the thickness of remaining dentin above the pulp, aiding in treatment planning and prognosis evaluation.
- **Crack and Microleakage Detection:** OCT has the capability to detect cracks and microleakage in teeth and dental restorations. Early identification of these issues allows for timely interventions to prevent further damage and potential tooth loss.
- **Periodontal Health Monitoring:** Dental OCT provides visualization of periodontal ligaments and the detection of subgingival calculus. This aids in monitoring periodontal health, enabling dentists to identify and address periodontal disease at an early stage.
- **Mucosal Lesions and Vascular Lesions:** OCT has potential applications in imaging mucosal lesions, such as lichen planus and pemphigoid, and vascular lesions. By providing detailed images of these tissues, OCT can aid in the diagnosis and management of oral mucosal diseases.

- **B Scope Of Optical Coherence Tomography (OCT) In Dentistry**

- The scope of OCT in dentistry is continually expanding, driven by advancements in technology and research. As a non-invasive and real-time imaging modality, OCT holds promise for further applications and advancements in dental diagnosis and treatment. Some of the areas with potential for growth include:
 - **Integration with Treatment Planning:** OCT can be integrated into treatment planning software, allowing dentists to simulate treatment outcomes and optimize procedures for individual patients. This integration could enhance the precision and predictability of various dental interventions.
 - **Dental Implant Assessment:** OCT's ability to visualize bone structures and soft tissues makes it a potential tool for dental implant assessment. Dentists can use OCT to evaluate bone quality and volume, enhancing the accuracy of implant placement.
 - **Caries Management:** OCT could play a vital role in caries management, enabling dentists to monitor the progression of carious lesions and evaluate the effectiveness of non-invasive remineralization therapies.
 - **Endodontic Applications:** OCT may find applications in endodontics, providing insights into the complex root canal anatomy and helping dentists identify areas of infection or treatment failure.
 - **Patient Education and Communication:** OCT's ability to generate real-time and patient-friendly images can be utilized for patient education and communication. By visualizing dental conditions, patients can better understand their oral health status and treatment options.

- **Multimodal Imaging:** The combination of OCT with other imaging modalities, such as fluorescence or Raman spectroscopy, may lead to enhanced diagnostic capabilities and a comprehensive approach to dental diagnosis and treatment.
- 3. Raman Spectroscopy:** Raman Spectroscopy is a groundbreaking analytical technique discovered by C.V. Raman and his team in 1928. It involves the scattering of light through a pure medium, resulting in scattered light with a different frequency than the incident beam. This phenomenon, known as Raman scattering, provides unique spectral "fingerprints" of substances, offering valuable insights into molecular bonds and structures. In the biomedical field, Raman Spectroscopy has found extensive applications in understanding and diagnosing oral diseases, such as dental caries and periodontal diseases. With advancements in nanotechnology and optical technologies, this non-invasive technique holds immense promise for enhancing diagnostic accuracy and sensitivity, paving the way for improved oral disease management.

- **A Applications**

- **Dental Caries Detection:** Raman Spectroscopy has been utilized to assess changes in mineral content and crystallinity of enamel and dentin, enabling the early detection and evaluation of dental caries. It has the potential to improve preventive strategies and treatment planning for tooth decay.
- **Periodontal Disease Analysis:** By detecting subgingival bacteria and analyzing changes in saliva, Raman Spectroscopy offers valuable insights into the pathogenesis of periodontal diseases. This technique aids in understanding bone transformation and disease progression, facilitating more effective treatment strategies.
- **Oral Cancer Diagnosis:** Raman Spectroscopy has shown promising results in diagnosing and classifying oral cancers, including oral squamous cell carcinoma (OSCC). By analyzing spectral patterns, this technique helps in differentiating malignant lesions from precancerous conditions and other oral diseases.
- **Surgical Margin Assessment:** Raman Spectroscopy assists in accurately assessing surgical margins during oral cancer resection. By distinguishing tumor tissues from surrounding healthy tissues, it provides valuable information to clinicians for precise tumor removal, potentially improving patient outcomes.
- **Prediction of Recurrence:** Raman Spectroscopy can predict the recurrence rate of oral cancers by analyzing serum and mucosa samples. By detecting minor molecular changes, it offers a potential screening tool to identify high-risk patients for timely intervention.

- **B Scope of Raman Spectroscopy:** The scope of Raman Spectroscopy in oral diseases is vast and promising. Advancements in nanotechnology, optical microscopes, and fiber optics have enabled the integration of Raman Spectroscopy with enhanced techniques, such as Surface-enhanced Raman Spectroscopy (SERS) and confocal Raman Spectroscopy. These developments enhance signal intensity and signal collection, improving diagnostic accuracy and sensitivity.

Raman Spectroscopy's non-destructive nature and potential for in vivo applications offer a safer and patient-friendly approach to diagnose and monitor oral diseases. As research and technology progress, Raman Spectroscopy is expected to

play an increasingly significant role in revolutionizing oral disease diagnosis and treatment.

XIII. ARTIFICIAL INTELLIGENCE AND DEEP LEARNING

Artificial intelligence (AI) and deep learning have emerged as transformative technologies with applications in various industries, including dentistry and oral and maxillofacial (OMF) radiology. The history of AI has seen periods of excitement and skepticism, but recent advances in deep learning and neural networks have led to significant breakthroughs, such as AI-powered autonomous cars and game-winning algorithms. AI is now quietly infiltrating various aspects of our lives, including dental and medical image analysis. In OMF radiology, AI has the potential to revolutionize diagnostic accuracy, improve treatment planning, and enhance overall patient care. However, there are challenges to overcome, such as ensuring trust in AI diagnosis and guarding against malicious uses.

Machine Learning and Deep Learning: Machine learning, a subset of AI, involves computer models that learn from experience without explicit instructions. It encompasses supervised learning (with labeled data), unsupervised learning (with unlabeled data), and reinforcement learning (based on feedback in dynamic environments). Deep learning, a type of machine learning, utilizes artificial neural networks to derive high-level abstractions and complex features from large datasets, enabling remarkable achievements in image analysis.

1. Working Of Ai in Oral Radiology

- **Radiographic Diagnosis:** AI has been applied to diagnose a range of OMF diseases, including dental caries, periodontal disease, osteosclerosis, cysts, and tumors. Deep learning models, such as Convolutional Neural Networks (CNNs), have shown promising results in automated diagnosis and differential diagnosis systems.
- **Radiographic Analysis:** AI has been used to detect and classify teeth, assess bone quality (osteoporosis) using panoramic radiographs, estimate bone age using hand-wrist radiographs, and localize cephalometric landmarks. CNNs and other deep learning models have been used to improve the quality of blurred images and reduce metal artifacts in radiographs.

2. Applications

- **Automated Diagnosis:** AI can aid in diagnosing various dental and maxillofacial pathologies, enabling faster and more accurate treatment planning.
- **Bone Age Assessment:** AI can estimate bone age using radiographs, assisting in pediatric dentistry and orthodontics.
- **Forensic Dentistry:** AI can be utilized in postmortem identification, age estimation, and sex determination using dental radiographs.
- **Dental Implant Planning:** AI can assist in the planning and placement of dental implants by analyzing radiographic images to determine the ideal location and angle for implant placement. This can improve the accuracy of implant placement and reduce the risk of complications.
- **Temporomandibular Joint (TMJ) Analysis:** AI algorithms can be used to analyze TMJ radiographs and identify abnormalities or disorders related to the

temporomandibular joint. This can aid in the diagnosis and treatment planning for TMJ disorders.

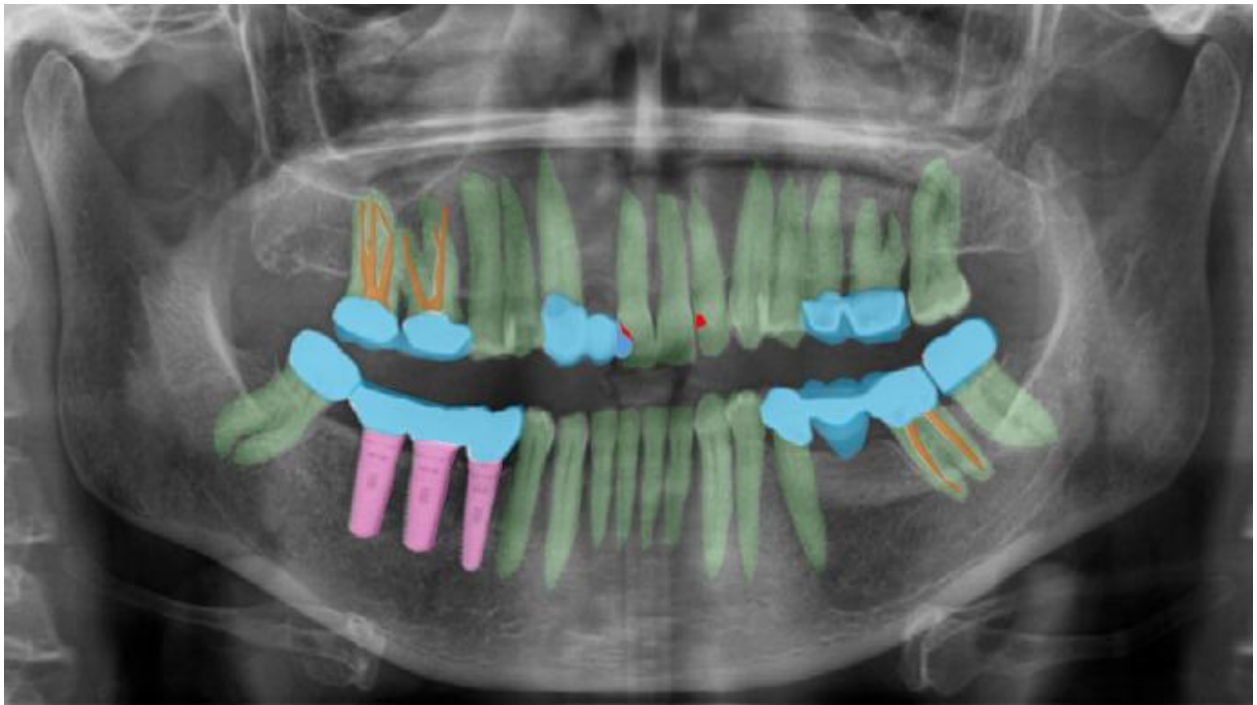
- **Root Canal Treatment Assistance:** AI can help in identifying the complexity and morphology of root canal systems in dental radiographs. This information can assist endodontists in planning and performing root canal treatments more effectively.
- **Automated Detection of Pathologies:** AI algorithms can be trained to detect various pathologies in oral radiographs, such as cysts, tumors, periapical lesions, and periodontal diseases. This automated detection can aid in early diagnosis and prompt treatment.
- **Orthodontic Treatment Planning:** AI can analyze cephalometric radiographs and aid orthodontists in treatment planning, including assessing tooth movement, predicting growth patterns, and evaluating treatment outcomes.
- **Automated Report Generation:** AI can generate structured reports based on the analysis of radiographic images, providing dentists and radiologists with detailed and standardized reports for patient records.
- **Disease Progression Monitoring:** AI can be used to track and monitor the progression of certain dental conditions over time by comparing sequential radiographs and identifying changes.
- **Fracture Detection:** AI algorithms can help in detecting fractures or traumatic injuries in dental radiographs, facilitating quick diagnosis and appropriate treatment.

3. Advantages

- **Improved Diagnostic Accuracy:** AI systems can analyze radiographic images with great precision, reducing the chances of misinterpretation or oversight.
- **Enhanced Efficiency:** AI can analyze large datasets rapidly, enabling OMF radiologists to focus on complex cases and optimize their workflow.
- **Automation and Assistance:** AI can assist in early detection of diseases, mark suspicious areas for further examination, and classify teeth and anatomical structures automatically.

4. Limitations

- **Data Requirements:** Developing AI systems demands large and accurately labeled datasets, which can be costly and time-consuming to create.
- **Reliability:** The performance of AI systems heavily depends on the quality of training data and model architecture, raising concerns about trust and explainability.
- **Security Concerns:** AI-powered hacking of DICOM images poses a threat to patient safety, necessitating robust security measures.



Example of complex labeling of dental panoramic radiography. In two-dimensional radiographs where structures overlap, it is often difficult to clearly distinguish and outline three-dimensional anatomical structures. Green: teeth, pink: implant, sky: prosthodontics, brown: endodontic filling, red: dental caries.

XIV. CONCLUSION

The field of diagnostic imaging techniques in dentistry has witnessed remarkable advancements, transforming the landscape of dental diagnostics. As the field continues to evolve, it is evident that diagnostic imaging techniques will continue to play a pivotal role in early and precise disease detection, ultimately leading to improved patient outcomes and enhanced quality of life.

This book chapter serves as a valuable resource, providing readers with insights into the vast array of diagnostic imaging techniques available today. From the foundations of traditional radiography to the frontiers of emerging technologies, the chapter showcases the relentless pursuit of excellence in dental diagnostics and the ongoing commitment to advancing patient care through the power of imaging science.

REFERENCES

- [1] White, Stuart C., and Michael J. Pharoah. *Oral Radiology: Principles and Interpretation*, 6th ed., Mosby, 2009, pp. 175-190, 221-222.
- [2] Karjodkar, Freny R. *Textbook of Dental and Maxillofacial Radiology*, 2nd ed., Jaypee Brothers Medical Publishers, 2019.
- [3] Venkatesh, Elluru, and Snehal Venkatesh Elluru. "Cone Beam Computed Tomography: Basics and Applications in Dentistry." *Journal of Istanbul University Faculty of Dentistry*, vol. 51, no. 3 Suppl 1, 2 Dec. 2017, pp. S102-S121. doi:10.17096/jiufd.00289.
- [4] Goo, Hyun Woo, and Jin Mo Goo. "Dual-Energy CT: New Horizon in Medical Imaging." *Korean Journal of Radiology*, vol. 18, no. 4, 2017, pp. 555-569. doi:10.3348/kjr.2017.18.4.555.

- [5] Roele, E.D., Timmer, V.C.M.L., Vaassen, L.A.A. et al. "Dual-Energy CT in Head and Neck Imaging." *Current Radiology Reports*, vol. 5, no. 5, 2017, pp. 19. doi:10.1007/s40134-017-0213-0.
- [6] O'Connor, J P B et al. "Dynamic Contrast-Enhanced Imaging Techniques: CT and MRI." *The British Journal of Radiology*, vol. 84, Spec No 2, Spec Iss 2, 2011, pp. S112-S120. doi:10.1259/bjr/55166688.
- [7] Gaddikeri, S., Gaddikeri, R.S., Tailor, T., and Anzai, Y. "Dynamic Contrast-Enhanced MR Imaging in Head and Neck Cancer: Techniques and Clinical Applications." *American Journal of Neuroradiology*, vol. 37, no. 4, April 2016, pp. 588-595. doi:10.3174/ajnr.A4458.
- [8] Chikui, Toru et al. "Dynamic Contrast-Enhanced MRI of Oral Squamous Cell Carcinoma: A Preliminary Study of the Correlations between Quantitative Parameters and the Clinical Stage." *The British Journal of Radiology*, vol. 88, no. 1050, 2015, 20140814.
- [9] Rodriguez Betancourt, Manda et al. "Overview of Ultrasound in Dentistry for Advancing Research Methodology and Patient Care Quality with Emphasis on Periodontal/Peri-implant Applications." *Zeitschrift für Medizinische Physik*, 2023, ISSN 0939-3889, doi:10.1016/j.zemedi.2023.01.005.
- [10] Hayashi, Takafumi. "Application of Ultrasonography in Dentistry." *Japanese Dental Science Review*, vol. 48, no. 1, 2012, pp. 5-13, ISSN 1882-7616, doi:10.1016/j.jdsr.2011.05.001.
- [11] Levring Jäghagen, E., and Ahlqvist, J. "Arthrography of the Temporomandibular Joint: Main Diagnostic and Therapeutic Applications." *Clin Dent Rev*, vol. 4, no. 2, 2020, doi:10.1007/s41894-019-0064-6.
- [12] Gratt, B M et al. "Dental Xeroradiography as an Adjunct in the Evaluation of Oral Cancer: A Preliminary Report." *Oral Surgery, Oral Medicine, and Oral Pathology*, vol. 49, no. 4, 1980, pp. 303-308.
- [13] Agni, N.A. "Salivary Gland Pathologies." *Oral and Maxillofacial Surgery for the Clinician*, edited by K. Bonanthaya, et al., Springer, Singapore, 2021, pp. 46. doi:10.1007/978-981-15-1346-6_46.
- [14] Heo, Min-Suk et al. "Artificial intelligence in oral and maxillofacial radiology: what is currently possible?." *Dento maxillo facial radiology* vol. 50,3 (2021): 20200375. doi:10.1259/dmfr.20200375.
- [15] Sari, Atika Windra, et al. "Recent development of photoacoustic imaging in dentistry: A review on studies over the last decade." *The Saudi Dental Journal*, vol. 35, no. 5, 2023, pp. 423-436. ISSN 1013-9052. doi: 10.1016/j.sdentj.2023.05.013.
- [16] Hsieh, Yao-Sheng et al. "Dental optical coherence tomography." *Sensors (Basel, Switzerland)* vol. 13,7 8928-49. 12 Jul. 2013, doi:10.3390/s130708928.
- [17] Zhang, Yuwei, et al. "Raman Spectroscopy: A Potential Diagnostic Tool for Oral Diseases." *Frontiers in Cellular and Infection Microbiology*, vol. 12, 2022, article 775236. DOI: 10.3389/fcimb.2022.775236.
- [18] Ziegler SI. "Positron emission tomography: principles, technology, and recent developments." *Nuclear Physics A*, 2005 Apr 18;752:679-87.
- [19] Özel HE. "Use of PET in head and neck cancers." *Turkish Archives of Otorhinolaryngology*, 2015 Jun;53(2):73.
- [20] Guledgud MV, Patil K, Shankar HJ, Deshpande P, Raman R. "Magnetic resonance imaging in head and neck radiodiagnosis: An overview." *Journal of Medicine, Radiology, Pathology and Surgery*, 2015 Jul 1;1(4):24-30.
- [21] Patel PR, De Jesus O. "CT Scan." InStatPearls [Internet] 2023 Jan 2. StatPearls Publishing.
- [22] *Advances in dental imaging – DCNA* vol 37, No. 4: Oct 1993.
- [23] Panebianco, V., & Fütterer, J. J. *MDCT and MRI in Genitourinary Imaging*. Springer Science + Business Media, 2015.
- [24] Zhang, Y., Ren, L., Wang, Q., Wen, Z., Liu, C., & Ding, Y. "Raman Spectroscopy: A Potential Diagnostic Tool for Oral Diseases." *Frontiers in Cellular and Infection Microbiology*, 2022.
- [25] Li, C., Feng, C., Xu, R., Jiang, B., Li, L., He, Y., Tu, C., & Li, Z. "The emerging applications and advancements of Raman spectroscopy in pediatric cancers." *Frontiers in Oncology*, 2023.
- [26] Tawakol Ali, I., Thomas, C., Elbanna, K. Y., Mohammed, M. F., & Berger, F. H. "Gastrointestinal Imaging: Emerging Role of Dual-Energy Computed Tomography." *Current Radiology Reports*, 2017.
- [27] Kaur, S., Singh, R., Kaur, A., Kainth, A., & Kainth, M. "Diagnostic aids in dentistry - An overview." *Archives of Dental Research*, 2023.
- [28] Chouhan, S., Sansanwal, M., Bhateja, S., & Arora, G. "Cone beam computed tomography implications in Dentistry." *IP International Journal of Maxillofacial Imaging*, 2020.
- [29] Schmoltd, D. L., Occeña, L. G., Abbott, A. L., & Gupta, N. K. "Nondestructive evaluation of hardwood logs: CT scanning, machine vision, and data utilization." *Nondestructive Testing and Evaluation*, 1998.
- [30] Patil, D. J., More, C. B., Venkatesh, R., & Shah, P. "Insight into the Awareness of CBCT as an Imaging Modality in the Diagnosis and Management of ENT Disorders: A Cross-Sectional Study." *Indian Journal of Otolaryngology and Head & Neck Surgery*, 2020.

- [31] Shokouhi, E. B., Welch, R., Sivagurufthan, K., & Mandelis, A. "Multispectral truncated-correlation photothermal coherence tomography imaging modality for detection of early-stage dental caries." *Biomedical Optics Express*, 2022.
- [32] Dickie, B., & van Houdt, P. J. "Dynamic contrast-enhanced MRI." Elsevier BV, 2023.
- [33] Gulati, V., & Chhabra, A. "Qualitative and Quantitative MRI Techniques for the Evaluation of Musculoskeletal Neoplasms." *Seminars in Roentgenology*, 2021.
- [34] Alabdulwahid, A. "Cone beam computed tomography: Still a blessing for maxillofacial imaging." *Journal of Dental Health, Oral Disorders & Therapy*, 2021.
- [35] Kabadi, S. J., Fatterpekar, G. M., Anzai, Y., Mogen, J., Hagiwara, M., & Patel, S. H. "Dynamic Contrast-Enhanced MR Imaging in Head and Neck Cancer." *Magnetic Resonance Imaging Clinics of North America*, 2018.
- [36] Liang, Y., Shi, J., He, Q., Sun, G., Gao, L., Ye, J., Tang, X., & Qu, H. "Hsa_circ_0026416 promotes proliferation and migration in colorectal cancer via miR-346/NFIB axis." *Cancer Cell International*, 2020.