

ROLE OF PSI IN ORAL MAXILLOFACIAL SURGERY: FRONTIER IN RECONSTRUCTIVE SURGERIES

Abstract

Aim: To elucidate the significance of Patient-Specific Implants (PSIs) in reconstruction of challenging maxillofacial hard tissues defects, requiring precise replacement of deficient tissue to achieve favourable outcomes. Also, to highlight the vital role of PSIs in rehabilitation of Post COVID Mucor maxillectomy patients providing maximal stability, functionality and improved quality of life.

Background: Conventionally, various autografts and alloplastic materials have been used in the reconstruction of complex maxillofacial defects, but were time consuming and didn't assure reliable outcomes. The use of individualized designed biomaterials has opened new possibilities in reconstructive surgery, and now, it is possible to use the patient's computed tomography (CT) to construct patient-specific implants (PSIs). Titanium implants are Customizable, Easily Workable (especially with the help of 3D virtual planning techniques), Bioinert, and Non-porous, they represent an ideal alloplastic material for facial hard tissue reconstruction.

Conclusion: Patient-Specific Implants (PSIs) show great potential for individuals with oral and craniomaxillofacial defects, whether resulting from trauma or post COVID maxillectomy. The reconstruction of these intricate anatomical areas provides a reliable alternative, enabling safe and time-efficient procedures. Ongoing advancements in Computer-Aided Design and Computer-Aided Manufacturing (CAD/CAM) technologies facilitate the

Authors

Dr. Vyomika Bansal
Junior Resident
Department of Oral & Maxillofacial Surgery
Faculty of Dental Sciences
IMS, BHU, Varanasi, India.

Dr. Akhilesh Kumar Singh
Associate Professor
Department of Oral & Maxillofacial Surgery
Faculty of Dental Sciences
IMS, BHU, Varanasi, India.

Dr. Naresh Kumar Sharma
Professor & Head
Department of Oral & Maxillofacial Surgery
Faculty of Dental Sciences
IMS, BHU, Varanasi, India.

Dr. Arjun Deepak Mahajan
Junior Resident
Department of Oral & Maxillofacial Surgery
Faculty of Dental Sciences
IMS, BHU, Varanasi, India.

Dr. Akhilesh Kumar Singh
Associate Professor
Department of Oral & Maxillofacial Surgery
Faculty of Dental Sciences
IMS, BHU, Varanasi, India.
aksingh.dent@bhu.ac.in

rapid customization of implant design and fabrication, bringing us closer to achieving the optimal patient-specific implant.

Keywords: Patient Specific Implant, Post-Mucormycosis Maxillectomy , CAD/CAM Technology.

I. INTRODUCTION

In today's medical landscape, the concept of "Personalized Dentistry" has gained significant importance. This concept provides treatment according to an individual's unique characteristics such as age, sex, facial structure, contour, size, and shape. This patient-centric approach harnesses the wealth of information available for each individual to deliver the best possible outcomes for their healthcare needs.

In the 21st century, surgeons are driven by a pursuit of superior results, are increasingly shifting away from stock designs intended for the average patient. Instead, they are embracing customized solutions that precisely fit each individual. The intricate and distinct nature of the facial skeleton presents formidable challenges for maxillofacial surgeons. Therefore, there is a growing imperative to reconstruct facial structural defects with the utmost precision, ultimately enhancing patient outcomes.

Recent advancements in radiodiagnosis, notably the integration of Computer-Aided Design and Computer-Aided Manufacturing (CAD/CAM) technology, have ushered in a new era of personalized prostheses in oral and maxillofacial surgery. This technology has become increasingly accessible and cost-effective, empowering more patients to benefit from tailored solutions. While surgeons have traditionally employed a range of autogenous and alloplastic materials, achieving precise replication of lost tissue details has remained a persistent challenge.

The introduction of 3-dimensional printing technology in the biomedical field has revolutionized the surgical repair of maxillofacial defects. These defects can arise from congenital factors, trauma, previous surgeries, or various benign and malignant maxillofacial pathologies. Through patient-specific implants (PSIs) created using 3D printing, surgeons now have a powerful tool to address these complex cases with unmatched precision. This transformative approach is paving the way for more successful and aesthetically pleasing outcomes, marking a significant leap forward in the field of maxillofacial surgery.

II. A “NEW ERA” OF PATIENT SPECIFIC IMPLANTS

In 2012, **Ciocca** and colleagues marked a milestone by reporting the pioneering use of a patient-specific implant (PSI) for reconstructing a mandibular defect resulting from a hemimandibulectomy. This groundbreaking procedure utilized a titanium alloy plate, crafted through direct metal laser sintering and guided by Computer-Aided Design and Computer-Aided Manufacturing (CAD/CAM) technology.

Today we find ourselves in the midst of a digital dentistry revolution that has profoundly impacted oral and maxillofacial surgery. At the heart of this transformation are three-dimensional (3D) printers, which have empowered surgeons with unprecedented precision and efficiency. Unlike the early days when resin materials dominated, modern 3D printers can now produce patient-specific implants using biocompatible titanium materials that have passed rigorous tests for dental implant suitability.

This evolution reflects not only the remarkable progress in technology but also the dedication of medical pioneers in their quest to enhance patient care. As a result, the realm of

oral and maxillofacial surgery stands on the threshold of even greater possibilities, promising improved outcomes and quality of life for patients in need of reconstructive procedures.

III. MATERIAL USED FOR MANUFACTURING PSIs IN FACE

The choice of material for manufacturing Patient-Specific Implants (PSIs) in maxillofacial applications is a critical consideration, driven by the need for specific attributes:

1. **Biocompatibility:** The material must be safe within the human body.
2. **Durability:** It should withstand the rigors of the facial environment.
3. **Radiolucency:** It should allow for clear imaging without interference.
4. **Lightweight:** Ideally, it should be lightweight to reduce the burden on the patient.
5. **Cost-Effective:** Cost is a significant factor in selecting the material.

Materials commonly used for maxillofacial PSIs include **metals** and **polymers**.

Titanium has emerged as the material of choice due to its exceptional qualities. It boasts high tensile strength, is lightweight, fosters osseointegration (bone attachment), and resists corrosion.

Polymers also find utility in maxillofacial PSIs. Silicone, a polymerized dimethyl siloxane, is prevalent, particularly for soft tissue augmentation. These implants offer intraoperative adjustability. For addressing bone defects, polyetheretherketone (PEEK) and polymethylmethacrylate (PMMA) are popular polymer choices. PEEK's semicrystalline polyaromatic nature equips it to withstand repeated stress, making it the preferred polymer for maxillofacial implants.

PSIs offer a precise fit with the added advantage of shorter rehabilitation times in cases of congenital craniofacial deformities (e.g., *Crouzon or Treacher-Collins syndrome, hemifacial microsomia*) or defects arising from trauma or pathological lesions. These conditions often entail both aesthetic and functional issues, such as facial disharmony, asymmetry, and masticatory problems. PSIs, in contrast to autogenous bone grafting, eliminate donor site morbidity, avert surgical failure, and obviate subsequent reoperation challenges.

However, it's crucial to note that the choice of material can affect biocompatibility, potentially posing issues for the patient. Furthermore, the material cost can contribute to increased surgical expenses. Therefore, selecting the right material for PSIs necessitates a judicious balance between biocompatibility, durability, and cost-effectiveness, all while adhering to the unique demands of each patient's condition

IV. USE OF PSIs in MAXILLOFACIAL RECONSTRUCTION

There are currently various areas of maxillofacial surgery that uses PSIs including;

- Reconstruction of the maxillofacial skeleton defects i.e., maxilla or mandible post-ablative surgeries (Oral cancer, benign tumors and post covid mucor mycosis)

- Correction of post-traumatic secondary facial deformities
- Total Temporo-mandibular joint replacement
- Orthognathic surgery

In modern maxillofacial surgery, Patient-Specific Implants (PSIs) find application in several key areas:

1. Reconstruction of Maxillofacial Skeletal Defects: PSIs are instrumental in restoring the integrity of the maxillofacial skeleton post-ablative surgeries, such as those following oral cancer treatment, removal of benign tumors, or addressing the aftermath of COVID-19-related mucor mycosis. Previously, rigid fixation plates and screws designed for "average" maxillo-mandibular dimensions were used. However, the advent of PSIs has revolutionized this process.

- The PSI fabrication process involves transmitting DICOM data from preoperative CT scans to a "**Virtual Surgical Planning**" team.
- Collaborative discussions between medical engineers and surgeons determine the PSI design, the number of required implants, and the surgical plan's finalization.
- Manufacturers subsequently supply *customized cutting guides, reconstruction plates, sterilizable stereo lithic models, and a detailed surgical plan.*

PSIs, in combination with **composite flap reconstruction techniques**, simplify complex mandibular defect reconstructions. They allow for precise 3D orientation and placement of bony flap segments, reducing surgical time and enhancing reconstruction reliability. Moreover, PSIs facilitate the placement of end osseous implants during primary composite flap placement, thanks to specific drill guides.

Notably, fibula reconstruction's accuracy falls short compared to virtual surgical planning due to the size of fibula cutting guides over an intact periosteum, a margin of 0.4 mm being considered during CAD/CAM guide fabrication.

Reconstruction of the maxilla and orbito-zygomatic regions, characterized by complexity and proximity to nasal cavities and dentition, benefits from PSIs. They enable precise orientation of the vascular portion, crucial for reconstructing the alveolar aspect of surgical defects.

2. Correction of Post-Traumatic Secondary Facial Deformities: Secondary reconstruction addresses residual skeletal deformities arising from pan facial trauma. It becomes necessary when primary surgical treatment yields unsatisfactory outcomes or when no initial treatment was provided. Inaccurate reduction or lingering defects in the midface, particularly affecting the *zygomatic bone, orbital walls, maxilla, and mandible, can lead to various functional and aesthetic consequences*, including changes in sagittal projection, facial height, facial width, asymmetry, visual function impairment, masticatory dysfunction, malocclusion, and tempromandibular joint disorders.

Virtual planning technology guides surgical interventions either via repositioning guides and preoperatively bent conventional plates or through CAD/CAM-fabricated osteotomy guides and PSIs.

- 3. Total Temporo-Mandibular Joint (TMJ) Replacement:** Severe end-stage TMJ disease necessitates replacement and reconstruction of the TMJ complex, including the fossa and condyle-ramus unit. Historically, various alloplastic materials, such as **Vitallium**, **Proplast-Teflon-coated Vitallium**, and **Dacron/Proplast-Teflon/ultra-high-molecular-weight polyethylene**, were used for TMJ replacement.

In 1993, PSIs utilizing CAD/CAM technology entered the scene. This approach involves several steps, beginning with a pre-resection CT scan to fabricate a stereo lithic skull model tailored to the patient's anatomy. The cranial base-mandible gap must measure at least 13 mm post-resection to accommodate the implant.

The post-resection skull model is then used for designing and fabricating TMJ components specific to the patient's anatomy and surgical defect. The TMJ fossa component comprises unalloyed titanium mesh bonded to an ultra-high-molecular-weight polyethylene articulating surface, while the mandibular component combines a cobalt chromium-molybdenum alloy condylar head with a titanium-aluminium-vanadium extra low interstitial alloy mandibular body. Virtual surgical planning software aids in creating intraoperative cutting guides to replicate the planned resection and joint reconstruction.

- 4. Orthognathic Surgery:** 3D imaging and CAD/CAM technology have revolutionized orthognathic surgery. Traditional pre-surgical planning, involving cephalometric analysis, facebow transfer, plaster models, and model tables, has been replaced with digital planning, saving both patient and surgeon time.

This advanced technology provides insight into potential intraoperative challenges, such as proximal and distal segment collisions in sagittal split osteotomy or bony interferences during Le Fort I impaction.

Mock surgery guides surgical procedures, with occlusal wafers guiding miniplate placement intraoperatively. Patient-specific bone-borne guides and implants eliminate the need for occlusal wafers, expediting occlusion.

The use of PSIs in orthognathic surgery offers several advantages, including ideal 3D orientation of the maxilla and mandible, negating the need for intraoperative plate bending, eliminating intermaxillary fixation requirements, and deploying patient-specific drill guides to ensure safe implant placement.

While PSIs bring remarkable benefits to these areas of maxillofacial surgery, there are certain disadvantages to consider. PSIs can be expensive, although these costs may be offset by reduced operating room time. There is also a delay in processing for PSI fabrication, and impromptu intraoperative decisions can be challenging to make. Additionally, transverse stability may be unpredictable in cases of segmental surgery.

V. PSIs: “SAVIOURS” IN POST-COVID MUCOR

Mucor mycosis is an aggressive fungal infection that primarily targets immunocompromised elderly individuals. During the COVID-19 pandemic in India, an alarming 77.6% of cases manifested as Rhino-cerebral Mucor mycosis. The primary culprits behind COVID patients contracting Rhizopus Oryza are the excessive administration of corticosteroids, poorly managed diabetes, extended periods in intensive care units, and individuals undergoing dialysis. These factors weaken the immune system, creating a favourable environment for the invasive fungal infection to thrive

Oral manifestations of the mucor mycosis;

1. Massive tissue destruction followed by nonhealing ulcers
2. Osseous destruction
3. Formation of oroantral communications etc.

Mucor mycosis, in its various forms, encompasses Rhino-cerebral involvement affecting the sinus and brain, Pulmonary affecting the lung, Gastrointestinal affecting the digestive tract, Cutaneous affecting the skin, and Disseminated mucor mycosis which disseminates through the bloodstream. Surgical intervention is crucial in managing this debilitating disease, often necessitating the excision of necrotic bone, which may extend to total or partial maxillectomy, followed by primary closure using buccal and palatal mucosa. The resulting tissue and bone defects can vary in complexity depending on the extent of tissue loss.

During the second wave of the COVID-19 pandemic, it was observed that this infection not only affected the geriatric population but also afflicted younger individuals with no preexisting medical conditions. Post-COVID Mucor mycosis leaves individuals with significant maxillofacial defects, imposing a substantial financial burden and enduring emotional scars.

Rehabilitating such patients poses a formidable challenge for maxillofacial surgeons, considering the larger defect size and anatomical complexities involved. Therefore, the imperative for customized implants arises, designed to anchor to adjacent residual structures such as the zygomatic, pterygoid, nasal, and orbital floors. These patient-specific zygomatic implants offer maximal stability and functionality to post-mucor maxillectomy patients in a relatively shorter timeframe, minimizing surgical morbidity and enhancing their quality of life.

1. Challenges for Surgeon and Prosthodontist In Rehabilitation of Patients with Post – Covid Rhino-Maxillary Mucor Mycosis:

- Lack of maxillary bone including pterygoid plates sometimes zygomatic bone involvement
- Adherence of nasal and sinus mucosa with palatal mucosa
- Fibrosed palatal mucosa
- Loss of lip support
- Reduced stress bearing area
- Lack of vertical guidance

- Over closure of mandible need to be addressed during rehabilitation.
- 2. Points to Remember before Going for PSI in Mucor Mycosis Affected Patients:** Patients eligible for PSI (Patient-Specific Implant) placement include those discharged from the ward 6 months to 1 year prior, exhibiting improved clinical and endoscopic conditions with no disease evidence. Additionally, their remaining bone must be sturdy enough to support PSI. The innovative use of stereolithic models in oral and maxillofacial surgery was initially introduced by Brix and Lambrecht in 1987. These "*pre-bending*" printed models are manually customized to match a specific defect before the surgery day. This approach ensures precise adaptation of the reconstruction plate within the patient's oral cavity without the need for anesthesia, streamlining the surgical process and enhancing patient outcomes.

VI. PROCEDURE FOR PSI FABRICATION

1. The pre-operative CT scan is prepared as a DICOM file and sent to a virtual surgical planning company.
2. To ensure optimal surface detail, the CT scan's slice thickness is set to less than 1.0 mm, enabling precise manufacturing of surgical guides and implants.
3. A web meeting is arranged between the surgeon and an engineer from the planning company. During this meeting, they collaborate to plan the surgical resection, design surgical guides, and create a reconstruction plate.
4. Following the web meeting, a comprehensive report summarizing the surgical plan is emailed to the surgeon. This report serves as a basis for final design approval before proceeding with fabrication.
5. The surgical planning company manufactures the cutting guides, reconstruction plate, and optionally provides a sterilizable stereo-lithic model. These essential tools are crucial for the upcoming surgery.
6. The surgeon receives the cutting guides, reconstruction plate, and any additional tools needed for the procedure in advance. This ensures they have everything required to execute the surgical plan effectively.
7. Alongside the physical tools, the surgeon also receives a detailed report outlining the surgical plan, providing valuable insights and guidance throughout the procedure.
8. This streamlined process enhances surgical precision and efficiency, ultimately benefiting patient outcomes and ensuring that the surgical team is well-prepared for a successful operation.

VII. INTRA-OPERATIVELY

1. A titanium PSI (Patient-Specific Implant) was positioned precisely at the intended location of the defect during the surgical procedure.
2. **The implant was securely fixed by attaching it mesially to both the bilateral infraorbital rim** and the bilateral body of the zygoma, ensuring stability and alignment.
3. Following the implant placement, the surgical site underwent thorough irrigation with a combination of 10% betadine solution and normal saline. This step helped maintain aseptic conditions and minimize the risk of infection.

4. To close the surgical site, 3-0 vicryl sutures were used for primary closure, ensuring proper wound sealing and tissue approximation. Additionally, 2-0 vicryl sutures were employed for specific closure requirements.
5. This surgical procedure aimed to provide both structural support and aesthetic restoration, and these steps played a critical role in achieving a successful outcome

VIII. POST OPERATIVE RESULT

1. Good aesthetic results as fullness at the right anterior region could be appreciated.
2. No oro- antral communication seen after 4 weeks follow up.
3. Patient is on regular follow ups since **3 months**.

IX. INDICATION

Indications for Patient-Specific Implants (PSIs) in oral and maxillofacial surgery:

1. Simultaneous reconstruction with dental implants is required.
2. Facial bone continuity defect limited to hard tissue.
3. Mild or moderate bone defects due to prior excessive bone preparation, such as facial osteoplasty.
4. High aesthetic requirements, including correction of fine skeletal asymmetry.
5. Defects in functional load-bearing areas, like the mandible.
6. Aesthetic indications, addressing volume loss often seen in aging faces leading to contour irregularities.
7. Congenital facial syndromes associated with challenging skeletal deficiencies and facial deformities.
8. Complex posttraumatic maxillofacial defects, where PSIs can facilitate reconstruction.
9. Patients with severe facial trauma, often accompanied by life-threatening injuries, necessitating delayed facial reconstruction until deemed medically stable.
10. Emphasizing the importance of timely reconstruction, as delayed intervention can compromise the overall reconstructive outcomes.
11. Ongoing follow-up to assess aesthetic results and ensure the absence of oro-antral communication.
12. Regular follow-ups to monitor patient progress and maintain optimal outcomes.

These indications highlight the versatile applications of PSIs in addressing a range of facial bone defects and deformities, from cosmetic enhancements to complex reconstructive procedures, ultimately improving both aesthetics and functionality while ensuring patient safety and satisfaction.

X. CONTRAINDICATION

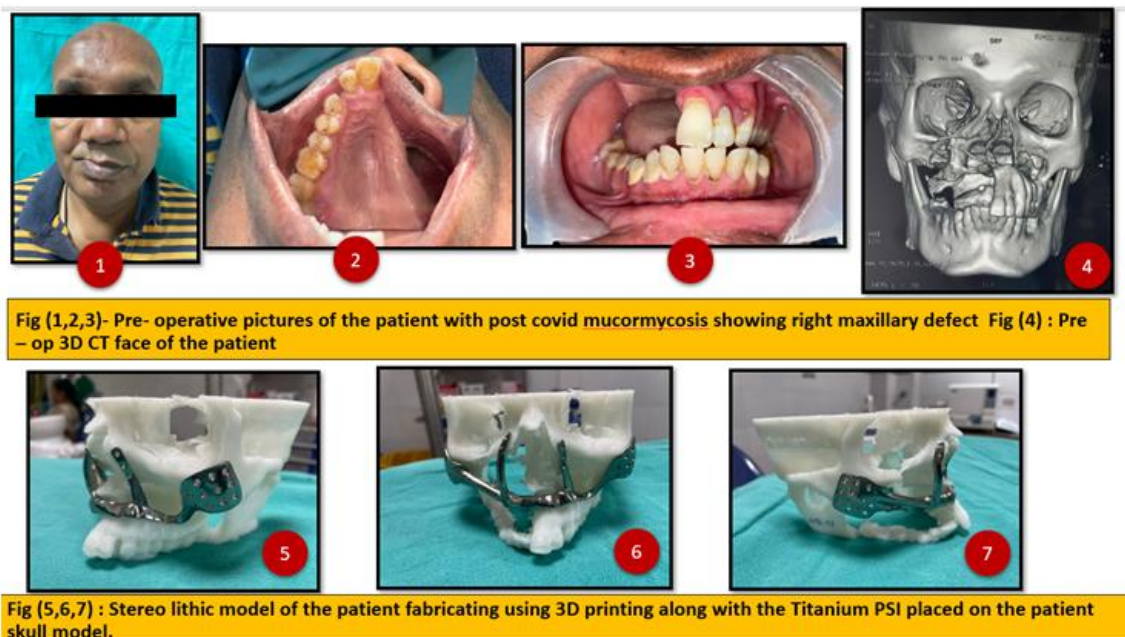
1. Cases necessitating intricate reconstruction of both hard and soft tissues.
2. Individuals exhibiting heightened sensitivity or allergies to titanium materials.
3. Patients who mandate ongoing monitoring through radiographic scans like CT or MRI, where the potential for artifacts to interfere with image quality exists.

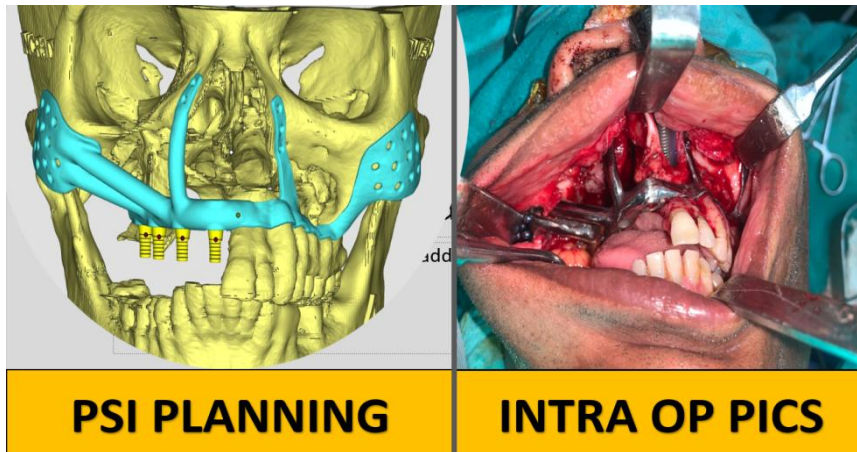
XI. FUTURE IN PSIs

Titanium 3D Patient-Specific Implants (PSIs) herald a promising future for patients facing oral and craniomaxillofacial defects. PSI deployment in reconstructing these complex anatomical regions offers an accurate alternative to off-the-shelf implants. The automated nature of PSI production allows for safe, time-efficient procedures, eliminating the need for specialized, software-specific expertise.

Reconstructing intricate maxillofacial defects presents challenges, demanding precise replacement of absent or deficient tissue for favourable outcomes. Suboptimal results often arise when manually crafting autologous grafts or adapting generic implants. To enhance the probability of achieving desired contours, implants must be tailored to individual reconstructive requirements.

Continual advancements in Computer-Aided Design and Computer-Aided Manufacturing (CAD/CAM) technologies facilitate swift custom implant design and fabrication, bringing us closer to realizing the ideal patient-specific implant. In the post-COVID era, the utilization of Titanium-based 3D PSIs represents an innovative solution. This approach not only addresses the physical aspects of facial deformities but also safeguards the patient's dignity and self-confidence, ensuring that these challenges do not leave a lasting emotional scar.





PSI PLANNING

INTRA OP PICS

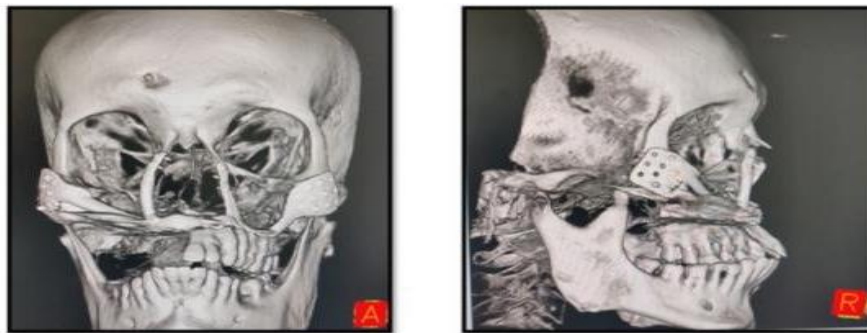
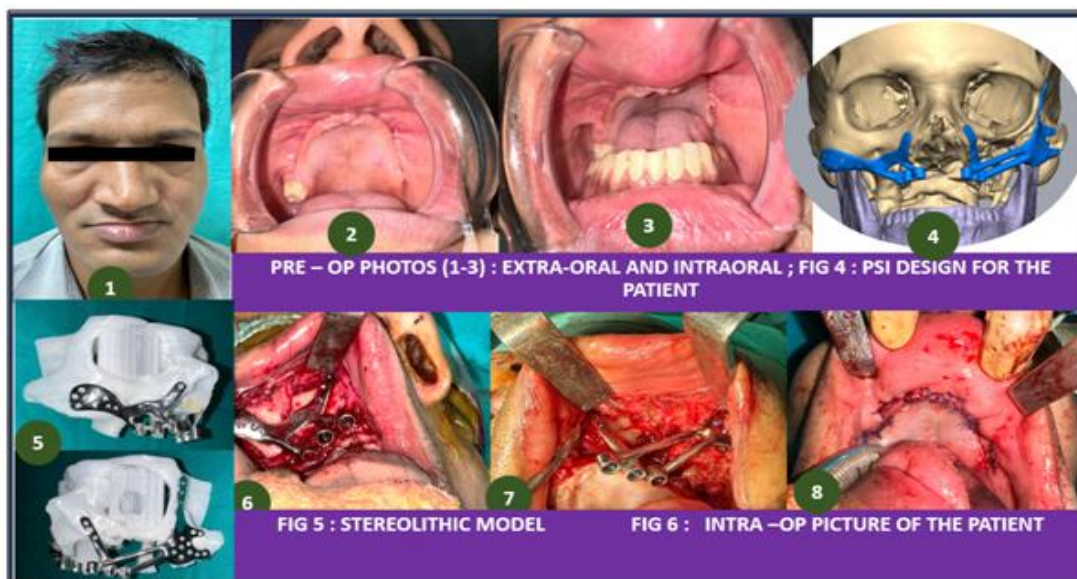
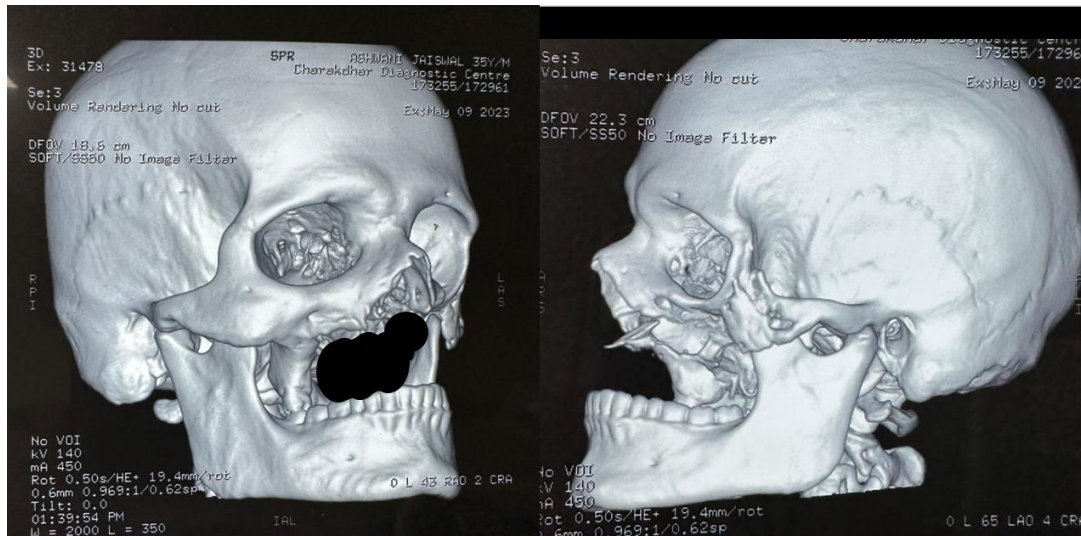
Fig (A,R) : Post operative CBCT of the patient after 2 months follow up



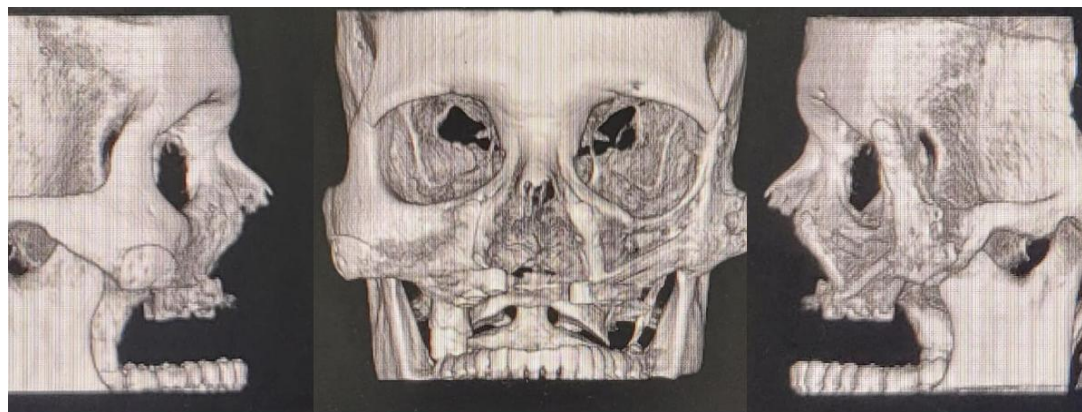
PRE - OP PHOTOS (1-3) : EXTRA-ORAL AND INTRAORAL ; FIG 4 : PSI DESIGN FOR THE PATIENT

FIG 5 : STEREO LITHIC MODEL

FIG 6 : INTRA -OP PICTURE OF THE PATIENT



PRE-OP 3D CT



POST-OP 3D CT

REFERENCES

- [1] The Use of Patient-Specific Implants in Oral and Maxillofacial Surgery Michael F. Huang, DDS, MD David Alfi, DDS, MD Jonathan Alfi, MA Andrew T. Huang, MD Published: August 31, 2019 DOI: <https://doi.org/10.1016/j.coms.2019.07.0104>
- [2] Rehabilitation of a rhinocerebral mucormycosis patient Dhiman, Col Rakesh; Arora, Bring Vimal*; Kotwal, L The Journal of Indian Prosthodontic Society 7(2):p 88-91, April-June 2007. | DOI: 10.4103/0972-4052.34003
- [3] A Novel Method to Rehabilitate Post-mucormycosis Maxillectomy Defect by Using Patient-Specific Zygoma Implant Nehal Patel, Anshul Mel, Pooja Patel, Ansari Fakhruddin & Saloni Gupta Journal of Maxillofacial and Oral Surgery volume 22, pages 118-123 (2023)
- [4] Digital planning and individual implants for secondary reconstruction of midfacial deformities: A pilot study Paris Liokatis MD, DDS1| Yoana Malenova DDS1| Florian-Nepomuk Fegg MD, DDS1| Selgai Haidari MD, DDS1| Monika Probst MD2| Marko Boskov MD, DDS1| Carl-Peter Cornelius MD, DDS1| Matthias Troeltzsch MD, DDS1| Florian-Andreas Probst MD, DDS

- [5] Prosthetic rehabilitation of untailed defects using patient-specific implants Sudheer Kondaka,¹ Vankudoth Dal Singh,² Chakradhar Vadlamudi,¹ and Lakshmana Rao Bathala
- [6] Update of patient-specific maxillofacial implant Owusu, James A. *Current Opinion in Otolaryngology & Head and Neck Surgery* 23(4):p 261-264, August 2015. | DOI: 10.1097/MOO.000000000000017
- [7] Zhao L, Patel PK, Cohen M. Application of virtual surgical planning with computer assisted design and manufacturing technology to cranio-maxillofacial surgery. *Arch Plast Surg* 2012; 39:309–316.
- [8] Binder WJ. Custom-designed facial implants. *Facial Plast Surg Clin North Am* 2008; 16:133–146.vii.
- [9] Abdoli A, Falahi S, Kenarkoohi A. COVID-19-associated opportunistic infections: A snapshot on the current reports. *Clin Exp Med.* 2021;23:1–20.
- [10] Vosselman N, Alberga J, Witjes MH, Raghoobar GM, Reintsema H, Vissink A, et al. Prosthodontic rehabilitation of head and neck cancer patients-challenges and new developments. *Oral Dis.* 2021;27:64–72.