

ESSENTIALS ON GUIDED BONE REGENERATION (GBR)

Abstract

Guided Bone Regeneration, a recent therapeutic advancement for regaining the lost bone structure for further implant placement. Various authors during the last three decades have used barrier membranes for creating space for regeneration. This procedure is based on the principle of that of Guided Tissue Regeneration. For successful results of this therapy, two main components are necessary: barrier membranes (for creating space) and bone graft materials which act as core for bone formation. In the course of time, these components have been advanced for better results. The procedure of Guided Bone Regeneration, initiates with an incision and is followed by the placement of membrane and graft. Procedural complications as well as post-operative complications need to be avoided which is possible by following the prescribed technique. This technique has been proved to be a successful way to regenerate the resorbed bone and hence leading to successful implant placement.

Authors

Dr. Ashida S Blesson
Post-Graduate Student
Department of Periodontology
Rungta College of Dental Sciences
Bhilai, Chhattisgarh, India.

I. INTRODUCTION

Guided bone regeneration (GBR), is one of the advancing modalities for correcting bony defects and aims to achieve bone regeneration (Dahlin et al. 1988). GBR is a surgical procedure that involves the placement of barrier membranes with or without bone grafts and/or bone substitutes.¹ Major function of barrier membrane includes: providing stability to the bone graft, preventing the overlying soft tissue from collapsing into the defect, preventing competing non-osteogenic cell from migrating into the site, and accumulating growth factors.

Although the concept was initially proposed for the regeneration of tissues associated with the periodontium, the proof of principle was soon applied to regenerate edentulous alveolar ridges.

Osseous regeneration by GBR has been governed by the migration of pluripotent and osteogenic cells (e.g. osteoblasts derived from the periosteum and adjacent bone and bone marrow) to the bone defect site and exclusion of cells impeding bone formation (e.g. epithelial cells and fibroblasts).²

II. HISTORICAL BACKGROUND

Berg proposed in 1947 that bone grafts may raise the paraspinal muscles from decorticated laminae, allowing granulation tissue to grow in the empty area. This would increase the likelihood and speed of osteosynthesis in the spine. Shortly after, Hellstadius put Berg's idea to the test by raising muscles from the cortex of a rabbit's femur that had been roughened up using stainless steel cups and rings. He came to the conclusion that if the soft components were kept apart, bone would not grow in granulation tissue. In 1959, Hurley et al first described the principle of placing membrane between a bone defect and the surrounding soft tissues, (later termed as Guided bone regeneration).³

Barrier membranes were initially evaluated in the 1950s and 1960s for osseous face reconstruction by Nyman, et al. by Bassett, et al. and Boyne, et al.⁴

GTR was first developed in the early 1980s by Nyman et al.⁵

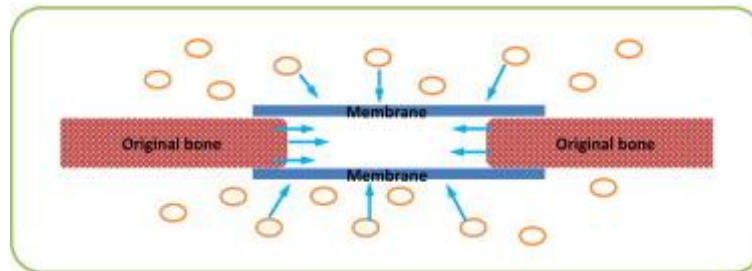
Murray first pronounced the procedure of placing barrier membranes for regeneration of lost bone in reduced alveolar width. Nyman and Gottlow introduced the term guided bone regeneration (GBR) in the 1980s as a result of GTRs. Occlusive barriers were used in periodontal healing studies to prevent the migration of cells from gingival connective tissue and epithelium to the periodontal defect, which can obstruct tissue regeneration.⁶

Early research on GBR was led by Dahlin and colleagues in an effort to address the challenging issue of reconstructing significant osseous abnormalities in the jaws and for the treatment of the atrophic maxilla or mandible.⁷

III. PRINCIPLES OF GUIDED BONE REGENERATION

1. Basic Principle: The goal of GTR is to prevent connective tissue from coming into contact with the root surface by sandwiching a membrane between the flap and root surface. By selectively inducing cells from the periodontal membrane on the root surface,

periodontal tissue is then renewed. Melcher created the idea of directed tissue regeneration for the first time in 1970.⁸



Source: Rakhmatia et al. Principle of Guided Bone Regeneration. 2013. 57.10.1016/j.jpor.2012.12.001.

2. **Biological Principle:** Wang et al. in 2006 described 4 major biologic principles (i.e., PASS) necessary for predictable bone regeneration:

- **Primary Closure:** True healing through primary aim is frequently challenging to accomplish. But primary wound closure, which establishes an environment that is unaffected/unaltered by external bacterial or mechanical damage, is a crucial surgical paradigm for GBR.
- **Angiogenesis:** According to the GBR's guiding principles, the addition of bone grafting materials and membranes facilitates osteogenesis by potentially releasing bone morphogenetic proteins. A blood clot forms during the first 24 hours, is cleared by neutrophils and macrophages, and is followed by the beginning of granulation tissue production over the next days and weeks. De novo bone growth and newly generated blood vessels have a close link.⁹ Blood vessels, which are abundant in the granulation tissue, play a crucial role in the creation of osteoid and the subsequent mineralization of the tissue to form woven bone.¹⁰ The role of the blood clot in the repair of bone deformities was also emphasised by Melcher and Dryer.¹¹
- **Space Creation/Maintenance:** One of the guiding principles of GBR is to provide sufficient room for bone regeneration. To ensure the growth of bone-forming cells while keeping out undesirable epithelium and connective tissue cells, space is required. By avoiding membrane collapse brought on by pressure from tissues above, reinforced membranes help maintain space.
- **Stability:** A barrier membrane serves two purposes: it keeps out undesirable cells and stabilises the blood clot.¹² In order for a wound to heal, early clot attachment and wound stabilisation are crucial. Interleukin-1, Interleukin-8, and tumour necrosis factor are only a few of the cytokines, growth factors, and signalling molecules that are abundant in the early blood clot and help to draw healing cells to the wound site. Particularly for neutrophils and monocytes, platelet-derived growth factor is a powerful mitogen and chemoattractant.¹³

The barrier membrane placement should result in:

- **Cell Exclusion:** The barrier membrane is employed in GBR to prevent gingival fibroblasts and/or epithelial cells from entering the wound and producing fibrous connective tissue.
- **Tenting:** A technique in which the membrane is carefully fitted and applied so that a space beneath the membrane is established, entirely isolating the defect to be regenerated from the overlying soft tissue. It is critical that the membrane be cut so that it extends 2 to 3 mm beyond the defect edges in all directions. The membrane's corners should also be rounded to prevent accidental flap perforation.
- **Scaffolding:** This tented space is first occupied by a fibrin clot, which acts as a scaffold for progenitor cell in-growth. The cells in GBR will come from neighbouring bone or bone marrow.
- **Stabilization:** During healing, the membrane must also protect the clot from being disturbed by movement of the underlying flap. As a result, sutures, small bone screws, or bone tacks are frequently, but not always, used to secure it in place. At times, the edges of the membrane are merely tucked beneath the flap margins during closing, giving stability.
- **Framework:** The membrane must be stabilized to prevent collapse where essential, such as in non-space maintaining defects such as dehiscence or fenestrations.¹⁴

IV. INDICATIONS FOR GBR

1. Deficiencies in the local alveolar ridge (horizontal or vertical).
2. Osseous filling of the immediate implant
3. Implant-related dehiscence and fenestration.
4. Bone abnormalities caused by dropping implants.
5. Remaining bone lesions
6. To help in the healing of perforations in the sinus membrane

1. **Grafting Materials:** GBR is a surgical procedure that uses barrier membranes with or without particulate bone grafts or/and bone substitutes.

Classification of Barrier Membranes: Membranes utilised for periodontal regeneration are primarily characterised according on their ability to be resorbed:

- Expanded nonresorbable e-PTFE (polytetrafluoroethylene) Gore-Tex d-PTFE (high density poly tetrafluoroethylene) Titanium mesh PTFE reinforced with titanium
- Polymeric (vicryl, atrisor, Epiguide) and collagen-derived resorbable materials.¹⁵ directed bone regeneration membranes:¹⁶

The first generation of barrier membranes developed in the 60s and 70s aimed to achieve a suitable combination of physical properties to match those of the replaced tissue with a minimal toxic response in the host.

The second generation of barrier membranes was designed to be resorbable to avoid the need for surgical removal. There are two broad categories of bioresorbable membranes: the natural and the synthetic membranes.

Table1: Table Source Zhao R. Bone Grafts and Substitutes in Dentistry. 2021. doi: 10.3390/molecules26103007.

Natural bone graft and substitute materials.			
Material Type	Forms Available	Material Source	Examples of clinically used bone grafts
Cortical Allograft	Fresh, frozen, freeze-dried Whole bone segments, block, pieces	Mineralized cortical allograft	MinerOss Cortical™
Cancellous Allograft	Fresh, frozen, freeze-dried Chips, wedges, pegs, powder	Mineralized cancellous allograft	MinerOss Cancellous™
Demineralised Bone Matrix	Putty, moldable pastes, blocks, particulates, powder	Human DBM	Dynagraft D Putty™ Opteform™ Grafton DBM™
Deproteinised bovine bone	Block, granules, particulates	Bovine	BioOss™ OsteoGraf™ Cerabone™
Algae-based	Granules	Red algae	Algipore™
Coral-based	Block, Granules	Marine coral	ProOsteon™ BioCoral™ InterPore™
Synthetic bone grafting materials			
Material Type	Forms Available	Examples of clinically used bone grafts	
Hydroxyapatite	Blocks, wedges and granules	Ostim™ Endobon™	
Tricalcium phosphate ceramics	Blocks, cylinders, wedges, granules	Cerasorb™ OSferion™ Orthograft™	
Biphasic calcium phosphate ceramics	Moldable putty, granules	MASTERGRAFT™	

Bioglasses	Particulates	Perioglas TM Biogran TM
Calcium phosphate cements	Injectable paste, moldable putty	Norian TM ChronOS inject TM Hydroset TM BoneSource TM
Calcium sulfates	Various sizes pellets	OsteoSet TM
Polymers	Particulates, granules, ready to use in syringe	Bioplant HTR Synthetic Bone TM
Metals	Mesh/membrane available in lateral and papilla design forms	OSS Builder TM
Composites	Putty, granulate, block, ready to use “QD”	NanoBone TM (nanocrystalline HA/silicon dioxide)
	Paste	Fortoss Vital TM (_ -TCP/calcium sulphate)
	Blocks, microchips, plate, granules, wedge, cylinder, rod	SmartBone TM (DBM/polymer/collagen)

2. Surgical Procedure

Step 1: The flap is designed in accordance with the following five principles.

- a. Access to the bone defect
- b. Maintenance of the blood supply of the elevated flap and the neighboring tissues
- c. Preserving the interdental papilla
- d. Providing sufficient advancement of the flap
- e. Allowing for tension-free primary closure

A full-thickness midcrestal incision is made between the teeth preserving the interdental papilla. Two full-thickness vertical incisions are made down to the bone on either side, starting in the area of the base of the vestibule and continuing coronally in one continuous cut to meet the crestal incision.

Step 2: Recipient site preparation

The bony defect is debrided of granulation tissue and tissue tags, using curettes and back-action chisels. Cortical perforations (decortications) are then made with a #1 or #2 round bur using high speed with copious irrigation to create bleeding at the surgical site. The decortications are designed to increase the blood supply and osteogenic progenitor cell migration from the bone marrow to the site of augmentation.¹⁷

Step 3: Releasing incisions

Periosteal releasing incisions are made with a sharp 15 C blade on the inner apical portion of the flap, creating a 2-3 mm split-thickness dissection.

Step 4: Graft materials and membrane placement

Step 5: Stabilization of graft material and barrier membrane

Step 6: Suturing to advance the flap coronally

Step 7: Suturing to ensure primary closure

Final tissue adaptation is achieved by means of multiple interrupted regularly spaced to close the incisions.

Complications associated with GBR

Postoperative complications occurring after periodontal surgery can be categorized as following

- **General Complications arising after Periodontal Surgery:**
 - Bleeding
 - Swelling
 - Postoperative pain
 - Root hypersensitivity
 - Increased tooth mobility
 - Delayed wound healing
 - Trismus
 - Postoperative bacteremia
 - Taste changes
 - Bruising

- **Complications arising due to the Surgical Procedure Employed**
 - Local anaesthesia related
 - Flap related
 - Graft related
 - GTR related
 - Suture related
 - Periodontal pack related¹⁸

Complications that are specifically related to GBR are mentioned below:
Complication classification associated with non-resorbable membrane.
Complications can be classified as either healing (Class I to IV) or surgical (A to C).

- **Healing Complications:**

- Class I: Small membrane exposure (≤ 3 mm) without purulent exudate
- Class II: Large membrane exposure (> 3 mm) without purulent exudate
- Class III: Membrane exposure with purulent exudate
- Class IV: Abscess formation without membrane exposure

- **Surgical Complications:**

- A: Flap damage
- B: Neurologic complications
- C: Vascular complications

V. CONCLUSION

It can be concluded that GBR can predictably lead to regeneration of critical size maxillofacial defects and to de novo bone formation via a synchronised progression of events recapitulating intramembranous ossification. The available preclinical and clinical evidence suggests that GBR constitutes a successful therapeutic approach for the treatment of peri-implant bone defects and for the preservation of the dimensions and the configuration of the alveolar socket following tooth extraction. Preclinical and clinical trials investigating the physiology and pathophysiology of the healing process following GBR application at the molecular level are warranted, with a view to develop and implement novel therapeutic strategies, e.g. tissue engineering, drug delivery and/ or gene therapy aiming to promote the bone formation and regeneration potential following GBR treatment.

REFERENCES

- [1] Dahlin C, Linde A, Gottlow J, Nyman S. Healing of bone defects by guided tissue regeneration. *Plast Reconstr Surg* 1988; 81(5): 672-6.
- [2] Healing of bone defects by guided tissue regeneration. Dahlin C, Linde A, Gottlow J, Nyman S *Plast Reconstr Surg*. 1988 May; 81(5):672-6.
- [3] Hurley, La, Stinchfield, F. E., Bassett, A. L., Lyon, W. H. The role of soft tissues in osteogenesis. An experimental study of canine spine fusions. *J. Bone joint surg. Am.* 1959. 41, 1243-1254
- [4] Bassett CAL, Creighton DK and Stinchfield FE (1961). Contributions of endosteum, cortex and soft tissues to osteogenesis. *Surg Gynecol Obstet* 112: 145.
- [5] Nyman S, Karring T, Lindhe J, Planten S. Healing following implantation of periodontitis-affected roots into gingival connective tissue. *J Clin Periodontol* 1980; 7(5): 394-401
- [6] Dahlin C, Gottlow J, Linde A, Nyman S. Healing of maxillary and mandibular bone defects using a membrane technique. An experimental study in monkeys. *Scand J Plast Reconstr Surg Hand Surg* 1990; 24(1): 13-9.
- [7] Dahlin, C., Sennerby, L., Lekholm, U., Linde, A. et al., Generation of new bone around titanium implants using a membrane technique: an experimental study in rabbits. *Int. J. Oral Maxillofac. Implants* 1989, 4, 19-25.
- [8] Caffesse G, Becker W. Principles and techniques of guided tissue regeneration. *Dent clin of N Am* 1991; 35(3): 479-93.
- [9] Schmid J, Wallkamm B, Hämmerle CH, Gogolewski S, Lang NP. The significance of angiogenesis in guided bone regeneration. A case report of a rabbit experiment. *Clin Oral Implants Res.* 1997 Jun; 8(3): 244-8. doi: 10.1034/j.1600-0501.1997.080311.x.

- [10] Melcher AH, Dryer CJ. Protection of the blood clot in healing of circumscribed bone defects. *J Bone Joint Surg.* 1962;44B:424-429.
- [11] Kostopoulos L, Karring T, Uraguchi R. Formation of jawbone tuberosities by guided tissue regeneration. An experimental study in the rat. *Clin Oral Implants Res.* 1994;5:245-253.
- [12] Weng D, Hurzeler MB, Quinones CR, et al. Contribution of the periosteum to bone formation in guided bone regeneration. A study in monkeys. *Clin Oral Implants Res.* 2000;11:546-554
- [13] Schenk RK, Buser D, Hardwick WR , et al. Healing pattern of bone regeneration in membrane-protected defects: a histologic study in the canine mandible. *Int J Oral Maxillofac Impl.* 1994;9:13–29.
- [14] Winet H. The role of microvasculature in normal and perturbed bone healing as revealed by intravital microscopy. *Bone.* 1996;19:39S-57S.
- [15] Bartold M, Gronthos S, Haynes D, Ivanovski S. Mesenchymal stem cells and biologic factors leading to bone formation. *J Clin Periodontol.* 2019 Jun;46 Suppl 21:12-32.
- [16] Wang HL, MacNeil RL. Guided tissue regeneration. Absorbable barriers. *Dent Clin North Am.* 1998;42(3):505–22.
- [17] Stuart J. Froum, Sang-Choon Cho, Leon Pariente. A surgical protocol for guided bone regeneration procedures using absorbable membranes to minimize and treat complications. *Dental Learning* 2012;6:3-13.
- [18] Zerr KJ, Furnary AP, Grunkemeir GL, et al: Glucose control lowers the risk of wound infections in diabetics after open heart operations. *Ann Thorac Surg* 1997;63:356–361.