

TALIPES EQUINOVARUS

Abstract

At least two out of every thousand live births are affected by the uncommon but frequent lower limb developmental disease known as idiopathic congenital talipes equinovarus. It involves abnormalities in the forefoot, midfoot, and hindfoot regions of the foot. The aetiology of this condition proposed to neurological, muscular, bony, connective tissue, vascular, genetical and idiopathic mechanism. The basic concept of this deformity appears and associated with the intra-uterine posture. According to complex segregation analysis, a single major effect gene acting against a polygenic background is the most likely inheritance pattern. Research indicates that in most cases, the clubfoot can be identified as early as the second trimester, far before any uterine pressure is applied to the developing embryo. A unifying factor across all developmental aspects may be disruption of the fetal foot's medial rotation process as a whole. There are probably multiple distinct causes, and in certain instances, the phenotype might emerge from the threshold effect of multiple factors working in tandem. The involvement is bilateral in about 50% of cases and in unilateral cases right is more common than left side. Male population are more commonly involved than the female. Clubfoot has four deformity components: equines, midfoot cavus, forefoot adduction and hindfoot varus. These are associated with hypoplasia of the skin, muscles, tendons, bones, ligaments, and neurovascular bundles on the medial side of the foot, and they have both cosmetic and functional implications. The afflicted foot is typically smaller than the healthy foot. The severity of the deformity is assessed by various methods like Pirani scoring, Ponseti and Smoley classification

Authors

Mrs. Priyadarsini Monalisha Dash
Demonstrator P&O
SVNIRTAR
Olatpur, Cuttack, Odisha, India.

Mrs. Sarita Sahoo
Demonstrator P&O
SVNIRTAR
Olatpur, Cuttack, Odisha, India

system, Harrold and Walker classification system etc. In the rehabilitation procedure conservative treatment with ponsetti method is well accepted and has been reported result in good correction ranging from 50-90%. Conservative treatment includes mother manipulation, serial manipulation and various orthosis are used to correct the deformity. Proper treatment protocols should be strictly followed to avoid recurrence of the deformity. Surgical treatment is indicated only after failure of conservative treatment.

The most typical foot condition talipes equinovarus. The prevalence rate is 1.2 times 1000 births. Males affected rate is more than females. These are Latin words for ankle and foot are talips and pes respectively. That implies that the issue only affects the ankle and foot. According to its original definition, this abnormality is "causes the patient to walk on the ankle"⁽¹⁾. There are two categories for Talipes Equino Varus (TEV): postural/primary TEV and structural/secondary TEV⁽²⁾. One's posture is primarily seen in their peer group, which can be evaluated after birth.

I. PRIMARY CLUBFOOT

Congenital deformities are those that exist from birth, while acquired deformities might develop as a result of any other problem or an injury. Any type of clubfoot has meaning when it is congenital. Its name comes from the club-like appearance of severe, untreated talipes equinovarus. Many different kinds of foot abnormalities are related to this issue.(fig-1)

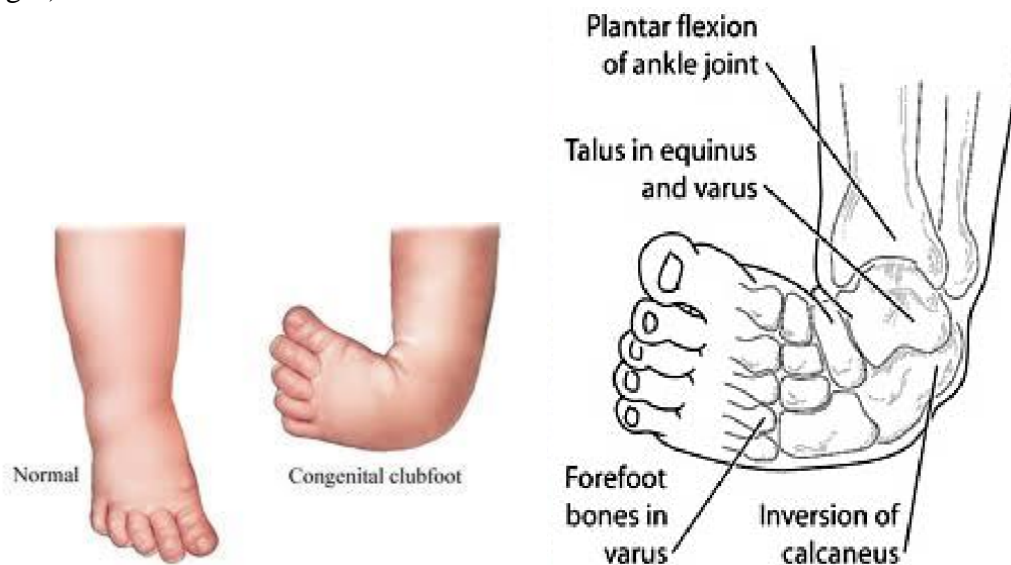


Figure 1: Normal Foot and the CTEV Foot

- 1. CTEV:** The posture that is displayed from birth is this one. It is a frequent birth defect that affects roughly 1:1000 live births. Bilateral clubfoot occurs mostly about 50% of cases. Males experience this 2:1 more frequently than females do. There are three joints in the foot that are affected by abnormalities to varied degrees⁽³⁾.
- 2. Etiology:** There is little understood about the biomechanics and pathophysiology of CTEV. At 12 weeks of gestation, the fetus develops this malformation(fig-2). At this time, the foot gradually unfolds after passing through a number of physiological equines. The conditions of clubfoot have been the subject of some theories.
 - **Foetal Developmental Arrest In The Fibula Phase:** Bohm postulated that the cause of the clubfoot was an arrest in embryonic development⁽¹¹⁾.
 - **Postural Theory:** it is also called extrinsic compression theory and is highly disputable⁽¹²⁾.

- **Neuromuscular Theory:** it put forward by Ponseti and Uthoff and states that a pathological process affects some muscles and is associated with the appearance of fibrotic sheaths⁽¹³⁾.
- **Malformation Theory:** it holds that the talus is abnormal, especially its neck and head. This deformity becomes a focus of retraction⁽¹⁴⁾.

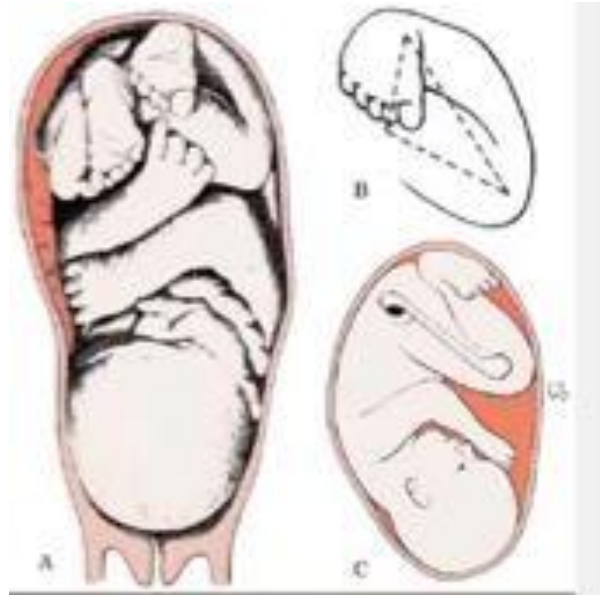


Figure 2: Gestation Age

3. Clinical Features of CTEV (can Be Seen In Naked Eye)(fig-3)

- Equinus of ankle.
- Varus of hindfoot.
- Adduction of midfoot.
- Cavus of midfoot (excessive arching at the mid-tarsal joints)
- Adduction and inversion of midfoot and forefoot.
- 60% cases are Bilaterally involved.
- In unilateral cases, Size of the foot are smaller than normal.
- Size of the heel is small in size.
- Presence of Deep skin creases on the posterior side of the heel and on the medial side of the sole.
- Inner side of the foot resembles shape of concave.

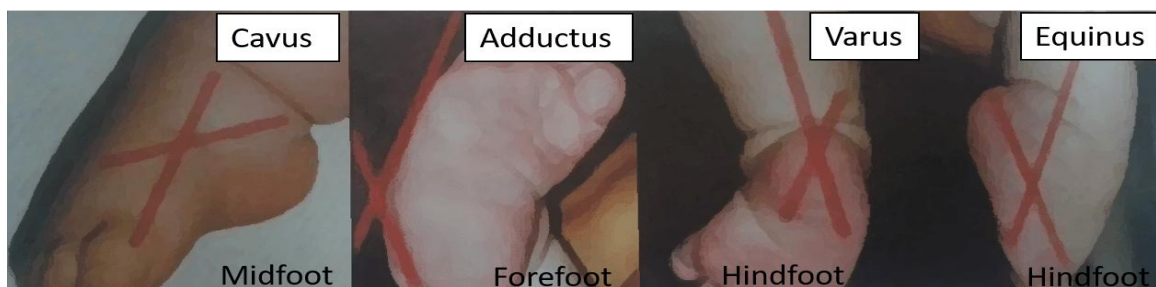

Figure 3: Clinical Features of CTEV

4. Radiological Features of CTEV: (fig.4): Plain and stress X-rays are both used to detect deformities, but the stress radiograph reveals the clubfoot deformity that is fixed. The fibula was visible superimposed on the tibia in the lateral view (X-ray) with maximum dorsiflexion of the foot. Breaching of the cubometatarsal or calcaneocuboid joints indicates erroneous foot alignment with a rocker bottom. This image also reveals the angle created by the tibiotalar and the talocalcaneal angle are useful in determining the degree of equinus and varus, respectively. CTEV has a smaller talocalcaneal angle than typical (25–50°)(fig-5). The angular relationship of the calcaneocuboid joint, the presence or absence of bifurcation between the calcaneum and the talus bone, the angles produced between the longitudinal axis of the talus and the calcaneus are all visible on A-P Xray taken with the foot maintained in eversion position. The forefoot adduction angle and the talometatarsal angle can both be determined using this information. Angles of 0° to negative 5° are typical in CTEV. The Talocalcaneal Index, or p in CTEV, should be at least 40°, which is equal to (AP view of TC angle+ lateral view of TC angle). The degree of varus can be determined by analyzing the talocalcaneal angle on the radiographs. X-ray skeletal anomalies were followed.

- Subtalar Joint: Inversion
- Talonavicular Joint : Adduction
- Ankle Joint: Equinus
- Internal Rotation of Tibia.
- Inverted Calcaneum

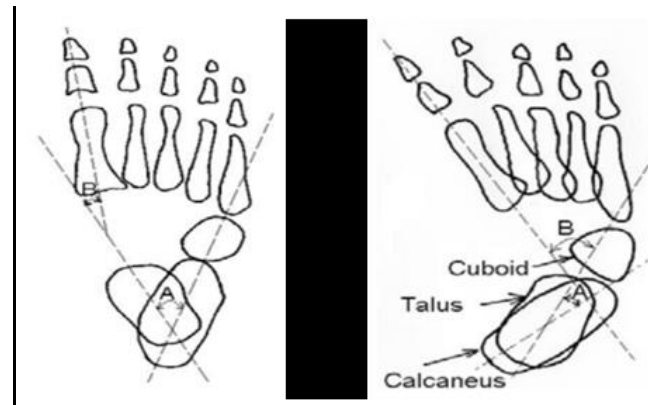


Figure 4: Radiographical View of Normal Foot and CTEV Foot

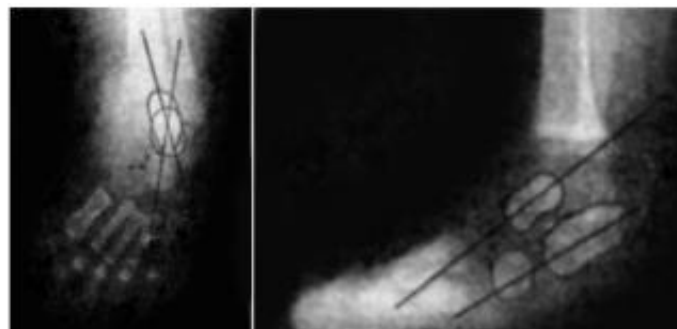


Figure 5: Radiographical View of Talocalcaneal Angle both Normal and CTEV.

5. Clinical Assessments: (for the Examiner by Palpation)⁽¹⁷⁾

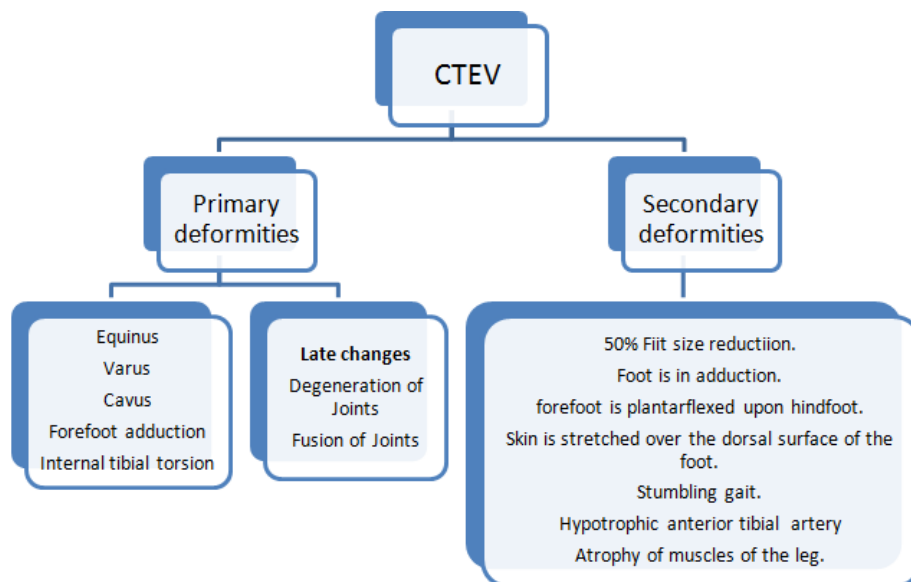
The examiner must carefully follow five key processes when examining a CTEV:

- To feel the heel to determine if the calcaneus is present or absent;
- To determine whether convex or straight lateral border;
- To assess the foot's reduction in all directions:
 - forefoot adduction and rotation of the calcaneotarsal complex in the transverse plane;
 - ankle dorsiflexion in sagittal plane
 - rear foot varus in frontal plane.
- To assess the muscle tone. It is challenging to measure the motor strength of a newborn's muscles. Even though it is challenging to do, a muscle test should be done because it is crucial to rule out neuromuscular non-idiopathic clubfoot. Muscle quality and activity are key indicators of how quickly a deformity progresses.
- To Check the other joints. It is necessary to inspect the hips, knees, elbows, and shoulders to rule out subluxation, dislocation, or deformity.

6. Types of CTEV (Etiology)

- **Idiopathic:** it is the most prevalent variety. The diagnosis is quite easy to make and understand. There are five common main abnormalities, and as a result, secondary deformities appear.
- **Untreated Clubfoot:** All clubfeet from birth to age two that have received little to no treatment or none at all can be categorized as untreated clubfeet.
- **Treated Clubfoot:** "Treated clubfeet" refers to untreated clubfeet that have undergone Ponseti correction. Clubfeet that have been treated are often braced at night till the age of 4 or 5 and full-time for 3 months.
- **Recurrent Clubfoot:** This clubfoot received successful Ponseti treatment, but the deformity has now returned. The most frequent cause is because braces were removed too soon.
- **Neglected Clubfoot:** The term "neglected clubfoot" refers to a clubfoot that is not treated or with little therapy and the age is more than 2 year. The untreated clubfoot may improve with Ponseti therapy, but it could possibly have a bone deformity that needs to be corrected surgically.
- **Complex Clubfoot** - Because of additional pathology or scarring from surgery, any foot with a deformity that has undergone several types of treatment plan rather than the Ponseti procedure may have more difficulty. The clubfoot complex is made up of several basic and secondary abnormalities. (flowchart-1)

- **Resistant Clubfoot:** This clubfoot has had the proper Ponseti treatment, but there hasn't been a noticeable change. It is frequently discovered that this particular variety of clubfoot is secondary or syndromic in nature rather than really idiopathic.
- **Atypical Clubfoot:** This particular type of clubfoot is covered in the course's advanced section. It involves a foot that is frequently swollen, has an elongated big toe, and a first metatarsal that is plantarflexed. Although it can happen on its own, cast slippage is the main cause.
- Osseous type Clubfoot is sometime associated with lack of tibia and fibula.
- Muscular CTEV because of Arthrogryposis multiplex congenital(AGMC) or sometimes multiple congenital contractures.
- Neuropathic CTEV due to spina bifida or any other neuro problem.

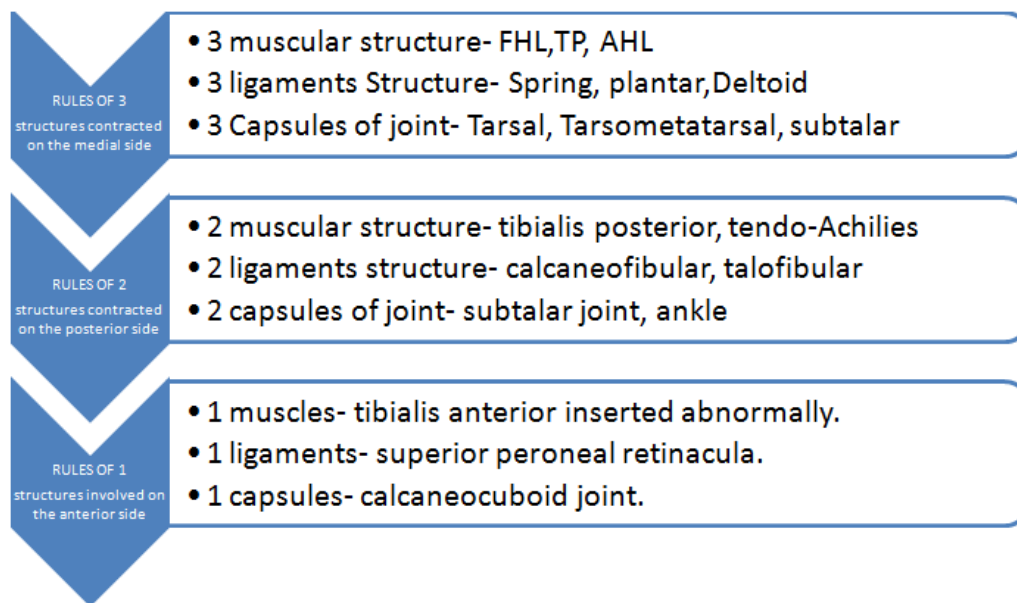


Flowchart 1: (Deformities of the CTEV)

7. Bones and Joints (bony) Changes in CTEV:

BONES & JOINTS	CHANGES
Calcaneus	Varus
Talus	Displaced medially and downward.
Navicular	Rotated & Medially displaced
Cuboid	Displaced medially and articulates with the calcaneus (Known as locked cuboid).
Metatarsals	From tarsometatarsal joints Deviates medially
Talocalcaneal articulation	Dislocation of the articulation on the talus and calcaneum.
Tibia	Usually shows medially rotated, rarely lateral rotated..

8. Soft Tissue Changes in CTEV:



II. SECONDARY CLUBFOOT

On the other side, secondary clubfoot happens when another illness or ailment is the root cause of or connected to the emergence of clubfoot. Such disorders are typically neurological, like Spina Bifida, which is linked to concurrent sensory and/or motor deficits, or syndromic, like Arthrogryposis, which is linked to more extensive findings and involvement of various musculoskeletal conditions.

1. Biomechanics of Clubfoot Deformity: The calcaneum, cuboid, and navicular bone segments are displaced medially and discovered to be inverted with respect to the talus, which is a characteristic of clubfoot. It originates from a medial displacement of the navicular and an irregular connection between talus and the os calcis(12). The results of the clubfoot investigation demonstrate that head and neck of the talus is positioned medially and downwardly is the primary aberration. It is also said that the skeletal deformity was a contributing factor in the abnormalities of the leg & foot muscles, tendons & ligaments. The talus in every case of clubfoot has significant flexion(9), a smaller body, and an abnormal shape when compared to a normal shape of the talus. Under the talus, the calcaneus is medially deviated and inverted. Its body is always somewhat medially bent and in severe flexion. Anterior to calcaneus, the cuboid is inverted and displaced medially and navicular bone is substantially displaced medially, flattened evenly, or wedge-shaped laterally. The middle joints vary different sizes, but the distal joint is relatively narrow or nonexistent in the cuneiform and metatarsals(10). The triceps surae muscles, tibialis posterior, flexor hallucis longus (FHL) & flexor digitorum longus (FDL) are present in the clubfoot, and the fibers in these muscles are reduced in size. The tibialis posterior tendon is big and elongated downward to the insertion point, whereas the extensor digitorum longus, tibialis anterior and extensor hallucis longus tendons are all substantially medially displaced in the ankle. The locking of the hindfoot in varus and equines is mostly dependent on the posterior tibialis muscle and achilles tendon(12). In every clubfoot anterior section of the deltoid ligament and the plantar

calcaneonavicular ligament are short and thick, the medial talocalcaneal ligament is noticeably enlarged. Along with being thick and short, the fibulotalar, posterior tibiotalar, and fibulocalcaneal ligaments are frequently matted together with an abundance of fibrous tissue. Clubfoot supination is caused by the cuboid, navicular & calcaneum held in inversion and adduction position. The skeletal elements of the forefoot are adducted in front of the medially displaced cuboid, navicular and cavus is caused by the first metatarsal flexing more than the fifth metatarsals. The talus-dependent column and the calcaneus-dependent column are the two columns that make up the foot. The equilibrium between these two columns is reestablished by restoring correct divergence between the talus and the calcaneum(15). The medial column tends to develop more slowly than the lateral column during clubfoot growth, which results in the kidney-shaped deformity.

2. Diagnostic test for CTEV:

- **Dorsiflexion Test:** An infant's foot can be dorsiflexed until its dorsal surface touches the tibia's anterior surface. As a screening test, CTEV can be performed to rule out this possibility.(fig-6)

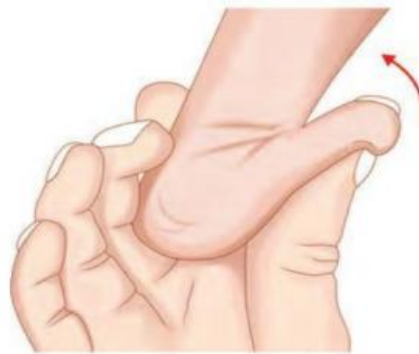

Figure 6: Dorsiflexion Test of CTEV

- **Plumb Line Test:** This examination aids in identifying torsional position of tibia. The youngster is forced to sit at a table as both lower limbs hang over the side. When extended downward, a line drawn from the patella's center to the tubercle of the tibia should generally cut the foot at the first or second intermetatarsal gap. The plumb line is what it is called. When the tibia rotates medially during CTEV, the fourth or fifth intermetatarsal gap is cut, and when the tibia rotates laterally, the opposite occurs.(fig-7)

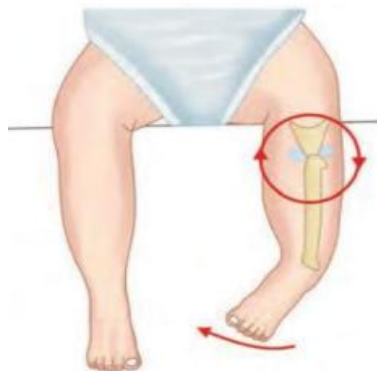

Figure 7: Plumb Line Test

- **Scratch Test:** This is performed to detect muscle imbalance in a child.
 - **Medial Scratch Test:** in general, when the medial sole is scratched, the foot everts. This tests the peroneals.
 - **Lateral Scratch Test:** when the lateral sole is scratched, the child inverts the foot. This tests the invertors.
- **Thigh-Foot Angle:** In CTEV, Internal Tibial Torsion & in toeing gait is a common. Diagnosis is made clinically with a thigh-foot angle > 10 degrees.(fig-8)

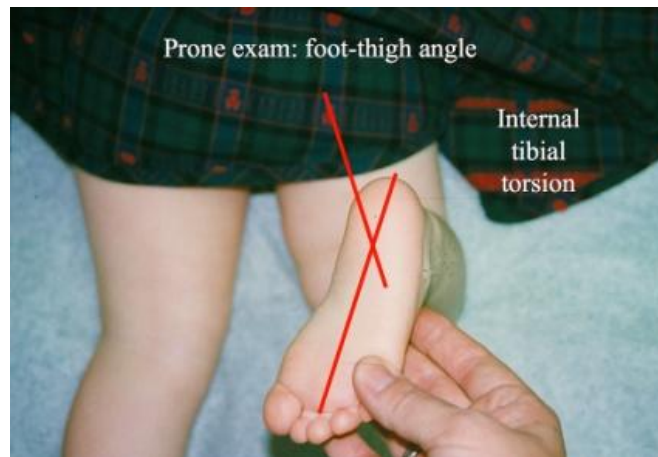


Figure 8: Thigh-foot Angle.

III.ACQUIRED TALIPES EQUINOVARUS

Such a defect does not exist at birth. This deformity originates with the patient due to some acquired condition.

Features of ATEV:

- Acquired
- Causes might polio, cerebral palsy, etc.
- Unilateral involvement.
- Tropical changes seen in the skin, muscles are flaccid or spastic.
- Transverse crease is absent.
- Thinner skeletal structure.

Outcome Measures in Clubfoot⁽¹⁶⁾:

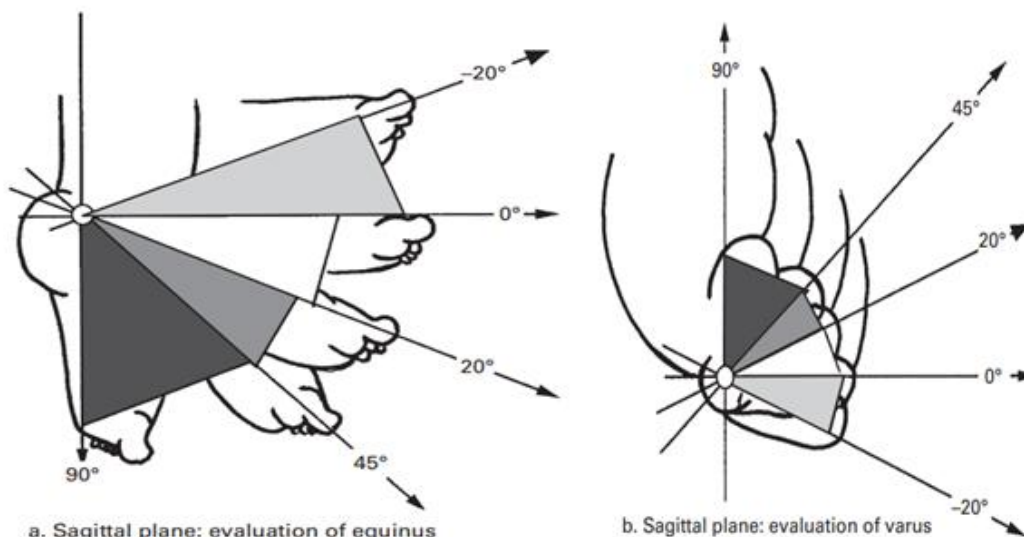
Despite the wealth of information on clubfoot, it appears that there is no approved method for assessing how well a treatment is working. Clubfoot treatment "results" in the examiner's eyes may be characterized by muscle strength, range of motion, standing alignment of various foot segments, conclusions from gait analysis and/or radiographic parameters on weight-bearing images,. According to the patient, cure may include their ability to wear certain types of shoes, their level of discomfort or endurance, how others perceive their feet, and their ability to engage in certain activities. While in other situations it could be expected that treatment will lead to a normal foot, in some situations minor alignment issues or cosmesis may be better as function is normal. Severity of the deformity and the degree of

progress following the application of various treatment methods are assessed using the systems listed below.

1. Ponseti and Smoley Classification System ⁽⁵⁾: Ankle dorsiflexion, forefoot supination, heel varus, and tibial torsion served as the foundation of their classification system. These measurements were used to categorize feet as good, acceptable, or terrible. This is the most widely used and only relies on 10 separate physical examination findings, each of which is given a score of 0 to 10 according to severity from normal to severe abnormality. There are no radiographic requirements for this categorization. The 10 physical characteristics of Pirani are as follows:

- Lateral curvature presence in the foot.
- medial crease Severly affect.
- Severity of the posterior crease.
- Medial malleol or navicular interval.
- Head of the talus palpated laterally.
- Absence of heel bone.
- Fibula Achilles interval.
- Equines Rigidity
- Adductus Rigidity
- Contracture of Long flexor

2. Pirani Scoring ⁽⁴⁾: The assessment and treatment of clubfoot can be assessed and tracked using the Pirani Score, which is an easy-to-use and trustworthy tool. The many foot images used in this scoring system make it easier to see problems with the supporting soft tissue and skeletal structure. Without using any special tools, a foot can be evaluated in under a minute. (fig-9a,b,c,d)



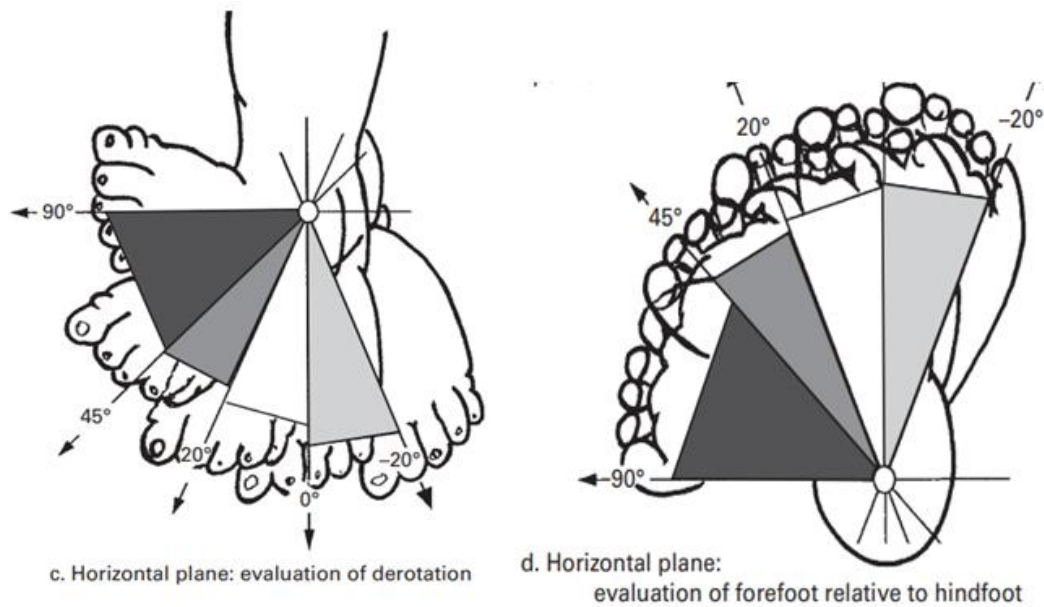


Figure 9: Different Position of Pirani Scoring.

3. **3. Harrold and Walker Classification System** ⁽⁶⁾: Foot maintained at or above the 0° (grade 1), foot held in less than 20° (grade-2) or fixed equinus or varus of 20° (grade 3), determined the degree of deformity.
4. **Catterall Classification System** ⁽⁷⁾: According to the onset of deformity, it was divided into four patterns: resolving; produced by tendon or joint contracture; or consequent to mistaken repair.
5. **Diméglio Classification System** ⁽⁸⁾: It is comes from a thorough scoring system that takes into account the measurement of four parameters and evaluates them according to how easily they can be reduced using gentle manipulation and measurement with a goniometer:
 - sagittal plane shows equinus
 - frontal plane present with varus
 - ‘derotation’ around the talus of the calcaneoforefoot area, horizontal plane.
 - forefoot adduction with respect to the hindfoot in the horizontal plane.

Four extra points are awarded for the existence of medial creases, a posterior crease, a cavus, and insufficient calf muscle. Based on the score, which can have a maximum of 20 points, the deformity can be categorized as mild, moderate, severe, or extremely severe.

6. **International Clubfoot Study Group (ICFSG) Classification System:** In order to compare the malformations before and after surgery, this system score was applied.

These above mentioned outcome measures are used as gold standard in the evaluation of CTEV status.

Summary of the Outcome Measures for CTEV

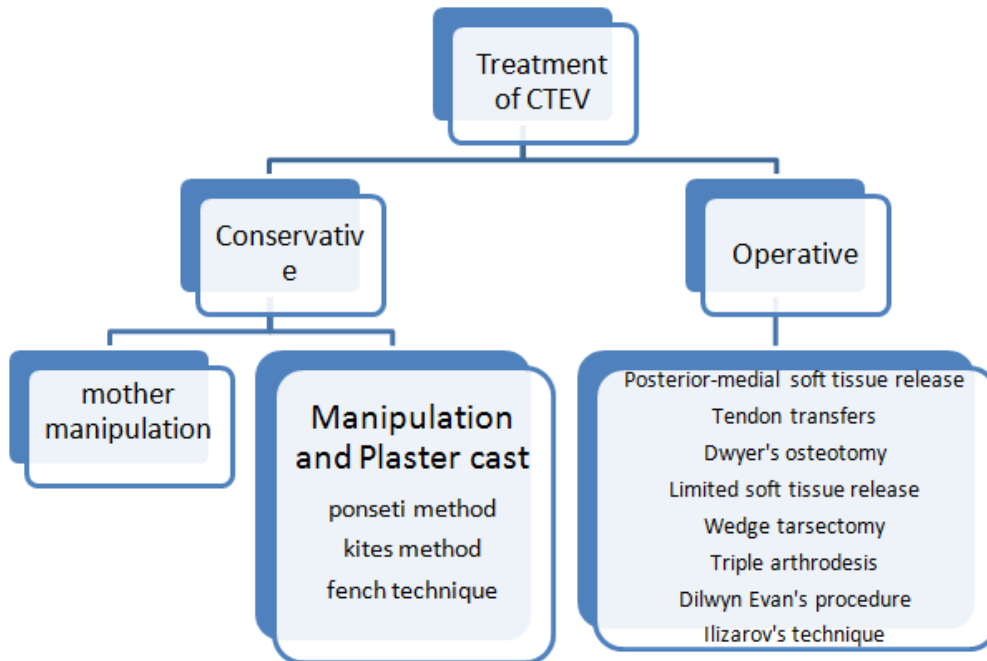
Measure	Components	Scoring scale
Pirani Score (1999)	Hindfoot scoring 3 components Midfoot scoring 3 components	Each item 0, 0.5, 1 Total score 0–6
Dimeglio Score (1995)	Four main items: <ul style="list-style-type: none"> • pes Equinus • pes Varus • Rotation of the calcaneopedal block • Adduction of forefoot with respect to hindfoot • Four bonus scores: contractures, posterior crease, cavus, medial crease. 	Each item 0–4 Total score 0–20
Dimeglio/Bensahel Final Evaluation of Clubfoot	Evaluation <ul style="list-style-type: none"> •Dorsi/plantar flexion, supination/pronation • Muscle function (flexors, triceps, dorsiflexors, peroneus) Morphology • Hind foot (varus / valgus, equinus) • Fore foot (supination, adduction) medial rotation, pes cavus • Eight radiographical view on AP and lateral 	total scoring -0 to 50
Gait analysis	Kinematics (joint angles) Pedobarography Electromyography Kinetics (moments)	NA
Radiographic parameters	AP talocalcaneal angle <ul style="list-style-type: none"> • Lateral tibiotalar angle • Lateral talocalcaneal angle • AP talo-first metatarsal angle 	NA
Roye (2001)	10 points to assess the outcomes as per overall satisfaction, pain, appearance, and physical limitations	
Pirani/Bohm/Sinclair (PBS) (2019) ³⁴	Seven item scoring system: <ul style="list-style-type: none"> • Child standing (hindfoot varus and supination) • Child sitting (passive and active ankle dorsiflexion, and 	Total scoring from 7–18

	subtalar abduction) •Child walking (swing phase supination and early heel rise)	
The International Clubfoot Study Group (ICFSG) score (2003)	A list of points assessing: Morphology Radiology Function	Total scoring from 0–60
Ezra score (2000)	Ankle dorsiflexion • Heel position • Supination • Subtalar motion • Forefoot appearance • Cavus • Gait • Functional limitations • Shoe type • Pain • Patient satisfaction • TA tendon function	Total score 150
The Institution of Motion Analysis and Research (IMAR) Clubfoot Scale	Three sections: • Questionnaire (function, symptoms) • Examination (appearance of the foot) • Gait data (static and dynamic pedobarography, temporospatial data)	Scores are deducted for each abnormality from an initial score of 100
Assessing Clubfoot Treatment Tool (ACT) (2017)	Three questions: • Can your child wear shoes of your/their choice? • Does your child complain of pain in their affected foot? • How satisfied are you with your child’s foot?	Scores 0–3

IV. MANAGEMENT OF CTEV (FLOWCHART-2)

Getting and keeping the foot in the plantigrade position is the aim of CTEV management.⁽¹⁸⁾ Surgery, casting, taping, and manipulation are used to achieve active correction. With the use of orthosis, such as splints, braces, and shoes, passive maintenance is accomplished.⁽¹⁹⁾

Depending on the age of the infant and the degree of the deformity, management of CTEV might begin as soon as the diagnosis. External fixators, surgery, and other conservative management strategies are available.⁽¹⁾



Flowchart 2: Summary of Management System for CTEV

1. Conservative Management:

- **Manipulation Alone:** It is crucial to teach a new mother how to manipulate her baby's foot correctly while it is being fed. Applying enough pressure to the Foot causes it to be everted and dorsiflexed for roughly 5 seconds. This procedure should be performed multiple times for up to 5 minutes. In most cases, mother manipulation is insufficient to correct a significant malformation.⁽²⁰⁾
- **Manipulation and Cast Immobilization:** The surgeon will serially manipulate the foot before immobilizing it with a plaster cast in the proper position. The International Clubfoot Study Group, founded in 2003, has endorsed the following procedures as the globally accepted conservative systems for the clubfoot treatment.⁽²¹⁾
 - The Kite's Technique is used shortly after birth. Based on the three-point pressure theory, the forefoot adduction and heel inversion are corrected sequentially, then the equine deformity, with the fulcrum remaining at the calcaneocuboid joint (administered by the thumb). Every week, a plaster cast below the knee is put and changed. This process is continued until the foot achieves overcorrection, at which point a maintenance tool (Dennis Brown splint) is applied.^(20,21,22)
 - **Ponsetti's Treatment:** Ignacio Ponseti created this treatment, which is based on a thorough study of the pathoanatomy of CTEV and involves internally rotating (adducting) the calcaneo-cuboid-navicular complex under the plantarflexed talus. Tight structures must therefore be stretched, the talar head must be pressured

rather than the calcaneo-cuboid joint (Kite's technique), and the complex must be brought back beneath the talus. When collagen is subjected to a steady load, it can elongate due to its viscoelasticity feature. He stretched and manipulated by casting using this property.⁽²⁵⁾

- Within a week of the baby's birth, the treatment is begun. Three phases make up the course of treatment: casting and manipulation, tenotomy, and bracing.

The Following Order is Used To Rectify The Deformities:

- Correction of cavus foot (first two)
- Adduction (third cast): Abduction upto 70 degrees
- Varus of heel
- Equinus

Following each manipulation is an above-the-knee PoP cast that is switched out every week. In just six weeks, all aspects of the abnormalities are fixed. Treatment for the remaining equinus deformity involves a straightforward percutaneous Achilles tenotomy, followed by three weeks of wearing an above-knee cast with the knee bent 90 degrees. A Denis-Browne splint helps stop the deformity from relapsing.^(20,21,23,24)

Depending on the initial severity, club foot has a propensity to relapse, with the probability of recurrence directly proportionate to the severity. As the disease that causes clubfoot disappears at age four, clubfoot might recur. Regardless of the level of correction attained following casting, Ponsetti observed that 50% of the relapses happened between 10 months and five years. Foot Abduction Orthosis (FAO) discontinuance is the cause of recurrence, and compliance with the FAO by the patient would lower the recurrence rate to 10%.^(18,21)

2. French Technique: This technique is also known as Functional method, introduced by Masse and Bensahel.

- Daily manipulation of 30 min by the physical therapist.
- To maintain the stimulated reduction of the muscles around the foot, especially peroneal muscles.
- Application of adhesive strapping .
- The procedure was continued for two months .
- Reduced to three sessions per week for six months.
- Taping was continued until the patient was ambulatory.
- A night-time splint was introduced and used for two to three years.

Initially, 50% of the patients have shown good result and remaining cases required surgery was only a posterior release. This procedure involves daily hospital visits, and was costly which was subsequently modified to include placement in a continuous passive motion (CPM) machine for six to eight hours after passive manipulation by the physical therapist and adhesive strapping of the feet. Surgical.⁽²¹⁾

3. Orthotic Treatment: Foot Abduction Brace/Orthosis (FAO)

Bracing is applied immediately after Tenotomy(after the last cast is removed). The most common cause of relapse is noncompliance to bracing protocol. Few of the FAOs are as follows:

- Dennis Browne splint (DB SPLINT) consists of Dennis-Browne bar attached to shoes.

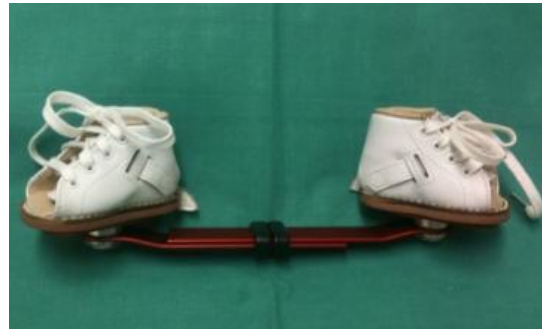

Figure 10: D-B Splint.

- **Design:**
 - Shoes are made up of leather, straight-last open-toe, and with lace-closures.
 - Deep heel cup- to prevents the heel from moving upwards and provide a normal shape.
 - Medial or posterior peep hole- allows parents to see if the heel is placed in its position.
 - The bar that connects both the shoes is equal length with shoulder or pelvis width.
 - Shoe out angle (Abduction angle): the angle between the longitudinal axis of the shoe and the imaginary perpendicular line to the bar in transverse plane.
Unilateral cases 70° for corrected clubfoot and 30°-40° for normal foot
Bilateral cases 70° for both of the corrected clubfeet.
 - Shoe up angle (dorsiflexion angle): The angle between the sole of the shoe and the bar in the coronal plane and it should be 10 degrees for both the corrected clubfoot (Bilateral cases) and the normal foot (unilateral cases). This holds the foot in dorsiflexion.
 - Disadvantage of this brace is there may develop excessive heel valgus and external tibial torsion while using the brace. To avoid that the abduction angle can be reduced from 70 degrees to 40 degrees.
Wearing protocol:
 - After the last cast is removed, **full-time bracing** (day and night) for **23 hours** a day for **three months**
 - Until the child attains **3 to 4 years** old, the brace has to applied for **12 hours at night** and 2 to 4 hours in the middle of the day, for a total of 14 to 16 hours every 24-hour period.
Bracing follow up has to undergo to check fit, regular use and recurrence of deformity. The brace has to be reviewed accordingly.
 - 2 weeks after the start of FAO
 - After 2months

- Every 3 to 6 months upto 4years of age
- Stop the use of splint and relapse of deformity after 6months has to be followed up.

To prevent the relapse of the deformity, the CTEV foot should be held in overcorrected position with bracing. The posteromedial soft tissues are stretched by maintaining it in abduction and extension. The design is such that it will keep the knees free so that the baby can sit and crawl.^(26,27,29)

- 2. H.M. Steenbeek created a brace that may be constructed using basic, readily available components. The brace is affordable, simple to make, excellent at maintaining correction, and well-suited for general use (Fig-11).

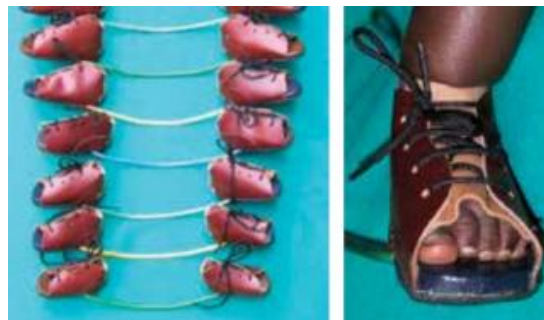

Figure 11: Steenbeek SPLINT

- John Mitchell brace consists of shoes and a plastic sole that is molded to the shape of the child's foot, comfortable and easy to use (Fig-12).



Figure 12: John Mitchell Brace

- Dr. Matthew Dobbs -a new dynamic brace for clubfoot which allows the foot to move while maintaining rotation of the foot. An ankle-foot orthoses can be a part of this brace to prevent ankle plantar flexion (Fig-13).



Figure 13: Matthew Dobb Splint

- Dr. Jeffrey Kessler (Fig-14) The bar is made of polypropylene. The brace may improve compliance because it is well accepted by the infant. The shoes, made of malleable plastic. The shoes are fixed to the bar with screws.



Figure 14: Jeffrey Splint

V. SHOE MODIFICATIONS FOR CTEV

1. **Flexible Equinovarus:** Apart from night time use, it is advise to use these footwear modified shoes in the day time.
 - Outflare last Shoes to abduct the forefoot: may be worn day and night with rigid DB Splint for non-ambulatory corrections (Fig15a).
 - To evert midfoot once the forefoot has been corrected: long medial counter and reverse orthopaedic heel (Fig15b).
 - To evert hindfoot: lateral heel and sole wedge, lateral heel and sole flare
 - To reduce plantarflexion: lower or remove the external heel and elevate the forefoot.
2. **Fixed Equinovarus:** Medial heel and sole wedge along with heel elevation to accommodate the deformity (Fig 15c).⁽²⁸⁾



Figure 15a: Outflare last Shoes




Figure 15b: Reverse orthopaedic heel



Figure 15c: Accommodative Footwear

3. Ankle Foot Orthosis for CTEV (Fig-16a,b): Ankle Foot Orthosis (AFO) plays an important role to correct all the deformity of the clubfoot by providing passive stretching for the tight soft tissues. It can be used both day and night time. It is necessary to prevent growth-related relapses, as well as stable weight-bearing. It is a safe and effective device in maintaining correction of clubfoot. AFO is made at plantigrade position having following modifications:

- Medial Straight Border for correction of forefoot adduction.
- Hole at posterior aspect of Heel.
- Instep strap for correction of equines.
- Absence of medial longitudinal arch support.
- Midfoot corrective strap for correction of varus and cavus and it provides medial and downward directed force system to correct the deformity.
- Ankle can be positioned in slight dorsiflexion.⁽³¹⁾



Figure 16a: AFO (Dynamic)

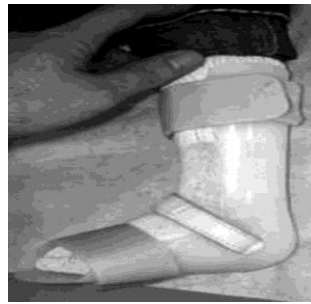


Figure 16b: AFO (Static)

The force systems acting to check equines and varus of foot⁽³¹⁾ (Fig-16c,d)

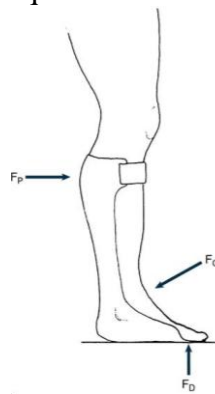


Figure 16c: Control of Equines

F_p - at posterior calf band, F_D - at Metatarsal Heads, F_C - Force around Ankle

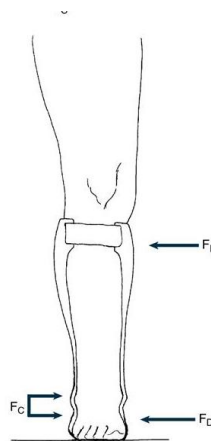


Figure 16d: Control Of Varus

F_p - Proximal Force at medial aspect of the calf band, F_D - Distal Force at distal medial wall of orthosis against first metatarsal, F_C - Distal lateral tibia and calcaneus

- 4. Single Medial Bar or Double bar AFO with Ankle Free Motion/ Phelps Brace (Fig-17a,b):** This is used when the deformity can be corrected both conservative and surgical management. A pair of medial straight border shoe with lateral T-strap are used with this AFO for the correction of components.

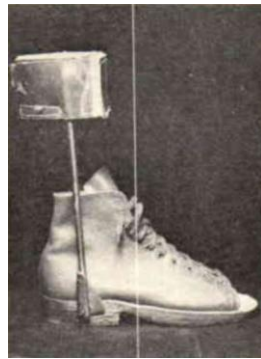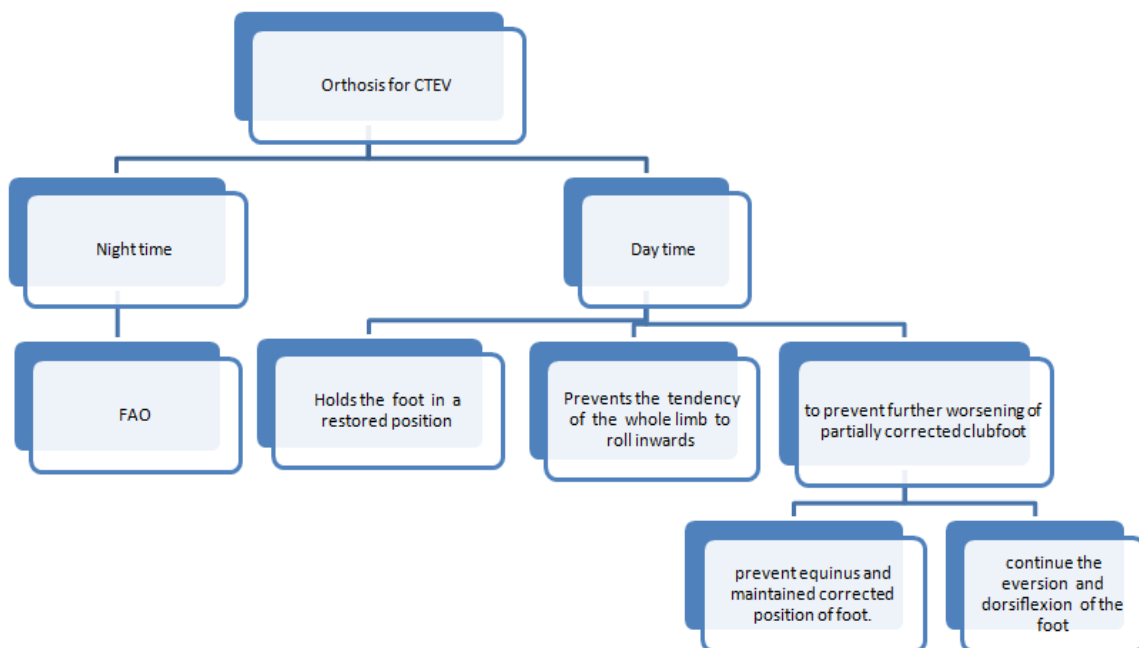


Figure 17a: Phelps Brace



Figure 17b: Double Bar AFO with varus T-Strap.

VI. CATERGORIES OF ORTHOSIS FOR CTEV⁽³⁰⁾



Flowchart 3: Categories of Orthosis for CTEV

1. Operative Management: Operative treatment is necessary for more severe abnormalities that cannot be repaired by conservative measures or for those that reoccur. Operations to release soft tissue adequate in younger kids (those under the age of 3 years), but older patients require bone surgeries. The following actions are carried out:

- **Posterior-Medial Soft Tissue Release (PMSTR)(Fig-18):** In this procedure the taut structures (ligaments, tendons, capsules, etc.) on the medial and posterior sides of the foot is released. An further bone surgery is necessary for older kids.⁽²⁰⁾

- **Released Soft Tissue are:**

Side	Structure
Posterior side of the foot	Z-plasty done to lengthen the tendoachilles tendon. ankle and subtalar joints Posterior capsules Posteriortalo-fibular and calcaneofibular ligaments.
Medial side of the foot	elongation of 3 tendons, i.e., tibialis posterior, flexor digitorum longus and flexor hallucis longus. Release of 3 ligaments i.e., talo-navicular ligament, superficial part of the deltoid ligament and the spring ligament. In severe cases Release of 3 more structures. i.e: interosseous talocalcaneal ligament, capsules of the naviculocuneiform and cuneiform-first metatarsal joints.
Plantar Side of the foot	Plantar fascia release. short flexors of the toes are Released (flexor digitorum brevis) and abductor hallucis from their origin on the calcaneum

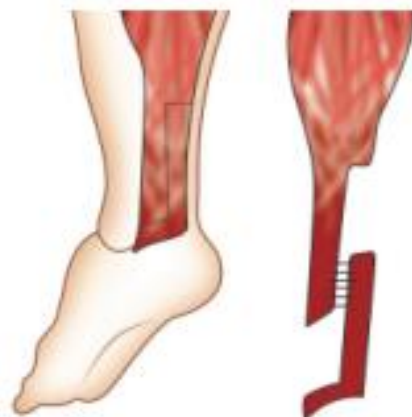

Figure 18: Z-Plasty

2. Limited Soft Tissue Release: in some of the cases only a little bit of soft tissue release with help the patient to be mobile and those are:

- If only equines- posterior soft tissue only
- If adduction- medial soft tissue alone.
- If cavus- plantar soft tissue only.

3. **Tendon Transfers (Fig-19):** sometime inverters(the tibialis anterior and tibialis posterior) are more powerful than evertors (peronei). Transferring the tibialis anterior to the outside of the foot, where it functions as an everter, can alleviate this muscle imbalance. Tendon transfers require a minimum age of five years.⁽¹⁾

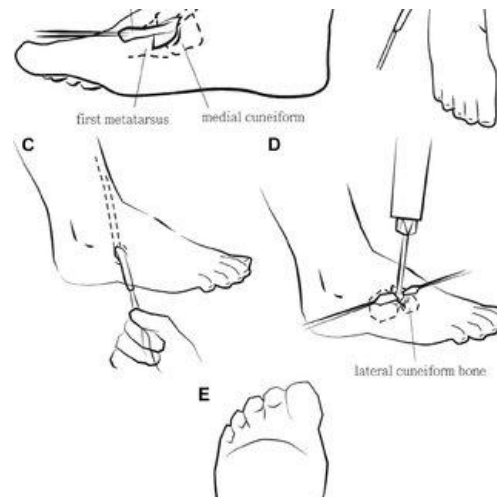


Figure 19: Tendon Transfer.

4. **Dwyer's Osteotomy(Fig-20):** used in correction of the Varus of the heel, open wedge osteotomy is performed at the age of 3 years.

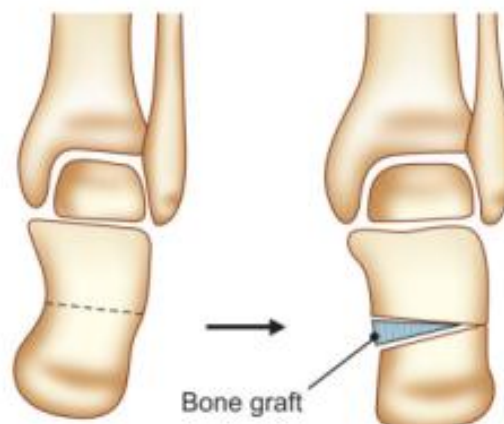


Figure 20: Dwyer's Osteotomy

5. **Dilwyn Evan's Procedure (Fig-21):** this surgery use the technique of both PMSTR and followed by calcaneo-cuboid fusion at the age of 4-8 years.

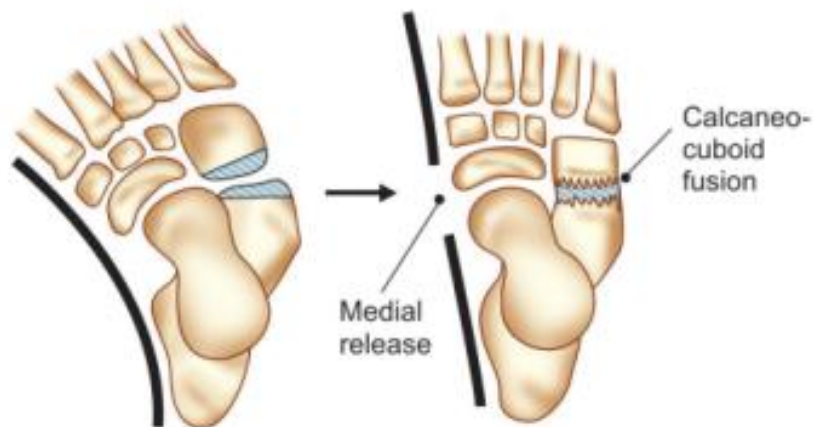


Figure 21:- Dilwyn Evan's Operation

- 6. Wedge Tarsotomy (Fig-22):** This surgery is performed for neglected CTEV between the age group of 8-11 years to correct the cavus and foot adduction basically. In this type wedge of the bone is chopped out dorsal and lateral aspect of the foot to correct the deformity.

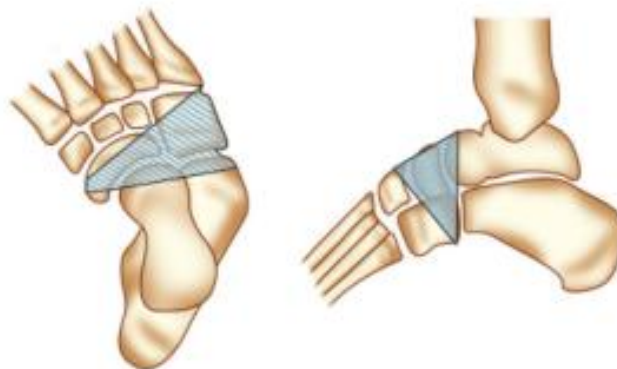


Figure 22: Dorsolateral Wedge Osteotomy

- 7. Triple Arthrodesis (Fig-23):** At the age of 12 years this operation is done to fuse 3 joints of the foot. i.e- subtalar, calcaneo- cuboid and talo-navicular joint.

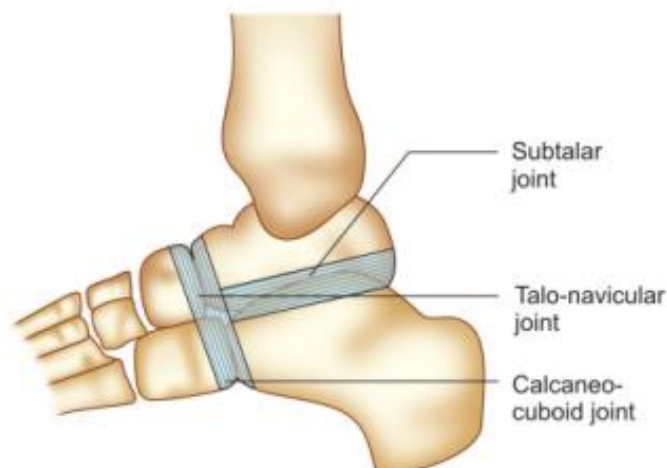


Figure 23: Triple Arthrodesis Operation

- 8. Ilizarov's Technique (Fig-24):** In the neglected CTEV, different components of the skeletal deformity are corrected by gradual stretching by using an external fixator and followed by plaster cast correction is achieved.⁽¹⁾

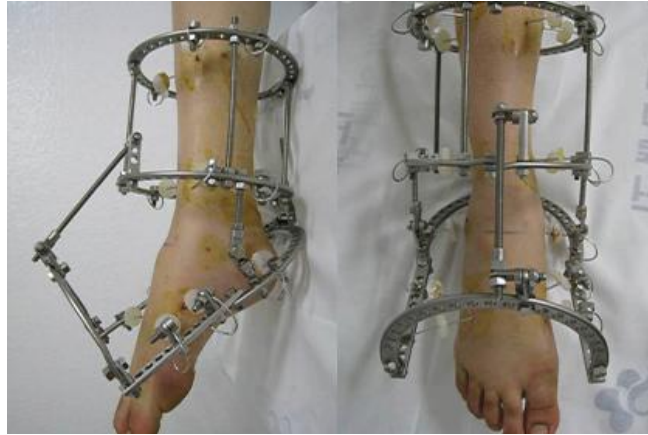

Figure 24: Ilizarov Surgery

Immediately after surgery the foot is provided with an AFO which maintains the foot in required position.

VII. CONCLUSION

CTEV is a complex deformity which is difficult to correct as there are chances of recurrence depending on the severity of the deformity. Several literatures depicted treatment modalities followed by Ponseti provides best results towards the correction of deformities. The main goal of the treatment is to eliminate the four components leading to a pain-free, functional, plantigrade foot, good mobility with better foot alignment. Non-compliance of foot abduction orthoses leads high rate of recurrence. Regular usage and follow up leads to a better prognosis. There are many foot abduction braces available to maintain the correction of foot achieved during Manipulation and Immobilisation. Various static and dynamic orthoses that correct or maintain the equines and deformity after the performance of surgical procedure. Currently many physicians prefer to treat with proper conservative treatment over operative as it is safe and effective.

Abbreviations:

- TEV- talipes equinovarus
- CTEV- congenital talipes equinovarus
- ATEV- Acquired talipes equinovarus
- AHL- Abductor hallucis longus
- TP- Tibialis posterior
- FHL- Flexor hallucis longus.
- TC- Talocalcaneal
- ICFSG- . International Clubfoot Study Group
- FHL - Flexor hallucis longus
- FDL - Flexor digitorum longus
- FAO- Foot Abduction Orthosis

POP- Plaster of Paris
AFO- Ankle Foot Orthosis
CPM- Continuous Passive Motion
PMSTR - Posterior-medial soft tissue release

REFERENCES

- [1] Ebenezar J, John R: Textbook of orthopaedics, Fifth Edition, New Delhi, Jaypee The Health Sciences Publisher, 2017.
- [2] Ranjitha Rebecca Jeevan, E. Vijayaragavanb, Angeline Kiruba: 3D Dimensional Modeling of an Ankle Foot Orthosis for Clubfoot Deformity, International Journal of Biomedical Research, October 2011.
- [3] Robert Rizza, XueCheng Liu, John Thometz, Roger Lyon, and Channing Tassone.: A New Method in the Design of a Dynamic Pedorthosis for Children with Residual Clubfoot, J. Med. Device, June 2010, Volume 4, Issue 2, 021004 (5 pages).
- [4] Andrew M. Wainwright, Tanya Auld, Michael K. Benson, Tim N. Theologis: The classification of congenital talipes equinovarus, The Journal Of Bone And Joint Surgery, Vol. 84-B, No. 7, September 2002.
- [5] Ponseti IV, Smoley EN: Congenital club foot: the results of treatment, J Bone Joint Surg [Am] 1963;45-A:261-344.
- [6] Harrold AJ, Walker CJ: Treatment and prognosis in congenital club foot, J Bone Joint Surg [Br] 1983;65-B:8-11
- [7] Catterall A. A method of assessment of the clubfoot deformity. Clin Orthop 1991;264:48-53.
- [8] Diméglio A, Bensahel H, Souchet P, Mazeau P, Bonnet F: Classification of clubfoot. J Pediatr Orthop B 1995;4:129-36.
- [9] Steven Adler: A 3D M.reverse engineering employing CT for CAD/CAM application. 3D scanning technologies magazine. 2008. vol 1, no.3.
- [10] James N. Athearn, CO, Justina S. Case, CO, John M. Roberts, MD: Impression Techniques and Model Modification of a Custom-Molded Ankle-Foot Orthosis for the Idiopathic Clubfoot. Current problems in orthopaedics: Clubfoot. New York: Churchill Livingstone, 1981:5-6, 85-96.
- [11] Bohm M: the embryologic origin of clubfoot. Journal of bone joint surgery, 1929;11:229.
- [12] Robert H. Fitzgerald, Herbert Kaufer, Arthur L. Malkani, ORTHOPAEDIC, chapter-24, clubfoot.
- [13] Feldbrin Z, Gila AN, Ezra E, muscle imbalance in aetiology of idiopathic club foot: An electromyographic study. J Bone Joint Surg Br 1995;77:596.
- [14] Irani RN, Sherman MS: The pathological anatomy of clubfoot. J Bone Joint Surg Am 1963; 45:45.
- [15] Carroll NC: the pathoanatomy of congenital clubfoot. Orthopaedic clinic north America, 1978; 9:225.
- [16] Soroush Baghdadi¹, Prakash Yadav², Bibek Banskota³, Alaric Aroojis⁴, Divya Talwar⁵, David A Spiegel, Outcome Measures in Clubfoot, Journal of Foot and Ankle Surgery (Asia Pacific), Volume 8 Issue 3 (July–September 2021).
- [17] Federico Canavese and Alain Dimeglio, Clinical examination and classification systems of congenital clubfoot: a narrative review, Ann Transl Med, v.9(13); 2021 Jul.
- [18] Stuart L. Weinstein, Joseph A. Buckwalter: Turek's Orthopaedics, Principles and Their Application, Sixth Edition, Philadelphia, USA, Lipincott Williams & Wilkins, 2005.
- [19] Alvin H. Crawford, Rita Ayyangar, Gregory L. Durrett: Atlas of Orthosis and Assistive Devices, Third Edition, USA, Mosby Inc., ch-32.
- [20] Maheswari J, Vikram A Mhaskar: Essential Orthopaedics, Fifth Edition, New Delhi, Jaypee The Health Sciences Publisher, 2015.
- [21] Ashish A, Debra A Sala: Clubfoot: Etiology and Treatment, Indian J Orthop. 2008 Jan-Mar; 42(1): 22–28.
- [22] Chunho Chen, Ting-Ming Wang, Kuan-Wen Wu, Shier-Chieh Huang, Ken N. Kuo: Comparison of Two Methods For Idiopathic Clubfoot Treatment: A case-controlled study in Taiwan, Journal of the Formosan Medical Association, February 2019, Volume 118, Issue 2, Pages 636-640.
- [23] Md Saif Ullah, Kazi Md Noor-Ul Ferdous, Md Shahjahan, Sk Abu Sayed: Management of Congenital Talipes Equino Varus (CTEV) by Ponseti Casting Technique in Neonates: Our Experience, Journal of Neonatal Surgery, 2013 Apr-Jun; 2(2): 17
- [24] Robert Cady, Theresa A. Hennessey, Richard M. Schwend: Diagnosis and Treatment of Idiopathic Congenital Clubfoot, American Academy of Pediatrics, January 31 2022, Volume 149, Issue 2.

- [25] Vincent S. Mosca ,Clubfoot Pathoanatomy-Biomechanics of Deformity Correction: A Narrative Review, *Annals of Translational Medicine*. 2021 Jul; 9(13): 1096.
- [26] Dr. A. Srinivasa rao, Dr. K. Sudhakar, Dr. B.S. Ravi teja, Dr. Mohammad Gulabi:A Study on Effectiveness of FAB (Foot Abduction Brace) Using Bracing Protocol By Ponseti Technique in Idiopathic Clubfoot Management. *IOSR Journal of Dental and Medical Sciences (IOSR-JDMS)* March. 2022,Volume 21, Issue 3 Ser.2 ,PP 46-53.
- [27] Ponseti et.al:Clubfoot:Ponseti Management ,Third Edition,Lynn Staheli, Global Help,2009.
- [28] van Bosse, Harold J.P., Pontén, Eva, Wada, Akifusa , Agranovich, Olga E,Kowalczyk, Bartłomiej, Lebel, Ehud, Şenaran, Hakan , Derevianko, Denis V.,Vavilov, Maxim A,Petrova, Ekaterina V. , Barsukov, Dmitry B. , Batkin, Sergey , Eylon, Sharon ,Kenis, Vladimir M, Stepanova, Yulia V. ,Buklaev, Dmitry S. ,Yilmaz, Guney, Köse, Oksana ,Trofimova, Svetlana I., Durgut, Fatih :Treatment of the Lower Extremity Contracture/Deformities, *Journal of Pediatric Orthopaedics*, July/August 2017,37():p S16-S23.
- [29] J. A. Janicki,J. G. Wright,S. Weir,U. G. Narayanan: A Comparison of Ankle Foot Orthoses with Foot Abduction Orthoses to Prevent Recurrence Following Correction of Idiopathic Clubfoot By The Ponseti Method, *The Journal Of Bone & Joint Surgery British Volume*, 01 May 2011, Volume 93-B, No. 5, P-700 – 704
- [30] Lajja Desai,Florin Opreescu, Andrew DiMeo,Jose A. Morcuende:Bracing in the treatment of children with clubfoot: past, present, and future, *The Iowa orthopaedic journal*, January 2010, 30:15-23
- [31] Michelle.M.Lusardi,Milagros Jorge,Caroline C Nielsen:Orthotics and Prosthetics in Rehabilitation,Third Edition,USA,Elsevier Inc.2000.