

MEDICINAL PLANTS IN WOUND RECUPERATING

Abstract

Wound mending is an intricate, unique interaction upheld by a bunch of cell occasions that should be firmly planned to proficiently fix harmed tissue¹. Recovery and tissue fix processes comprise of a succession of sub-atomic and cell occasions which happen after the beginning of a tissue sore to reestablish the harmed tissue. The exudative, proliferative, and extracellular grid renovating stages are successive occasions that happen through the incorporation of dynamic cycles including solvent arbiters, platelets, and parenchymal cells. Exudatives peculiarities that occur after injury add to the improvement of tissue oedema. The proliferative stage looks to lessen the area of tissue injury by contracting myofibroblasts and fibroplasia. At this stage, angiogenesis and reepithelialisation cycles can in any case be noticed. Endothelial cells can separate into mesenchymal parts, and this distinction has all the earmarks of being finely coordinated by a bunch of flagging proteins²

In this chapter focus is primarily on the effect of different description of wound, the mechanism involved in wound healing, different models used in wound healing. Moreover, this chapter also includes different evaluation parameters involved in wound healing, different herbal formulations available for wound healing, different plants used in wound healing.

Keywords: Medicinal plants, pharmacy, Medicine.

Author

Swati Sabharwal
IEC College of pharmacy
Greater Noida, Uttar Pradesh, India.

I. INTRODUCTION

1. **Definition of Wound:** An injury is a disturbance of tissue honesty that outcomes in misfortune or breaking of cell and anatomic or practical progression of living tissues. Wounds are inescapable events of life. It may arise due to physical, chemical or mechanical factors as shown in Fig 1.1^{3,4}

Legitimate mending of wound is fundamental for the rebuilding of upset physical coherence and disturbed useful status of the skin.⁵

2. **Signs and Symptoms:** Wounds are often accompanied by the following signs and symptoms⁵
 - Abnormal flushing and swelling of the skin as a result of the accumulation of fluid in body tissues
 - Heat and infection
 - Loss of function (or mobility) and foul smell (in infected wounds only)
 - Redness and pounding agony or delicacy in the injury region
 - Pus or watery fluid that has accumulated under the skin or is seeping from a wound

II. CLASSIFICATION

1. **Wound can be classified into two types:**

- **Chronic wounds:** Constant injuries are those that are made by a generally sluggish cycle that leads tissue harm. Constant injuries incorporate tension, venous and diabetic ulcers. Contamination then grabs hold of the site and turns into a persistent boil. When the contamination hits a basic point, it can spread locally or become foundational (sepsis).
- **Acute wounds:** It can be any gunshot wound or wound caused by animal bite.

2. **Acute wounds can further be classified in to eight categories:**

- **Abrasion:** These are likewise called as scratches, which happen when the skin is scoured away by grinding against another unpleasant surface.
- **Punctures:** These are profound, tight injuries delivered by sharp articles like nails, cuts and broken glass.
- **Avulsions:** It happens when a whole design or a piece of it is effectively pulled away, like the passing of a super durable tooth or an ear cartilage; creature chomps may likewise cause separations.
- **Contusions (Bruises):** These are the consequence of a powerful injury that harms an inward construction without breaking the skin. Disasters for the chest, mid-region or head with a heavy-handed tool (for example football or clench hand) can likewise cause wounds.
- **Crush wounds:** It happen when a weighty item falls on an individual, parting the skin and breaking or tearing basic designs.
- **Cuts:** These are cutting injuries made with a sharp instrument leaving even edges. They might be basically as negligible as a paper cut or as huge as a careful entry point.

- **Fish-hook wound:** A physical issue brought about by a fish-snare becoming implanted in delicate tissue.
- **Incised wound:** Any sharp cut where the tissues are not cut off. A neat and tidy brought about by a sharp cutting instrument - the injury might be aseptic or tainted, contingent upon the conditions.
- **Lacerations (Tears):** These are isolating injuries that produce worn out edges. They are created by a huge power against the body, either from an inside source as in labor, or from an outer source like a punch.
- **Penetrating wound:** In which the skin is broken and the specialist causing the injury enters subcutaneous tissue or a profound lying construction or hole (the specialist may be a nail, splinter or spike).

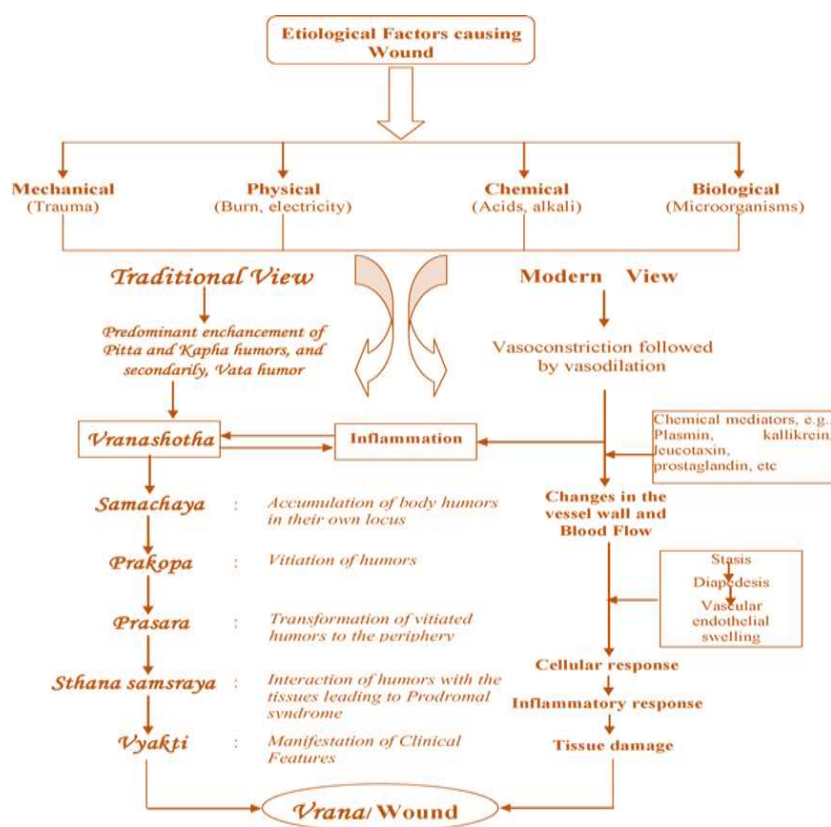


Figure 1: Factors causing wound

III. WOUND MENDING

Wound mending is characterized as a multifaceted cycle in which the skin (or another organ) fixes itself after injury and obliterated tissue supplanted by new living tissue.⁷ Solvent development factors control the methodical relocation, expansion and separation of cells as well as union and debasement of proteins. Wound recuperating includes recovery of specific cells by multiplication of enduring cells and connective tissue reaction portrayed by the arrangement of granulation tissue.⁸ Wounds recuperated by an unconstrained cycle in the creature through an outpouring of occasions what begins by turning on different compound signs in the body until the injury is connected by scar tissue that tight spot and hold the injury in balance which works with the rebuilding of physical coherence and capability of skin.⁶ The

recuperating of full thickness wounds reach out through the whole dermis which is a powerful cycle including solvent go between, platelets, extracellular grid, parenchymal cells and include more perplexing very much controlled natural occasions as shown in Fig 1.2.⁹The healing process begins with clotting of blood and is completed with remodelling of the cellular layers of skin.¹⁰

1. **Wound Mending is Partitioned Into Four Successive, Yet Covering 4 Stages:** as shown in Fig. 1.3.

- **Hemostasis:** which prevents blood loss.
- **Inflammation and debridement of wound:** to rapidly achieve a sterile environment.
- **Epithelial fix, including multiplication, assembly, movement and separation:** to contain the injury and to reestablish the epithelial obstruction.
- **Issue remodelling and collagen deposition:** to slowly organize the closed wound matrix for increased strength and elasticity.^{1, 10, 11}

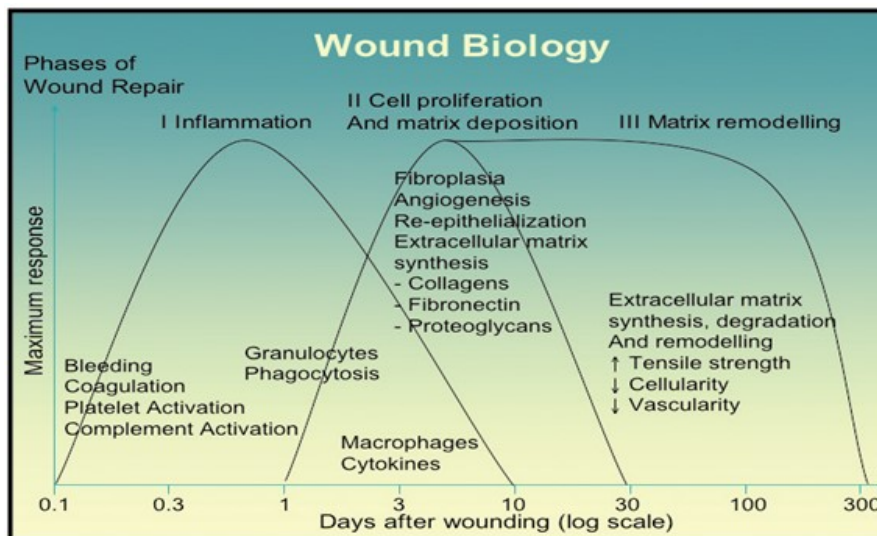


Figure 2: Wound Biology

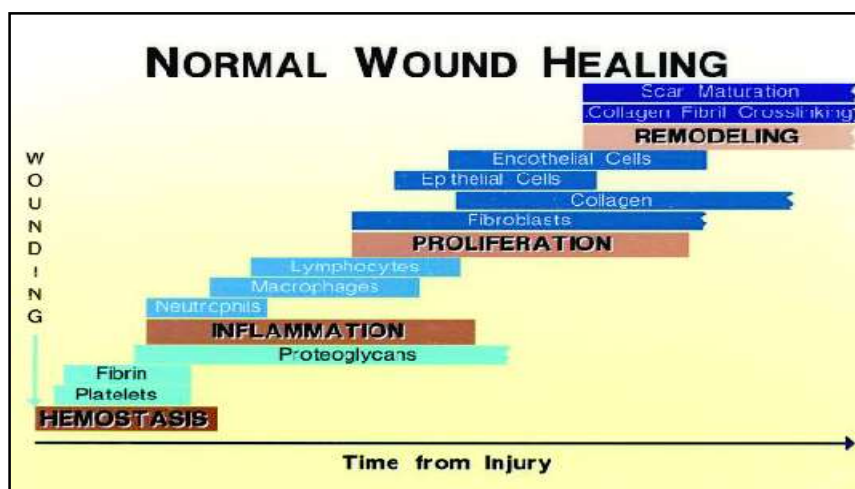


Figure 3: Different phases of Wound Healing

2. Sequences of Events Involved During Normal Wound Recuperating

- **Hemostasis:** At the point when tissue is first injured, blood interacts with collagen, setting off blood platelets to start discharging incendiary elements. Platelets likewise express glycoproteins on their cell films that permit them to adhere to each other and to total, shaping a mass.¹² Fibrin and fibronectin cross-interface together and structure a fitting that traps proteins and particles and forestalls further blood misfortune.¹³
 - **Vasoconstriction :** At the point when a vein is penetrated, burst cell layers discharge provocative variables like thromboxane's and prostaglandins that make the vessel fit to forestall blood misfortune and to gather fiery cells and elements nearby. This vasoconstriction endures five to ten minutes and is trailed by vasodilation.¹⁴
 - **Vasodilation:** One of the significant substances set free from pole cell granules is receptor. Receptor follows up on receptor and causes the widening of arterials and expanded porousness of venules.¹⁴
- **Inflammatory Phase:** It is a serious consequence of injury and one that frequently results in tissue repair and the restoration of function. The coagulating overflow occurs to achieve homeostasis or stop blood misfortune via a fibrin coagulation just before the fiery stage is initiated. This intensely provocative reaction typically lasts between 24 and 48 hours, but it occasionally lasts for as long as 14 days ¹⁵. Inflammatory oedema encircles all of the injured or repaired structures, fills up all of the wound's openings, and binds them altogether.¹¹
- **Polymorphonuclear Neutrophils:** In something like an hour of wound, polymorphonuclear neutrophils (PMNs) show up at the injury site and become the transcendent cells in the injury for the initial two days after the injury happens, with particularly large numbers on the subsequent day. Neutrophils phagocytise flotsam and jetsam and microbes and furthermore kill microscopic organisms by delivering free revolutionaries in what is known as a 'respiratory burst'.¹⁶
 - **Macrophages:** Macrophages are important cell components of granulation tissue and are essential for wound healing. Neutrophils and macrophages must work together immediately to maintain the contact. These cells promote the movement and division of endothelial cells, causing the connective tissue cells to neovascularize. Keratinocytes and collagen are then incorporated, leading to the reepithelialization of the wounded tissue. The macrophages debride damaged tissue by providing proteases, and they also phagocytize minute organisms and damaged tissue. Macrophages also release a variety of substances, including as cytokines and development factors.^{7,17}
- **Proliferative Phase:** Around a few days after the injury happens, fibroblasts start to enter the injury site, denoting the beginning of the proliferative stage even before the fiery stage has finished. The significant stages include are foundation of proper blood supply (angiogenesis), support of harmed dermal tissue (fibroplasias), production of porousness hindrance (reepithilialization).¹⁴

Angiogenesis: Angiogenesis alludes to the development of new vessels because of the extension of existing ones near the harm. Recently framed veins support the development of granulation tissue and give supplements and oxygen to developing tissues. Endothelial cells additionally make and discharge normally happening substances or cytokines during angiogenesis, including different cytokines and development factors.¹⁴

Four steps occur in the development of new capillary vessel¹⁶:

- Proteolytic debasement of the parent vessel storm cellar film.
- Relocation of endothelial cells toward the angiogenic boost.
- Expansion of the endothelial cells behind the main front of moving cells.
Development of endothelial cells with association in to slender cylinders.

3. Fibroplasia and granulation tissue: It is a course of fibroblast multiplication, relocation in to wound fibrin cluster and creation of new collagen and other network proteins that add to the development of granulation tissue. Fibroplasia closes two to about a month in the wake of injuring. In the initial a few days after injury fibroblasts principally relocate and multiply, while later they are the primary cells that set out the collagen network in the injury site.^{14,18}

- **Collagen deposition:** Collagen is the group of proteins and its statement is significant in light of the fact that it is the principal part of tissues like ligament and stringy tissue that builds the strength of the injury, additionally give solidness and construction to dermal tissue before it is set down.¹⁶Type III collagen and fibronectin are for the most part delivered in starting in considerable sums at somewhere close to around 10 hours and 3 days, contingent essentially upon wound size. Their affidavit tops at one to three weeks. The development of lactic corrosive impacts how much collagen delivered. Satisfactory supplies of oxygen, ascorbic corrosive and different cofactors, for example, zinc, iron and copper are expected to make the legitimate foundation for fibroplasias.¹⁹
- **Epithelialization:** It is the most common way of reestablishing a flawless epidermis after cutaneous injury. Basal keratinocytes from the injury edges and dermal extremities, for example, hair follicles, sweat organs and sebaceous organs are the fundamental cells liable for the epithelialization period of wound recuperating.¹⁸ Promptly after injury, unharmed epithelial cells at the injury edge start to replicate. The epithelial edge should deliver lytic catalyts, which act to sever the connection of non-feasible tissue from the reasonable injury bed. A scab structures as a transitory obstruction for the injury and ought not be upset until epithelialization is finished.⁶
- **Keratinocyte migration:** Keratinocytes movement is an early occasion in injury reepithelialization. Relocation starts as soon as a couple of hours subsequent to injuring. Be that as it may, epithelial cells require practical tissue to relocate across, so in the event that the injury is profound it should initially be loaded up with granulation tissue.^{19,20} Migration of keratinocytes over the wound site is stimulated by lack of contact inhibition and by chemicals such as nitric oxide.²¹

- **Contraction:** Withdrawal is a critical period of wound recuperating. Constriction begins roughly seven days after injury, when fibroblasts have separated into myofibroblasts. In full thickness wounds, constriction tops at 5 to 15 days after injury. Myofibroblasts, which are like smooth muscle cells, are answerable for compression.²²
- **Reconstitution of the dermis:** Dermal Reconstitution starts around 3 to 4 days after injury, portrayed clinically by granulation tissue development, which incorporates fresh blood vessels arrangement or angiogenesis, and the collection of fibroblast and ground lattices, named fibroplasias.¹⁴

IV. REMODELING PHASE

Renovating of collagen happens with cicatrization, coming about in a scar.²³ Redesigning comprises of the statement of the network and its resulting changes over the long haul. At the point when the degrees of collagen creation and debasement level, the development period of tissue fix is said to have started.²⁴

During development, type III collagen, which is predominant during expansion, is slowly corrupted and the more grounded type I collagen is set down in its place.¹⁵ Initially confused collagen Strands are revamped, cross-connected, and adjusted along strain lines. The beginning of the development stage might fluctuate broadly relying upon the size of the injury and whether it was at first shut or left open, going from roughly 3 days to 3 weeks.²⁶ The development stage can keep going for a year or longer, likewise relying upon wound sort. The development stage can keep going for a year or longer, comparably relying upon wound kind.

As the stage advances, the elasticity of the injury increments. The strength approaches around half that of typical tissue by 90 days after injury and eventually becoming as much as 80% solid as would be expected tissue.²⁶ Since movement at the injury site is decreased, the scar loses red appearance as veins are not generally required are taken out by apoptosis.²⁴

V. DIFFERENT MODELS FOR WOUND RECUPERATING ACTION

1. Incision Wound Model: Two 6 cm long paravertebral long incisions are made into the rat's skin in this procedure. Following the incision, the skin is held together and sewn back together with black silk thread, 0.5 cm apart. Stitching is done with bent needles and surgical threads. The injury is not covered. Drug is applied every day till full recovery takes place. The criterion that is then monitored to represent the level of wound healing is tensile strength.²⁷

- **Tensile Strength:** The animals are put to sleep seven days after the wound was first created. On the ninth day following a wound, sutures are removed, and on the tenth day, tensile strength is measured. Using the tensile testing equipment TKG-20, healing tissue and healthy skin are removed from both ends to determine the tensile strength. In both treatment and control animals, strips of excised tissue that are 8 mm wide and 20 mm long are cut off and loaded between the upper and lower holders of the machine in such a way that the effective load bearing size was 8x8 mm with the

wound still present in the middle. The following equation determines the tensile strength and measures the overall breaking load in newtons.²⁸

Tensile strength=Total breaking load/Cross-sectional area

2. Excision Wound Model: Before making wounds, diethyl ether anaesthesia was used to sedate every animal in each group.¹¹⁸ Using an accupunch with a 10mm diameter, a circular wound measuring about 10mm in diameter is produced in the dorsal thoracic middle region of the animal. Animals are put in individual cages once they have reached complete hemostasis. From the first post-injury day until the 16th, or until healing is complete, whichever comes first, the drug is applied every day. Monitoring is done for factors such histology, scar size, hydroxyproline content, and epithelialization time.²⁹

- **Wound Contraction:** The act of mobilising healthy skin from around the wound to cover the nipped area is known as wound contraction. This centripetal movement of the wound margin is thought to be caused by myofibroblast activity.

Wound contraction is calculated as percentage of the original wound size for each animal of a group and group mean on pre-determined days i.e. 4, 6, 8, 12 14,16th days after inflicting the wound for analysis of results.³⁰

Wound contraction (%) is calculated using the formula:

$$\text{Wound contraction (\%)} = [(WD0-WDt)/WD0] 100$$

Where:

WD0 = the wound diameter on day zero

WDt = the wound diameter on day t

- **Scar Area:** On the final day, when there appeared to be no change in the wound region and the wound had fully healed and closed, the scar area is measured by tracing the entire healed wound area on tracing paper.³¹
- **Hydroxyproline Determination:** Collagen is made out of amino corrosive for example hydroxyproline which is the significant part of extracellular tissue that gives backing and solidarity to the injury. The granulation tissue of wound is principally made out of fibroblast, collagen, edema and little fresh blood vessels.³²

Wound tissues are broke down for hydroxyproline content as depicted by woessner, which is an essential constituent of collagen. Tissues are dried in a hot air stove at 60-70°C to consistent weight and are hydrolysed in 6 M HCl at 130°C for 4 h in fixed tubes. The hydrolysate is killed to pH 7.0 and is then exposed to chloramine-T oxidation for 20 min. The response is ended by expansion of 0.4 M perchloric corrosive and variety will created with the assistance of Ehrlich reagent at 60°C and estimated at 550 nm utilizing an UV spectrophotometer. How much not set in stone with the standard bend.³³

- **Histopathology:** A cross over part of tissue is ready from each gathering of creature and stained haematoxylin and eosin to uncover the tissue segment plainly. Then, at

that point, the tissues are seen under magnifying lens to study different histopathological phenomenon. Amount of not set in stone with the standard bend²⁹

- 3. Dead Space Model:** In this model little cross over cut are made in the lumbar locale. A polypropylene tube (2.5 × 0.5 cm) is embed subcutaneously underneath the dorsal paravertebral lumbar skin. The day of the injury creation is considered as day zero. Granulation tissue framed on the polypropylene tube is collect via cautious analyzation on day 10 and the breaking strength of the granulation tissue is measure. The granulation tissue is then dried in a broiler at 60°C short-term and the dry weight is noted. The granulation tissue of wound is essentially made out of fibroblast, collagen, edema and little fresh blood vessels.³⁴

VI. WOUND RECUPERATING ASSESSMENT PARAMETERS

Hydroxyproline Determination³³

Principle: Collagen is quite possibly of the most generally appropriated protein in the set of all animals. Hydroxyproline, an amino corrosive which is found solely in collagen and which gives an immediate proportion of collagen content. Free hydroxyproline is let out of protein and peptides by corrosive hydrolysis, the corrosive is then killed. The hydroxyproline is oxidized to pyrrole with chloramines T at pH 6. This middle then, at that point, gives pink tone with 4-dimethylaminobenzaldehyde.

VII. REAGENTS

1. For Hydrolysis and Neutralization

6M- HCL

1.2M NaOH

2. Reagents for Colour Reaction

- **Stock reagents**

- **Acetate- citrate Buffer**

Sodium Acetate	- 57g
Citric Acid	- 33.4g
1M NaOH	- 435ml
Mixed until dissolved (add NaOH carefully)	

- **Chloramine T trihydrate (Sodium p-Toulenesulfonechloramide)**

ChloramineT	1.41g
Water	20ml
Methyl cellosolve	30ml
(Ethylene glycol monoethyl ether)	
Buffer	50ml

Solution is freshly prepared by dissolving 1.41g of chloramines T in 20ml water. 30ml of Methyl cellosolve and 50ml buffer were added.

- **Propan-2-ol** – 385ml, water up to 1 litre
- **DAB Reagent** – 10g p-dimethylaminobenzaldehyde in 15ml of 60% perchloric acid. Stored in dark colored bottle in the refrigerator (It is stable up to 3 weeks).
- **Working Reagents** (freshly prepared)
 - **Solution A- Chloramine T plus Acetate citrate buffer (1 : 4 by vol.)**
 - **Solution B-** DAB reagent plus propan-2-ol (3: 13 by vol.)

VIII. PROCEDURE

The creatures were forfeited on the sixteenth day (or in the wake of falling of scab) of wound creation and recovered tissues from the recuperated sore of wound were gathered for the assessment of hydroxyproline. Determined amounts of tissue test were drenched in 2ml of 6M-HCL and the cylinders were fixed without clearing. Hydrolysis was finished for 20 hrs at 105°C, hydrolyzed tissues were sifted through 0.22 µm needle channel. After filtration 100 µl of test was taken and 0.8ml of Isopropanol was blended to it. After that 0.4ml of arrangement A was blended and hatched at room temperature for 5 min. After hatching 6ml of arrangement B was blended and hatched at 58°C for 25 min. Then this combination was cooled under faucet water and absorbance was estimated at 550 nm inside 30 min. The amount of hydroxyproline was determined with the assistance of standard bend.

1. **Preparation of Standard Curve of Hydroxyproline:** For the preparation of standard curve, 50 mg hydroxyproline was dissolved in 200ml distilled water to get 0.25 mg/ml stock solution.

To prepare the standard curve 0, 10, 20, 30, 40, 50, 60, 70, 80, 90, 100 µl of standard hydroxyproline was taken in tubes and volume was made up to 200 µl with distilled water. 100 µl of sample was taken from each dilution and 800µl isopropanol was mixed. Then 400 µl solution A was mixed and incubated at room temperature for 5 min. Further 6ml of solution B was mixed and incubated at 58°C for 25 min. The samples were cooled under tap water and absorbance was measured at 550 nm within 30 min. Now the graph was plotted between concentration and absorbance to obtain the standard curve

- **Epithelialization Period³⁵:** Epithelialization period is the quantity of days expected for falling of the scab with no remaining crude injury behind.
- **Determination of Wound Contraction³⁶:** The extraction wound edges were followed at 4-day stretches by following the crude injury region, which was estimated by backtracking the injury on a millimeter scale chart paper. The wound of the animals was photographically documented. The wound contraction percentage was determined from the measurements using the formula.

$$\% \text{ wound contraction} = \frac{\text{Initial wound area} - \text{final wound area}}{\text{Initial wound area}} \times 100$$

Initial wound area

2. Herbal Marketed Formulations for Wound Recuperating

- **Calendula Ointment** (By Greenridge Company, Philadelphia, United States)
Ingredients:
Calendula officinalis
- **Trypsin Complex Ointment** (By Breckenridge Pharmaceutical, Boca Raton, USA)
Ingredients:
Trypsin
Resin peru
Castor oil
Glyceryl monostearate
Glycine
L-Proline
Taurine and
White petrolatum
- **Silver Herbal Ointment** (By Natural path wings, Nashville, TN, India)
Ingredients:
Colloidal silver
- **Comfrey Herbal Infused Oil**
By Nanning Innovative Pharmaceutical Technology Co., Ltd, Guangxi, China)
Ingredients:
Symphytum officinale flowers
- **Comfrey Ointment** (By Blues Farm Investments LLC, Melrose, US)
Ingredients:

Essential oils of lemon (*Citrus limonum*)
Oil beeswax (*Cera flava*)
Shea butter (*Butyrospermum parkii*)
Olive oil (*Olea europaea*)
Aloe Vera (*Aloe barbadensis*)
Lavender (*Lavandula angustifolia*)
Tocopherol (Vitamin E)
Rosemary extracts (*Rosmarinus officinalis*)
Comfrey leaf & root extracts (*symphytum officinale*)
Organic hempseed oil
Soybean (*Glycine max*)
- **Wound Care Ointment** (By Weleda Pharmaceuticals, Arlesheim, Switzerland)
Ingredients:

Lanolin
Peruvian balsam
Sesame oil
Water

Alcohol
Beeswax
Lanolin alcohols
Larch resin
Calendula officinalis
Mercurialis perennis

- **Wound Honey**(By Eras Natural Sciences,New Zealand)
Ingredients:
Active Manuka honey
- **Mederma[®] Skin Care For Scars (By Mederma)**
Ingredients:
Water (Purified)
PEG 4
Fragrance
Methylparaben
Ascorbic acid
Allium cepa bulb extracts (Onion)
Xanthan gum
Allantoin
- **Aloe Vesta 3-n-1 Protective Ointment** (By Convatec Pharmaceuticals, Skillman United states of America)
Ingredients:
Petrolatum 43%
- **Medihoney hydrocolloid wound paste** (By Medihoney Pharmaceuticals, Australia)
Ingredients
Active manuka honey
- **Terrasil Max Therapeutic Skin Care ointment** (By Terrasil Pharma, United States)
Ingredients:
Activated Minerals
- **Jakhme Ruz - Pink Ointment Balm** (By Bhawsar Chemicals Pvt Ltd, Leicester, Leicestershire, UK)
Ingredients: Jasat bhasm, ,Tankankhar, Gandhak, Ras Kapoor

IX. LIST OF MEDICINAL PLANTS USED FOR THE SCREENING OF WOUND RECUPERATINGACTIVITY

S.No	Plant	Part Used/ Extract	Model Used/ Dose	Result/Inference
1	<i>Acalypha indica</i> ³⁷ (<i>Euphorbiaceae</i>)	Whole Plant/ Ethanol	Excision Incision	Good wound healing activity
2.	<i>Achillea kellalensis</i> ³⁸ (<i>Compositae</i>)	Flowers/ Aqueous	Excision/ 10% w/w ointment	Significant healing activity
3.	<i>Acorus calamus</i> ³⁹ (<i>Acoraceae</i>)	Leaves/ Ethanol	Excision Incision Dead Space/ 40% w/w ointment	Therapeutic benefits in wound healing
4.	<i>Adhatoda vasica</i> ⁴⁰ (<i>Acanthaceae</i>)	Leaves/ Methanol, Chloroform, Diethyl ether	Excision	Significant healing activity comparable to standard (nitrofurazone ointment)
5.	<i>Aegle marmelos</i> ⁴¹ (<i>Rutaceae</i>)	Leaves, Roots, Root Barks/ Aqueous Methanol	Excision Incision	Wound healing activity comparable to Standard (nitrofurazone ointment)
6.	<i>Ageratum conyzoides</i> ⁴² (<i>Asteraceae</i>)	Leaves/ Aqueous	Excision/ 10% w/w ointment	Work justifies the use in wound healing activity
7.	<i>Alangium salvifolium</i> ⁴³ (<i>Alangiaceae</i>)	Leaves/ Ethanol	Excision Incision Dead space/ 150 and 300mg/kg	Enhanced wound healing activity
8.	<i>Allamanda cathartica</i> ⁴⁴ (<i>Apocynaceae</i>)	Leaves/ Aqueous	Excision incision/ 150mg/kg	Significant activity of <i>Allamanda cathartica</i>
9.	<i>Allium cepa</i> ³ (<i>Liliaceae</i>)	Bulbs/ Chloroform Alcohol	Excision Incision Dead Space/ 300mg/kg	Enhanced activity due to free radical scvanging activity of plant

S.No	Plant	Part Used/ Extract	Model Used/ Dose	Result/Inference
10.	<i>Aloe Ferox miller</i> <i>Aloe arborescens</i> ⁴⁵ (Liliaceae)	Leaves/ Juice	Excision	Therapeutics benefits for topical treatment in skin wounds
11.	<i>Alternanthera</i> <i>sessilis</i> ⁴⁶ (Amaranthac <i>eae</i>)	Leaves/ Pet ether, Chloroform	Excision/ 200µg/ml	Significant activity
12.	<i>Areca catechu</i> ⁴⁷ (Areaceae)	Nuts/ Alcohol	Excision Dead space	Enhanced Activity
13	<i>Aristolochia</i> <i>bracteolate</i> ⁴⁸ (Aristolochiaceae)	Leaves/ Ethanol	Excision Incision Dead space/ 400 and 800mg/kg b.wt.	Definite Pro Healing action
14.	<i>Arrabidaea</i> <i>verlot</i> ⁴⁹ (Bignoniaceae)	Leaves/ Ethanol	Excision/ 100mg/ml	Moderate wound healing activity
15.	<i>Astilbe thunbergii</i> ⁵⁰ (Saxifragaceae)	Rhizomes/ Ethyl acetate, Ethanol	Excision/ 100ng/ml	Enhanced activity due to promotional angiogenesis
16.	<i>Azardirachta indica</i> ⁵¹ (Meliaceae)	Twigs/ Oil	Excision Incisions Dead Space/ 1% and 2% w/w ointment	Good activity in all models
17.	<i>Buchanania lanzan</i> ⁵² (Anacardiaceae)	Fruits/ Ethanol	Excision Incision Dead Space/ 300mg/kg p.o	—
18.	<i>Buddleja globosa</i> ⁵³ (Buddlejaceae)	Leaves/ Aqueous, Ethanol	Excision	Accelerate activity due to flavanoids
19	<i>Butea monosperma</i> ⁵⁴ (Fabaceae)	Barks/ Alcohol	Dead Space	Increase activity due to synergistic effect of their constituents
20.	<i>Calendula officinalis</i> ⁵⁵ (Asteraceae)	Unflorescence/ Hexane, Ethanol	Excision Incision/ 20 and 100mg/kg b.wt.	Potent healing activity

S.No	Plant	Part Used/ Extract	Model Used/ Dose	Result/Inference
21.	<i>Calotropis gigantea</i> ⁵⁶ (<i>Apocynaceae</i>)	Latex	Excision Incision /100, 200, 400mg /kg b.wt.	Accelerate activity supports its traditional use
22.	<i>Calotropis procera</i> ⁵⁷ (<i>Asclepiadaceae</i>)	Latex	Excision Dead Space/ 20µl of 1% sterile solution	Traditional use in the management of wound healing
23.	<i>Carica candamarcensis</i> ⁵⁸ (<i>Caricaceae</i>)	Fruits	Excision/ 1% w/w ointment	Good healing properties
24.	<i>Caryocar cariaceum</i> ⁵⁹ (<i>Caryocaraceae</i>)	Seeds/ Fixed oil	Excision/ 6 and 12% w/w ointment	Increase activity
25.	<i>Cassia fistiula</i> ⁶⁰ (<i>Fabaceae</i>)	Leaves/ Alcohol	Excision Dead Space	Supports its traditional use in wound healing activity
26.	<i>Cassia occidentalis</i> ⁶¹ (<i>Fabaceae</i>)	Leaves/ Methanol	Excision Incision Dead Space/ 200mg/kg b.wt.	Increase wound healing activity
27.	<i>Catharanthus roseus</i> ⁶² (<i>Apocynaceae</i>)	Leaves/ Ethanol	Excision Dead Space/ 100mg/Kg/day	Increment movement support the utilization in the administration of wound mending
28.	<i>Centaurea sadleriana</i> Janka ⁶³ (<i>Asteraceae</i>)	Aerial Parts/ N-Hexane Fraction of Methanol	Excision	Significant activity supports folk medicinal use of plant
29.	<i>Centella asiatica</i> ⁶⁴ (<i>Mackinlayaceae</i>)	Leaves/ Aqueous	Excision Incision Dead Space/ 0.2% solution	Significant healing activity
30.	<i>Centraurea iberica</i> ⁶⁵ (<i>Loranthaceae</i>)	Aerial Parts/ Ethanol	Excision Incision/ 1% w/w ointment	Remarkable wound healing activity
31.	<i>Cinnamomum zeylanicum</i> ⁶⁶ (<i>Lauraceae</i>)	Barks/ Methanol	Excision Incision Dead Space/	Enhanced wound healing activity

S.No	Plant	Part Used/ Extract	Model Used/ Dose	Result/Inference
			250 and 500mg/kg b.wt.	
32.	<i>Clerodendron splendens</i> ⁶⁷ (<i>Verbenaceae</i>)	Aerial Parts/ Methanol	Excision Incision Dead Space	Justifies the traditional use in wound healing and skin infections
33.	<i>Clerodendrum infortunatum</i> ⁶⁸ (<i>Verbenaceae</i>)	Leaves/ Ethanol	Excision Incision Dead Space	Significant healing activity
34.	<i>Copaifera langsdorffii</i> ⁶⁹ (<i>Fabaceae</i>)	Barks/ Oleo-resin	Excision, incision/ 4% w/w ointment	Legitimizes the conventional use in injury the board
35.	<i>Crataeva nurvala</i> ⁷⁰ (<i>capparidaceae</i>)	Root barks/ Ethanol	Excision, incision, Dead space/ 150 and 200mg/kg b.wt.	Improved action because of free revolutionary scvanging action of plant
36.	<i>Curculigo orchioides</i> ⁷¹ (<i>Hypoxidaceae</i>)	Root Tubers/ Methanol	Excision/ 200 and 400mg/kg	Significant healing activity
37.	<i>Curcuma longa</i> ⁷² (<i>zingiberaceae</i>)	Rhizomes/ Aqueous	Excision Incision	Faster rate of wound contraction compared to control (Simple ointment)
38.	<i>Cyperus rotundus</i> ⁷ (<i>Cyperaceae</i>)	Leaves/ Alcohol	Excision Incision Dead Space/ 0.5,1 and 2% w/w of extract	–
39.	<i>Datura alba</i> ⁷⁴ (<i>solonaceae</i>)	Leaves/ Alcohol	Excision Dead Space/ 10% w/w ointment	Legitimizes the customary use in injury the board
40.	<i>Dendrophthae falcata</i> ⁷⁵ (<i>Loranthaceae</i>)	Aerial Parts/ Ethanol	Excision Incision	Potent wound healing capacity
42	<i>Desmodium triquetrum</i> ⁷⁶ (<i>Fabaceae</i>)	Leaves/ Ethanol	Excision Incision	Pro healing action
43	<i>Echinacea pallida</i> ⁷⁷ (<i>Asteraceae</i>)	Leaves/ Alcohol	Excision	Good healing activity

S.No	Plant	Part Used/ Extract	Model Used/ Dose	Result/Inference
44	<i>Elaeis guineensis</i> ⁷⁸ (<i>Palmae</i>)	Leaves/ Methanol	Excision/ 10% w/w	Potent healing capacity
45	<i>Elephantopus scaber</i> ⁷⁹ (<i>Asteraceae</i>)	Leaves/ Ethanol	Excision Incision Dead Space	Enhanced activity in all models
46	<i>Embelia ribes</i> ⁸⁰ (<i>Myrsinaceae</i>)	Leaves/ Ethanol	Excision Incision Dead Space/ 30mg/ml	Significant healing activity
47	<i>Euphorbia heterophylla</i> ⁸¹ (<i>Euphorbiaceae</i>)	Leaves/ Ethanol	Excision/ 10% w/w ointment	Good healing properties
48	<i>Evolvulus numularius</i> ⁸² (<i>Convolvulaceae</i>)	Leaves/ Methanol & Aqueous	Excision	Significant healing activity
49	<i>Ficus religiosa</i> ⁸³ (<i>Moraceae</i>)	Leaves/ Hydroalcohol	Excision Incision/ 55 and 10% w/w ointment	Significant increase in healing activity

X. CONCLUSION

In this we portrayed different system of activity of wound mending, various models use in injury recuperating movement and various boundaries used to assess wound mending action. In light of review and introduced an outline of proof that makes sense of why numerous restorative plants are utilized as customary medicines for cutaneous injuries and clinical skin problems. It could not be absolutely expressed about adequacy of therapeutic plants in injury recuperating however restorative plants with their dynamic fixings at any point have significant potential for working on injury mending.

REFERENCES

- [1] Wound healing: cellular mechanisms and pathological outcomes
a. Holly N. Wilkinson and Matthew J. Hardman Published: 30 September 2020
- [2] Wound healing - A literature review *An Bras Dermatol.* 2016 Sep-Oct; 91(5): 614–620.
- [3] Shenoy C, Patil MB, Kumar, Patil S. Preliminary phytochemical investigation and wound healing activity of *Allium Cepa* Linn (Liliaceae). *Int J Pharm Pharm Sci* 2009;2(2):167-75.
- [4] Chattopadhyay D, Arunachalam G, Mandal AB, Sur TK, Mandal SC, Bhattacharya SK. Antimicrobial and anti-inflammatory activity of folklore: *Mellotus peltatus* leaf extract. *J Ethnopharmacol* 2002;82:229–37
- [5] Wound infection signs and preventive measures. [Online]. [cited 2010 Oct 20]; Available from: URL: www.alternativedr.com/wounds1.htm
- [6] Mallefet P, Dweck AC. Mechanisms involved in wound healing. *The Biomed Scientist* 2008:609-15.
- [7] Das S. A Text book of surgery. 3rd ed. Old mayor's court, Calcutta: 2001. vol 1. p. 1-7.
- [8] Okoli CO, Ezike AC, Akah PA, Udegbunam SO, Okoye TC, Mbanu TP et al. Studies on wound healing and antiulcer activities of extract of aerial parts of *Phyllanthus niruri* L. (*Euphorbiaceae*). *Am J Pharmacol* 2009;4(4):118-26
- [9] Ather S, Chan DS, Harding KG. The biology of wound healing. *EAHP* 2007;13(3):53-5.

- [10] Schwartz BF, Neumeister M. The mechanics of wound healing. *Future Directions in Surg* 2006;78-9.
- [11] Robert FD, Melissa CE. Wound healing: An overview of acute, fibrotic and delayed healing. *Front Biosci* 2004;9:283-9.
- [12] Midwood KS, Williams LV, Schwarzbauer JE. Tissue repair and dynamics of extracellular matrix. *Int J Biochem Cell Biol* 2004;36(6):1031-7.
- [13] Hodde JP, Johnson CE. Extracellular matrix as a strategy for treating chronic wounds. *Am J Clin Dermatol* 2007;8(2):61-6
- [14] Li J, Chen J, Kirsner R. Pathophysiology of acute wound healing. *Clin in Dermatol* 2007;25:9-18.
- [15] Martin P, Leibovich SJ. Inflammatory cells during wound repair: the good, the bad and the ugly. *Trends Cell Biol* 2005;15(11):599–607.
- [16] Robbins KC. *Basic Pathology*. Philadelphia: Saunders; 8th Ed. 2007.p. 48-59.
- [17] Newton PM, Watson JA, Wolowacz RG, Wood EJ. Macrophages Restrain Contraction of an in Vitro wound healing model. *Inflammation* 2004;28 (4):207-14
- [18] Adam JS, Richard AF, Clark. Cutaneous wound healing. *New Engl J Med* 1999;341(10):738-46.
- [19] Toole EAO. Extracellular matrix and keratinocyte migration. *Clin. Exp. Dermatol* 2001;26:525-30.
- [20] Bartkova J, Gron B, Dabelsteen E, Bartek J. Cell-cycle regulatory proteins in human wound healing. *Arch Oral Biol* 2003;48(2):125–32.
- [21] Witte MB, Barbul A. Role of nitric oxide in wound repair. *Am J Surg* 2002;183(4):406–412.
- [22] Eichler MJ, Carlson MA. Modeling dermal granulation tissue with the linear fibroblast populated collagen matrix: a comparison with the round matrix model. *J Dermatol Sci*2006;41(2):97–108.
- [23] Shenoy R. *Manipal Manual of Surgery*. 2nd ed. New delhi: CBS Publication; 2005. p. 1-4.
- [24] Greenhalgh DG. The role of apoptosis in wound healing. *Int J Biochem Cell Biol* 1998;30(9):1019–30.
- [25] Traversa B, Sussman G. The role of growth factors, cytokines and proteases in wound management. *Primary Intention* 2001;9(4):161-7.
- [26] Mohan H. *Pathology-Quick Review and MCQs*. 4th ed. New Delhi: Jaypee Brothers medical publishers; 2000. p. 88-91.
- [27] Sheeba M, Emmanuel S, Revathi K, Ignacimuthu S. Wound healing activity of *Cassia Occidentalis* L. in albino wistar rats. *Int J Integr Biol*2009;8(1):1-6.
- [28] Shukla AR, Jain GK, Shankar R, Kulshrestha DK, Dhawan BN. *In vitro* and *in vivo* wound healing activity of asiaticoside isolated from *Centella asiatica*. *J Ethnopharmacol* 1999;65(1):1-11.
- [29] Karodi R, Jadhav M, Rub R, Bafna A. Evaluation of the wound healing activity of a crude extract of *Rubia cordifolia* L. (Indian madder) in mice. *Int J Appl Res Nat Prod* 2009;2(2):12-18.
- [30] Nalwaya N, Pokharna G, Deb L, Jain NK. Wound healing activity of latex of *calotropis gigantean*. *Int J Pharm Pharm Sci* 2009;1(1):176-81.
- [31] Kaushal M, Kutty NGC, Rao CM. Wound healing activity of NOE-aspirin: A pre-clinical study. *Nitric Oxide* 2007;16:150–6.
- [32] Singh SDJ, Krishna V, Mankani KL, Manjunatha BK, Vidya SM, Manohara YN. Wound healing activity of leaf extract and deoxyelephantopin isolated from *Elephantopus scaber* Linn. *Indian J Pharmacol* 2005;37(4):238-42.
- [33] Woessner J F. The determination of hydroxyproline in tissues and protein samples containing small proportion of this imino acid. *Arch. Biochem. Biophys* 1961;93:440-7.
- [34] Shabang T, Sharma C, Adiga S, Bairy LK, Shenoy S, Shenoy G. Wound healing activity of alcoholic extract of *Kaempferia glangain* wistar rats. *Indian J Physiol Pharmacol* 2006;50(4):384–90.
- [35] Dinesh M, Manjunath C, Joshi VG, Karigar AA, Sikarwar MS. Wound healing property of ethanolic extract of *Crataeva nurvala* root bark. *J Pharm Res* 2010;3(11):2788-9.
- [36] Rashed AN, Afifia FU, Disi AM. Simple evaluation of the wound healing activity of a crude extract of *Portulaca oleracea* L. (growing in Jordan) in *Mus musculus* JVI-1. *J Ethnopharmacol* 2003;88:131–6.
- [37] Reddy JS, Rao PR, Redy MS. Wound healing effects of *Heliotropium indicum*, *Plumbago zeylanicum* and *Acalypha indica* in rats. *J Ethnopharmacol* 2002;79(2):249-51.
- [38] Pirbalouti AG, koopayeh, karimi I. The wound healing activity of flower extracts of *Punica Granatum* and *Achillea Kelallensis* in wistar rats. *Acta Poloniae Pharmaceutica Drug Res* 2010;67(1):07-110.
- [39] Jain N, Jain R, Jain. A, Jain DK, Chandel HS. Evaluation of wound-healing activity a. of *Acorus calamus* Linn. *Nat prod res* 2010;24(6):534-41.
- [40] Vinothapooshan G, Sundhar K. Wound healing effect of various extract of *Adhatoda* a. *vasica*. *Int J of Pharm Bio Sci* 2010;1(4):530-36.
- [41] Jaswanth AD, Akilan V, Loganathan S. Wound healing activity of *Aeglemarmelos*. a. *Indian J Pharm Sci* 2008;56(1):41-4.
- [42] Mustafa MR, Mahmood AA, Sidik K, Noor SM. Evaluation of wound healing potential

- a. of *ageratum conyzoides* leaf extract in combination with honey in rats animal model.
i. Int J mol med Adv sci 2005;1(4):406-10.
- [43] Asif KA, Shariff WR, Sikarwar MS. Wound healing property of alcoholic extract of leaves of *Alangium salvifolium*. J Pharm Res 2010;3(2):267-69.
- [44] Nayak S, Nalabothu P, Sandiford S, Bhogadi V, Adogwa A. Evaluation of wound healing activity of *Allamanda cathartica*. L. and *Laurus nobilis*. L. extracts on rats. CAM 2006;6(12):6-12.
- [45] Jia Y, Zhao G, Jicheng J. Preliminary evaluation: The effects of *Aloe ferox* Miller. and *Aloe arborescens* Mille.r on wound healing. J Ethnopharmacol 2008;120(2):181-9.
- [46] Jalalpure SS, Agrawal N, Patil MB, Chimkode R, Tripathi A. Antimicrobial and wound healing activities of leaves of *Alternanthera sessilis* Linn. Int J Green Pharm 2008;2(3):141-44.
- [47] Azeez S, Amudhan S, Adiga S, Rao N, Laxminarayana AU. Wound healing profile of *Areca Catechu* extracts on different wound models in wistar rats. Kuwait Med J 2007;39(1):48-52.
- [48] Shirwaikar AP, Somashekar AL, Udupa SL, Somashekar S. Wound healing studies of *Aristolochia bracteolata* Lam. with supportive action of antioxidant enzymes. Phytomedicine 2003;10(6-7):558-62.
- [49] Jorge MP, Madjarof C, Tasca AL, Rui G, Fernandes AT, Alexandre R. Evaluation of wound healing properties of *Arrabidaea chica* Verlot extract. J Ethnopharmacol 2008;118(3):361-66.
- [50] Kimura Y, Sumiyoshi M, Sakanaka M. Effects of *Astilbe thunbergii* rhizomes on
a. wound healing. J Ethnopharmacol 2007;109(1,3):72-7.
- [51] Chaudhari RY, Patil VR. Promotion of cutaneous wound healing by herbal formulation containing azadirachta indica and cynodon dactylon extract in wistar. Int J Pharm Res Dev June 2011;3(4):80-86.
- [52] Prasad P, Pavan KK, Alla NR. Wound healing activity of alcoholic extract of *Buchanania lanzan* in albino rats. Int J Chem Tech Res 2009;1(4): 1026-31.
- [53] Mensah AY, Sampson J, Houghton PJ, Hylands PJ, Westbrook J, Dunn M, et al. Effects of *Buddleja globosa* leaf and its constituents relevant to wound healing. J Ethnopharmacol 2001;77(2-3):219-26.
- [54] Miriyala S, Panchatcharam M, Lochin S. Efficacy of *Butea monosperma* on dermal wound healing in rats. Int J Biochem Cell Biol 2005;37(3):566-73.
- [55] Fronza M, Heinzmann B, Hamburger M, Laufer S and Merfort I. Determination of the wound healing effect of *Calendula* extracts using the scratch assay with 3T3 fibroblasts. J Ethnopharmacol 2009;126(3,10):463-67.
- [56] Nalwaya N, Pokharna G, Deb L, Jain NK. Wound healing activity of latex of *calotropis gigantea*. Int J Pharm Pharm Sci 2009;1(1):176-81.
- [57] Rasik AM, Raghubir R, Gupta A, Shukla A, Dubey MP, Srivastava S, et al. Healing potential of *Calotropis procera* on dermal wounds in Guinea pigs. J Ethnopharmacol 1999;68(1-3):261-66.
- [58] Gomes FSL, Spinola CDV, Ribeiro HA, Lopes MTP, Cassali GD, Salas CE. Wound-healing activity of a proteolytic fraction from *Carica candamarcensis* on experimentally induced burn. Burns March 2010;36(2):277-83.
- [59] Oliveira MLM, Nunes-Pinheiro DCS, Tome AR, Mota EF, Islene. *In vivo* topical anti-inflammatory and wound healing activities of the fixed oil of *Caryocar coriaceum* Wittm. Seeds. J Ethnopharmacol 2010;129(2):214-19.
- [60] Muthusamy SK, Sripriya R, Raghavan HV, Sehgal PK. Wound healing potential of *Cassia fistula* on infected albino rat model. J S R J 2006;131(2):283-89.
- [61] Sheeba M, Emmanuel S, Revathi K, Ignacimuthu S. Wound healing activity of *Cassia Occidentalis* L. in albino wistar rats. Int J Integr Biol 2009;8(1):1-6.
- [62] Nayak BS, Pinto Pereira LM. *Catharanthus roseus* flower extract has wound-healing activity in Sprague Dawley rats. Fitoterapia 2007;78(7-8):540-44.
- [63] Csupor D, Blazso G, Balogh A, Hohmann J. The traditional hungarian medicinal plant *Centaurea sadleriana* Janka accelerates wound healing in rats. J Ethnopharmacol 2010;127(1):193-95.
- [64] Shukla AR, Jain GK, Shankar R, Kulshrestha DK, Dhawan BN. *In vitro* and *in vivo* wound healing activity of asiaticoside isolated from *Centella asiatica*. J Ethnopharmacol 1999;65(1):1-11.
- [65] Koca U, Suntar IP, Keles H, Yesilada E, Akkol EK. *In vivo* anti-inflammatory and wound healing activities of *Centaurea iberica* Trev. ex Spreng. J Ethnopharmacol 2009;126(3):551-6.
- [66] Kamath JV, Rana AC, Chowdhury AR. Pro-healing effect of *Cinnamomum zeylanicum* bark. Phytother Res 2003;17(8):970-2.
- [67] Gbedema SY, Emelia K, Francis A, Kofi A, Eric W. Antimicrobial and wound
a. healing activities of *Clerodendron splendens* G. Don. Fitoterapia 2010;2(2):63-8.
- [68] Gouthamchandra K, Mahmood R, Manjunatha H. Free radical scavenging, antioxidant enzymes and wound healing activities of leaves extracts from *Clerodendrum infortunatum* L. Environ. Toxicol Pharmacol 2010;30(1):11-8.

- [69] Paiva LAF, Cunha A, Santos FA, Gramosa NV, Silveira ER, Rao VSN. Investigation on the wound healing activity of oleo-resin from *Copaifera langsdorffi* in rats. *Phytother Res* 2002;16(8):737-9.
- [70] Dinesh M, Manjunath C, Joshi VG, Karigar AA, Sikarwar MS. Wound healing property of ethanolic extract of *Crataeva nurvala* root bark. *J Pharm Res* 2010;3(11):2788-9.
- [71] Agrahari AK, Panda SK, Meheri A, Padhan AR. Screening of wound healing activity of *Curculigo orchioides Gaertn* root tubers methanolic extract. *International J Phar Appl Sci* 2010;1(1):91-5.
- [72] Santhanam G, Nagarjan S. Wound healing activity of *Curcuma aromatica* and *Piper betle*. *Fitoterapia* 2007;61(5):458-9.
- [73] Puratchikody DC, Nagalakshmi G. Wound healing activity of *cyperus rotundus* linn. *Indian J Pharm Sci* 2006;68(1):97-101.
- [74] Shanmuga PK, Radhakrishnan N, Babu M. Healing potential of *Datura alba* a. wounds in albino rats. *J Ethnopharmacol* 2002;83(3):193-9.
- [75] Pattanayak SP, Sunita P. Wound healing, anti-microbial and antioxidant potential of *a. Dendrophthoe Falcate* (L.f) Ettingsh. *J Ethnopharmacol* 2008;120(2):241-7.
- [76] Shirwaiker A, Jahagirdar S, Udupa AL. Wound healing activity of *Desmodium triquetrum* leaves Indian J Pharm Sci 2003;65(5):461-4.
- [77] Zhai Z, Haney DM, Wu L, Solco AK, Murphy PA, Wurtele ES, et al. Alcohol extract of *Echinacea pallida* reverses stress-delayed wound healing in mice. *Phytomedicine* 2009;16(6-7):669-78.
- [78] Sasidharan S, Nilawatyi R, Xavier R, Latha LY, Amala R. Wound healing potential of *Elaeis guineensis* Jacq leaves in an infected albino rat model. *Mol* 2010;15:3186-99.
- [79] Singh SDJ, Krishna V, Mankani KL, Manjunatha BK, Vidya SM, Manohara YN. Wound healing activity of leaf extract and deoxyelephantopin isolated from *Elephantopus scaber* Linn. *Indian J Pharmacol* 2005;37(4):238-42.
- [80] Kumara Swamy HM, Krishna V, Shankarmurthy K, Abdul Rahiman B, Mankani K L, Mahadevan K M, et al. Wound healing activity of embelin isolated from the ethanol extract of leaves of *Embelia ribes* Burm. *J Ethnopharmacol* 2007;109(3):529-34.
- [81] James O, Friday ET. Phytochemical composition, bioactivity and wound healing potential of *euphorbia heterophylla* (Euphorbiaceae) leaf extract. *IJPBR* 2010;1(1):54-63.
- [82] Saini V, Kingler HK, Sharma DK. Ahuja N, Middha A, Gupta VB. Wound healing activity of *Evolvulus numularius* Linn. *Asian J Chem* 2007;19(7):5772-4.
- [83] Roy K, Shivakumar H, Sarkar S. Wound healing potential of leaf extracts of *Ficus Religiosa* on wistar albino strain rats. *Int J of Pharm Tech* 2009;1(3):506-8.