

WELL DIFFERENTIATED THYROID CANCERS

Abstract

Well differentiated thyroid cancers are a class of cancers that have one of the best prognosis. They include papillary and follicular cancers with a few of their subtypes. They often present as solitary thyroid nodules. Cervical lymph node metastases is more common in papillary carcinoma than follicular carcinomas. Diagnosis is made with the help of thyroid ultrasonography coupled with fine needle aspiration cytology. Surgical management can either be lobectomy for low risk, small tumors or sub total/ total thyroidectomy for larger, high risk tumors. Total thyroidectomy enables better post operative follow up via serum thyroglobulin levels and radio iodine scans. Remnant thyroid tissue is ablated with radioiodine and patients are kept on suppressive doses of thyroxine to decrease risk of recurrence. 10 year prognosis is usually >95%, especially in patients with PTC.

Authors

Dr Amena Khan
Senior Resident
Department of General Surgery
King George's Medical University
Lucknow, India.

I. INTRODUCTION

A steady increase has been seen in the worldwide incidence of thyroid cancers. This rise in incidence rates is almost entirely due to increased detection of differentiated thyroid cancers especially papillary thyroid cancer, The incidence of the remaining thyroid cancers (follicular, anaplastic and medullary) hasn't changed much over the last 30 years.

Most thyroid tumors arise from follicular epithelial cells, while a small number are derived from calcitonin-secreting C cells. Follicular cell derived neoplasms are categorised into benign, low risk neoplasms and malignant neoplasms based on histopathological features, lymph nodal and extra thyroidal extension.

The updated 2022 WHO classification of malignant thyroid neoplasms is as follows:

1. Follicular thyroid carcinoma
2. Invasive encapsulated follicular variant papillary thyroid carcinoma
3. Papillary thyroid carcinoma
4. Oncocytic carcinoma of thyroid
5. Follicular-derived carcinomas, high grade
 - Poorly differentiated thyroid carcinoma
 - Differentiated high grade thyroid carcinoma
6. Anaplastic follicular cell derived thyroid carcinoma: Of these malignant neoplasms, follicular carcinoma and papillary thyroid cancers are considered to be amongst the well differentiated variety of cancers.

II. PAPILLARY THYROID CARCINOMA

1. **Clinical Features:** Papillary carcinoma is the most common type of thyroid neoplasm specially in iodine-sufficient areas. Exposure to external radiation (medical or environmental) serves as a risk factor for development of papillary thyroid cancer. PTC is also the most common thyroid tumor in children. Women are more commonly affected with the mean age of presentation being 30 to 40 years. It is usually associated with excellent prognosis especially in young female patients.

Patients are mostly euthyroid and present with a slow-growing painless mass in the neck. Papillary thyroid cancers can metastasize early to cervical lymph nodes, especially in children and young adults. At times it may be the only presenting complaint. "Lateral aberrant thyroid" is a misnomer and actually represents metastasis from a thyroid malignancy to a cervical lymph node and not ectopic thyroid tissue. Distant metastases are rare at initial presentation, but may develop in up to 20% of patients. It is most commonly found to involve the lungs, followed by bone, liver, and brain.

2. **Pathology:** The diagnosis of papillary thyroid carcinoma is made on HPE owing to the presence of specific pathological findings such as presence of papillary architecture, calcified clumps of sloughed off cells called psammoma bodies, and characteristic nuclear features (e.g. nuclear chromatin, nuclear orientation, nuclear grooving) and intra nuclear cytoplasmic inclusions called Orphan Annie nuclei.

Papillary carcinomas are often multifocal. Tumor multifocality may be detected in up to 85% of cases on histopathological examination. It is associated with an increased risk of cervical nodal metastases.

Tall cell, insular, columnar, diffuse sclerosing, clear cell, trabecular and poorly differentiated types are some of the other variants of papillary carcinomas. They account for about 1% of all papillary carcinomas and are often associated with a worse prognosis.

Papillary carcinomas ≤ 1 cm without capsular or angioinvasion and without lymph node metastases are referred to as minimal or occult/microcarcinoma. These tumors are nonpalpable and often found to be incidental findings at operative, histologic, or autopsy examination. 25% of patients with these tumors have associated occult lymph node metastases.

3. Prognosis: Papillary carcinomas have an excellent prognosis with a 10 year survival rate between 80- 95% . Several prognostic scores have been devised that classify patients into high risk and low risk groups and thereby help in deciding management. These include:

- **AMES scoring:** Age at presentation (>40yrs males, >50 in females), presence of Metastases, Extrathyroidal spread, Size of tumor (>5cm)
- **AGES scoring:** Age at presentation, histological Grade of tumor, presence of Extrathyroidal invasion and metastasis and tumor Size
- **MACIS:** (post operative scoring system)- presence of Metastases, Age of presentation, Completeness of resection, extra thyroidal Invasion and Size of lesion

4. Follicular Carcinoma

- **Clinical Features:** Follicular carcinomas are more commonly encountered in regions where iodine deficiency is prevalent and accounts for 10% of thyroid cancers.

Women are more commonly affected and the mean age at presentation is 50 years old. They usually present as solitary thyroid nodules. There may be a history of rapid increase in size, and in some cases a history of long-standing goiter. Pain is rare. Pain can occur if there is hemorrhage into the nodule. Cervical lymphadenopathy is uncommon at initial presentation (about 5%), although distant metastases to the lung, bones (scalp, sternum) may be present.

- **Pathology:** On microscopic examination follicular carcinomas are diagnosed on the presence of trabecular or solid pattern of follicles with capsular and/or vascular invasion. Nuclear features seen in papillary carcinoma are absent. However, nuclear atypia and mitotic figures may be present. Capsular and vascular invasion are difficult to discern on cytology, hence the diagnosis of follicular carcinoma requires histopathological examination.
- **Prognosis:** Survival rates of patients with follicular carcinomas is slight lower than that of papillary carcinomas and ranges between 70-95% at 10 years. Certain subtypes such as widely invasive follicular carcinomas have poorer survival rates (25-45% at 10 years) that match poorly differentiated carcinomas.

5. Diagnosis: Diagnosis of well differentiated thyroid cancers is made by a combination of imaging and cytological assessment of the lesion.

- **Ultrasonography of Thyroid Gland:** Prior to tissue diagnosis via fine needle aspiration, an ultrasound of the thyroid gland is performed to assess gland size; size, location and sonographic characteristics of any nodule(s)- composition(solid or cystic, echogenicity, margins, presence/absence and type of microcalcifications, nodule vascularity; the presence or absence of any lymph nodes in the central or lateral compartments of the neck. Malignant nodules are usually hypoechoic with irregular, infiltrative margins, often taller than wider in shape and rim microcalcifications. USG elastography can also be used to help differentiate between benign and malignant lesions. It evaluates tissue stiffness and malignant nodules are generally harder than benign lesion and thus get less deformed on elastography that allow them to be detected.

Features on sonography that are highly suspicious for malignancy-

- Solid hypoechoic nodule or solid hypoechoic component of a partially cystic nodule with one or more of the following feature:
- irregular margins (infiltrative, microlobulated)
- microcalcifications
- taller than wide shape
- rim calcifications with small extrusive soft tissue component
- evidence of extra thyroidal extension.

The estimated risk of malignancy in nodules with such features is >70-90%

USG features of lymph nodes that are predictive of malignant involvement:

Sign	Reported sensitivity %	Reported specificity %
Microcalcifications	5-69	93-100
Cystic aspect	10-34	91-100
Peripheral vascularity	40-86	57-93
Hyperchogenicity	30-87	43-95
Round shape	37	70

- **Fine Needle Aspiration Cytology:** Fine needle aspiration of thyroid is used to determine the pathological type of nodule and to differentiate between benign and malignant nodules. It is a highly sensitive and specific method for evaluation of malignant nodules. For nodules that are difficult to palpate, in multinodular goitres and in solid-cystic nodules USG guidance can be used during FNAC. Optimum cytology specimens are those which have at least six follicles each containing at least 10 to 15 cells from at least two aspirates. FNAC smears of malignant nodules show neoplastic cells with high nuclear cytoplasmic ratio, crowded oval nuclei with intra nuclear cytoplasmic inclusions. It is difficult for an FNAC to diagnose a follicular carcinoma from a follicular neoplasia as carcinoma is marked by capsular invasion which is difficult to make out on FNAC alone. Hence such lesions are categorised as follicular neoplasms or suspicious for follicular neoplasm(SFN).

The Bethesda system for reporting Thyroid Cytopathology: Diagnostic Categories and risk of Malignancy

Diagnostic category	Estimated risk of malignancy by Bethesda system %	Actual risk of malignancy in nodules surgically excised % median (range)
Non diagnostic or unsatisfactory	1-4	20
Benign	0-3	2.5
Atypia of undetermined significance	5-15	14
Follicular neoplasm or suspicious for follicular neoplasm	15-30	25
Suspicious for malignancy	60-75	70
Malignant	97-99	99

- Preoperative use of cross-sectional imaging studies such as CECT, MRI can be used in addition to ultrasonography for patients with clinical suspicion of advanced disease or clinically apparent multiple or bulky lymph node involvement. Routine preoperative ¹⁸FDG-PET scanning is however not recommended.
- Preoperative vocal cord status assessment via indirect laryngoscopy, where required.
- Routine preoperative measurement of serum thyroglobulin(Tg) or anti-Tg antibodies is not recommended.

III. SURGICAL TREATMENT OF WELL DIFFERENTIATED THYROID CANCERS

The choice of surgical procedure that can be used for a patient, depends mostly on tumor size and presence or absence of cervical lymph nodes. Hemithyroidectomy/Lobectomy involves the removal of an entire lobe of the thyroid along with the isthmus. Near total thyroidectomy involves removal of entire thyroid tissue except for some amount of tissue near the ligament of Berry to avoid recurrent laryngeal nerve injury. The amount of tissue left behind should ideally be <1 gram. Total thyroidectomy includes removal of the entire thyroid gland leaving behind no thyroid tissue. Bilateral parathyroid glands are either preserved or reimplanted in forearm (if accidentally removed/ blood supply disrupted).

Near total or total thyroidectomy with removal of primary tumor in its entirety, with therapeutic central and/ or lateral cervical lymphadenectomy is recommended for patients with large sized tumors (>4cm) or clinically apparent lymph node involvement (clinical N1). Total thyroidectomy is also the procedure of choice in patients with gross extra thyroidal extension (clinical T4) or with gross extra thyroidal extension of tumor.

Total thyroidectomy facilitates follow up of such patients by using serum thyroglobulin levels and radioiodine uptake scans to detect residual thyroid tissue in the postoperative period.

For patients with nodules that are >1 cm and <4 cm without any extrathyroidal extension, and without clinical evidence of any lymph node metastases (cN0), the initial surgical procedure can either be a near-total or total thyroidectomy or lobectomy.

For low risk papillary and follicular carcinomas lobectomy of the side with the affected nodule alone may suffice.

1. Lymph Node Disease: For patients with clinically involved central (level VI) nodes (USG, intra op findings) or lateral cervical nodes (biopsy proven) a therapeutic central compartment and/or lateral compartmental lymph node dissection should be performed.

Prophylactic central-compartment neck dissection (ipsilateral or bilateral) is considered in patients with papillary thyroid carcinoma who have advanced primary tumors (T3/T4) or clinically involved lateral neck nodes (c N1b) without involvement of central group of lymph nodes.

Thyroidectomy without prophylactic central neck dissection is appropriate for small (T1 or T2), noninvasive, clinically node-negative PTC (cN0) and for most follicular cancers.

In patients who have undergone lobectomy/ hemithyroidectomy for a solitary thyroid nodule without the diagnosis of malignancy, a completion thyroidectomy coupled with a therapeutic central compartment lymph node dissection should be performed if tumor has high risk features, large size or extra thyroidal extension on histopathological examination.

Post operative pathological assessment and staging:

ATA low risk

2. Papillary Thyroid Cancer (With all the following)

- No local or distant metastases
- All macroscopic tumor has been resected
- No tumor invasion of loco-regional tissues or structures
- The tumor does not have aggressive histology (e.g tall cell ,hobnail variant, columnar cell carcinoma)
- If I¹³¹ is given, there are no RAI-avid metastatic foci outside the thyroid bed on the bed on the first post treatment whole body RAI scan
- No vascular invasion
- Clinical N1 or ≤ 5 pathologic N1 micrometastases (<0.2 cm in largest dimension)

3. ATA Intermediate Risk

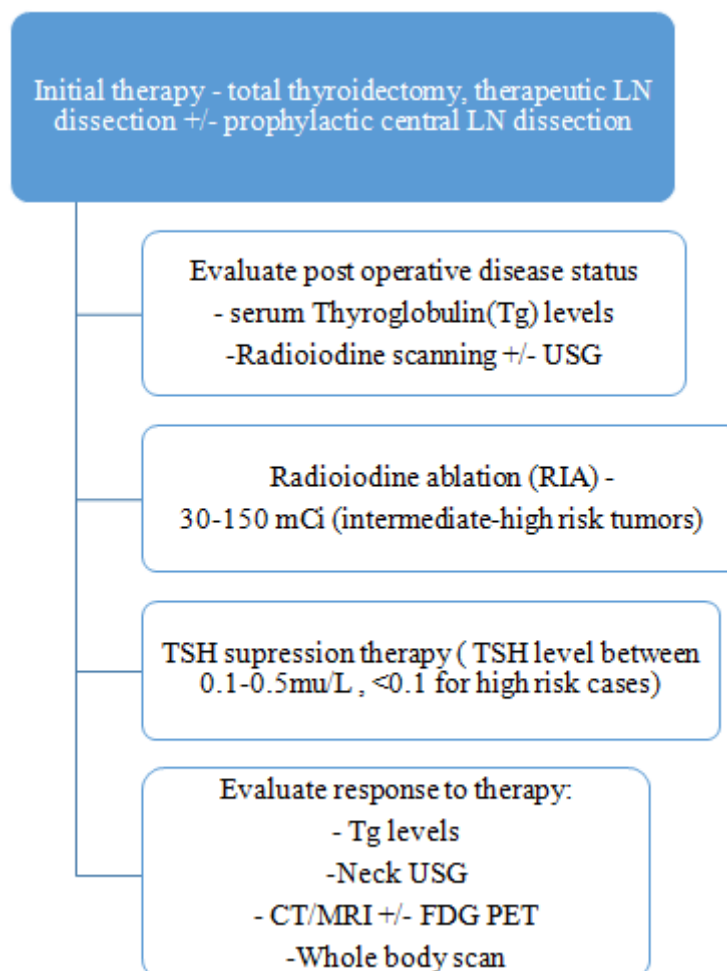
- Microscopic invasion of tumor into perithyroidal soft tissues
- RAI avid metastatic foci in the neck of the first post treatment whole body RAI scan
- Aggressive histology (e.g tall cell, hobnail variant, columnar cell carcinoma)
- Papillary thyroid cancer with vascular invasion

- Clinical N1 or >5 pathological N1 with all involved lymph nodes < 3 cm in largest dimension
- Multifocal papillary microcarcinoma with extra thyroidal extension.

4. ATA High Risk

- Macroscopic invasion of tumor into perithyroidal soft tissue (gross ETE)
- Incomplete tumor resection
- Distant metastases
- Postoperative serum thyroglobulin suggestive of distant metastases
- Pathologic N1 with any metastatic lymph node > 3 cm in largest dimension.
- Follicular thyroid cancer with extensive vascular invasion (>4 foci of vascular invasion)

5. Postoperative Therapy



- **For Tumors with Excellent Response to Therapy:** Maintain TSH between 0.1-0.5 mu/L for 5 years with annual thyroglobulin levels for 5 years.

For tumors with partial/ indeterminate response maintain TSH<0.1 mu/L for indefinite period, unless contraindicated.

IV. POSTOPERATIVE MANAGEMENT

Disease status (i.e., the presence or absence of persistent disease) should be evaluated in the post operative period to decide whether additional treatment (e.g., RAI, surgery, or other treatment) is required.

- 1. Postoperative Serum Thyroglobulin:** Post operative serum thyroglobulin levels can be helpful in detecting persistent disease, presence of remnant tissue and also in predicting disease recurrence. Ideally serum thyroglobulin levels (Tg) should reach its lowest values by 3-4 weeks postoperatively. Elevated levels in the post operative period are suggestive of remnant disease. However, the optimal cut off level that can suggest remnant or recurrent disease is still under study. Patients with a postoperative Tg >1-2ng/mL have been found to have an increased risk of recurrence, despite total thyroidectomy and RAI remnant ablation. Postoperative Tg levels have also been found to be an independent predictor of persistent or recurrent disease. High postoperative stimulated Tg values (>10–30 ng/mL) were also associated with poorer survival.
- 2. Radioiodine Ablation (RAI):** Following operative therapy (total thyroidectomy) and serum thyroglobulin assay, remnant tissue can be estimated via radioiodine scans. Often I¹²³ is used due to its low half life, or I¹³¹ in dosages of 1-3 mCi. This helps to assess the amount of remnant tissue, which can then be ablated using I¹³¹. Patients are kept on a low iodine diet for 1-2 weeks prior to ablation to enable better uptake by remnant tissue. If patient is on thyroxine, it is withdrawn 6 weeks prior to screening radioiodine scan, until TSH \geq 30 mIU/L. Another option is to use 3 doses of recombinant TSH to achieve hypothyroid state to promote uptake during screening scan.

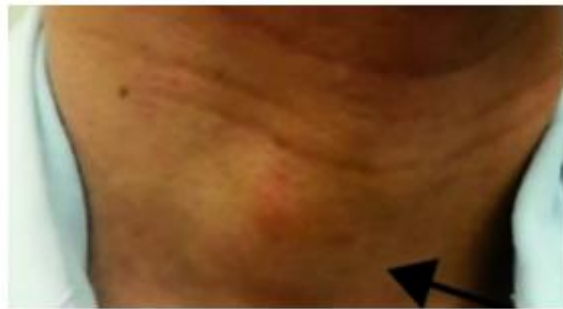
RAI is routinely used for high risk tumors and can be considered for intermediate tumors with high risk features- large size, presence of central, lateral or mediastinal nodes, age >45 yrs. It is generally not performed for low risk tumors or in patients who have undergone lobectomy or total thyroidectomy with unifocal or multifocal papillary microcarcinoma, in absence of other adverse features.

When RAI ablation is performed after total thyroidectomy, especially in low or intermediate risk disease with low risk features (e.g low volume central neck nodal metastases with no other gross residual disease or adverse pathological features) a lower dose of approximately 30 mCi (maximum dose that can be given without dosimetry) is preferred over higher doses. Higher dosages of 100-200 mCi maybe needed in patients who have undergone subtotal thyroidectomy or in where a larger remnant is suspected. In patients with lymph nodal disease doses upto 250mCi may be required.

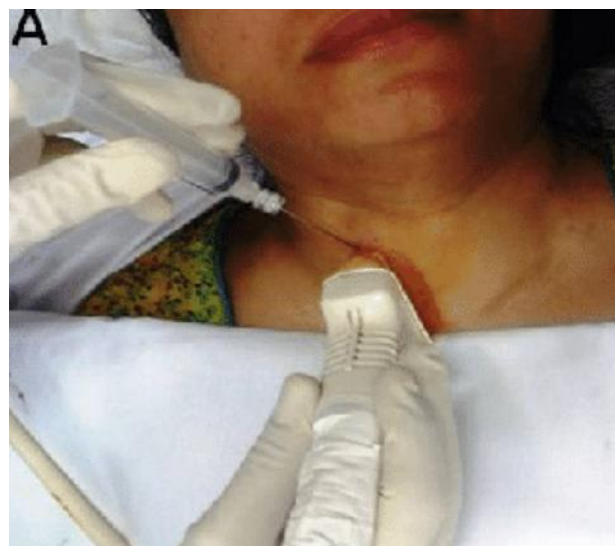In certain patients, no hot spot can be detected on a screening iodine scan despite high serum thyroglobulin levels. In such patients it is recommended that ablation be performed with a dose of 100mCi and then re-imaging be done and to repeat thyroglobulin after 2 weeks and reassess disease status.

After RAI treatment a posttherapy whole body scan is recommended to assess leftover disease.

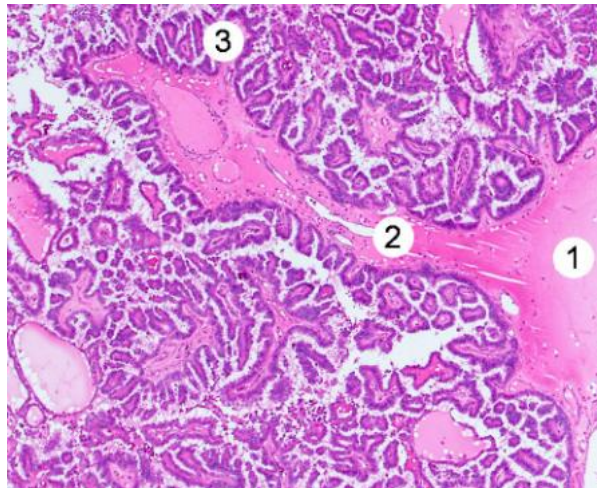
3. **TSH suppression:** TSH suppression needs to be continued in the post operative period to prevent recurrence. For high-intermediate risk thyroid cancer patients, suppressive doses of thyroxine should be given in order to keep TSH to between 0.1 mU/L - 0.5 mU/L. In low-risk patients who have undetectable serum Tg levels with or without radioiodine ablation, TSH may be maintained at the lower range (0.5–2 mU/L) while continuing surveillance for recurrence via USG and thyroglobulin levels.
- **Other Adjuvant Therapy:** Adjuvant external beam radiotherapy(EBRT) to the neck is not indicated in patients with differentiated thyroid cancers, after initial complete removal of the tumor. Routine systemic adjuvant therapy in patients with DTC (beyond RAI and/or TSH suppressive therapy using LT_4) has also not found to be useful and is hence not recommended.



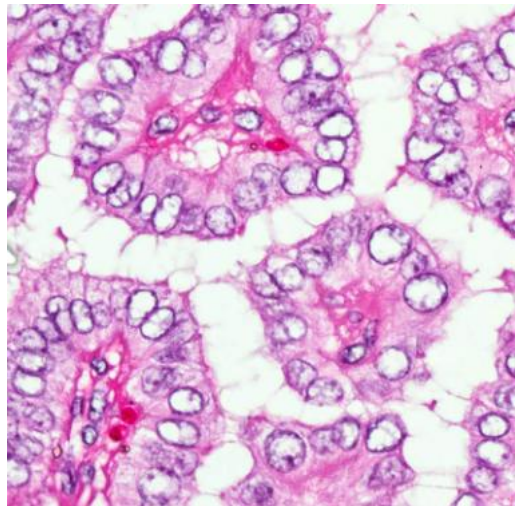
Solitary thyroid nodule of right side of neck



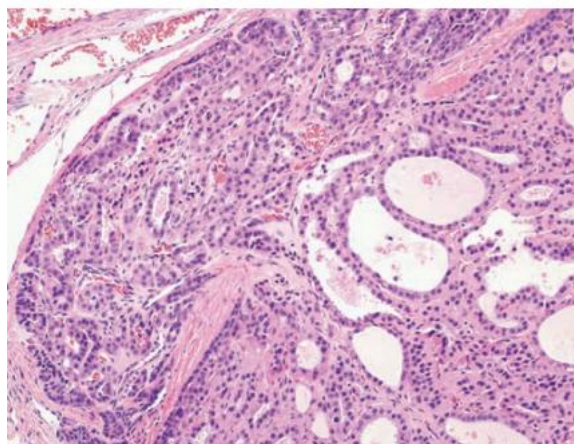
USG guided FNAC of right thyroid nodule



Papillary architecture on HPE



Orphan Annie eye intranuclear cytoplasmic inclusions



Follicular carcinoma with capsular invasion

BIBLIOGRAPHY

- [1] European Network of Cancer Registries Factsheets. https://www.encreu/sites/default/files/factsheets/ENCR_Factsheet_Thyroid_2017.pdf (12 June 2019, date last accessed).
- [2] Kitahara CM, Sosa JA. The changing incidence of thyroid cancer. *Nat Rev Endocrinol* 2016; 12(11): 646–653.
- [3] Filetti S, Durante C, Hartl D, Leboulleux S, Locati LD, Newbold K, Papotti MG, Berruti A; ESMO Guidelines Committee. Electronic address: clinicalguidelines@esmo.org. Thyroid cancer: ESMO Clinical Practice Guidelines for diagnosis, treatment and follow-up†. *Ann Oncol*. 2019 Dec 1;30(12):1856-1883. doi: 10.1093/annonc/mdz400. PMID: 31549998.
- [4] Vaccarella S, Franceschi S, Bray F et al. Worldwide thyroid-cancer epidemic? The increasing impact of overdiagnosis. *N Engl J Med* 2016; 375(7): 614–617.
- [5] Jung CK, Bychkov A, Kakudo K. Update from the 2022 World Health Organization Classification of Thyroid Tumors: A Standardized Diagnostic Approach. *Endocrinol Metab*. 2022;37(5):703-718.
- [6] Haugen BR, Alexander EK, Bible KC, Doherty GM, Mandel SJ, Nikiforov YE, Pacini F, Randolph GW, Sawka AM, Schlumberger M, Schuff KG, Sherman SI, Sosa JA, Steward DL, Tuttle RM, Wartofsky L. 2015 American Thyroid Association Management Guidelines for Adult Patients with Thyroid Nodules and Differentiated Thyroid Cancer: The American Thyroid Association Guidelines Task Force on Thyroid Nodules and Differentiated Thyroid Cancer. *Thyroid*. 2016 Jan;26(1):1-133. doi: 10.1089/thy.2015.0020. PMID: 26462967; PMCID: PMC4739132.
- [7] Schwartz's Principles of Surgery, 11e Brunnicardi F, Andersen DK, Billiar TR, Dunn DL, Kao LS, Hunter JG, Matthews JB, Pollock RE