

# GUIDED ENODONTICS

## Abstract

Contemporary dentistry primarily focuses on minimally invasive procedures as a result of emerging trends in technological advancements. Guided Endodontics is also known as Targeted Endodontic Treatment which represents one of the most accurate technology to perform complex endodontic interventions predictably. GE approach is based upon four essential elements which comprise of 3D imaging, digital devices, processing software and manufacturing tools.

Guided endodontics includes the use of two techniques: Static Navigation and Dynamic navigation. In Static Navigation approach, the optical impression is merged with the 3D data obtained from CBCT for designing of a virtual drill path prior to the clinical procedure. On the other hand, Dynamic navigation is a newer technology which utilizes stereoscopic monitoring camera to dynamically guide the operator's instruments to the exact location with in real-time.

The clinical applicability of Guided Endodontics includes the use of computer-designed guides for minimally invasive access cavity preparation, negotiation of pulp canal obliteration and calcification in order to achieve predictable and safe results. 3D guides are also gaining popularity in endodontic surgery for osteotomy and root-end resection, among the few indications.

With the continuous improvements in imaging, 3D printing, and virtual planning, the potential benefits of this technique can be used for the management of challenges in nonsurgical and surgical endodontic procedures.

**Keywords:** 3D, Digital images, TET, Guided Endodontics

## Author

**Dr. Shriya Shahu**

Assistant Professor

Ranjeet Deshmukh Dental College and  
Research Centre

VSPM's Dental College and Research  
Centre

Nagpur, Maharashtra, India

dr.shriyashahu@gmail.com

## **I. INTRODUCTION**

The realm of contemporary endodontics has metamorphosed beyond recognition as a result of quantum leap in technological advancements.

Guided Endodontics (GE), also known as Targeted Endodontic Treatment (TET) is an emerging exemplar of evolution in this domain, representing one of the most accurate technology to perform complex surgical interventions predictably. It encompasses conservative access cavity preparation with precision, safety and reliability in accordance with the modern approaches of minimally invasive endodontics.

Minimally invasive Endodontics is based on the preservation of sound coronal and radicular tooth structure especially in the cervical region, thereby reinforcing fracture resistance of endodontically treated teeth. GE facilitates preservation of pericervical dentin and offers the most conservative approach for treating complex endodontic cases.

The concept of GE originated with the improvements in tomographic imaging and 3D printing technologies. Cone beam computed tomography (CBCT) has been utilized in challenging cases wherein conventional radiographic techniques fail to provide adequate information on the morphology of the root canal and periradicular tissues. GE utilizes this three dimensional (3D) information which is integrated with the morphological profile of the teeth acquired by an intraoral scanner in for designing and printing a 3D guide for treatment.

The indications for use of TET is based upon the understanding of its characteristics and exploration of digital dentistry tools to enhance clinical applicability. These computer-designed guides are used for minimally invasive access cavity preparation, negotiation of pulp canal obliteration and calcification in order to achieve predictable and safe results. 3D guides are also gaining popularity in endodontic surgery for osteotomy and root- end resection, among the few indications.

GE has been an emerging field since the past decade, and clinical research and laboratory studies have reported high reliability and accuracy of the procedure. It may constitute a significant addition to an endodontist's arsenal in managing complexities in contemporary practices.

## **II. HISTORICAL BACKGROUND**

Non-invasive and safe targeting of specific anatomical structures is the paramount principle of three dimensional exploration. The quest for localization of discrete anatomical structures stemmed from the late nineteenth century after the advent of medical imaging.

Wilhelm Roentgen in 1895 unraveled a revolution in diagnosis and treatment planning by discovering the X-ray. Sir Godfrey Hounsfield introduced computerized axial tomography in 1970 which was the first computer tomography (CT) imaging device.

Since then drastic improvements in image receptors, beam source, and movement of detectors have revolutionized three dimensional imaging. In 1988, Mozzo et al. revolutionized 3D imaging by describing importance of volumetric CT machine and its applications in dental imaging.

Dr. Raymond Damadian marked an important milestone in 1980s by introducing magnetic resonance imaging (MRI) allowing for the detailed imaging of soft tissues.

David Roberts in 1990 conceptualized frameless stereotaxy for neurosurgery that could track surgical instruments in real time and enable continual visualization of its position on the preoperative CT or MRI. This discovery laid the foundations for inception of contemporary dynamic navigation.

Dr. Francois Duret was the pioneer in describing the fundamental principles of optical impressions. In 1984, he developed and patented the first CAD/CAM device which was named Sopha System.

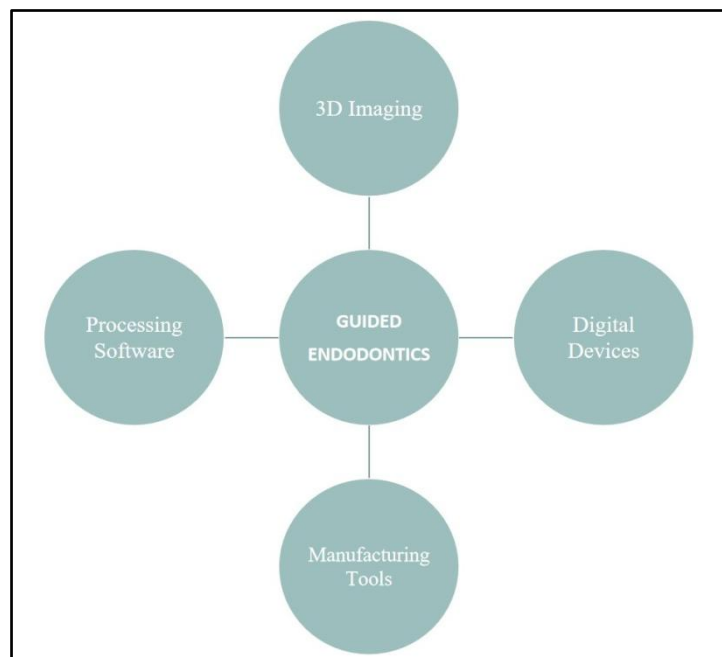
Werner Mörmann in 1987 created the first generation of Chairside CAD/CAM system CEREC (Siemens Corporation) to fabricate chairside inlays. The CEREC 2 software was developed by Siemens Corporation in 1994, and CEREC 3 was produced by Sirona Dental System in 1999.

Since then, developments in the field of scanning intraoral and extraoral images of dental hard and soft tissues have advanced drastically.

The introduction of 3D printing systems by Charles Chuck Hull in 1984 has enormously evolved the future of bioprinting tools from multimaterial 3D printers to a plethora of softwares and 3D printers currently used in the endodontic domain.

### III. COMPONENTS OF GUIDED ENDODONTICS

GE approach is based upon four essential elements which comprise the tetrad of digital dentistry. (Figure 1)



**Figure 1:** Components of Guided Endodontics

**1. 3D Imaging:** CBCT is the quintessential imaging modality used in guided endodontic procedures. The CBCT unit comprises of a rotating gantry, an X-ray source with a pyramidal- or cone-shaped beam of ionizing radiation, and a detector moving around a fixed fulcrum within the field of interest. After exposure, mutliplanar 2D images are acquired in an arc of at least 180°. These images are then reconstructed for visualization of 3D data set. The process of image formation consists of three stages

- Acquisition of image
- Image Reconstruction
- Image display

The data obtained from the 3D scan is saved in the format of Digital Imaging and Communications in Medicine (DICOM). A smaller Field of View is recommended for CBCT utilized for endodontic purposes.

The type of CBCT device utilized for obtaining data majorly affects the quality of the acquired image. It is of paramount importance to record the images in high definition mode to allow better visualization of root canal anatomy. For guided treatments, open mouth CBCT are advised to allow better evaluation of anatomy and prevention of superimposition.

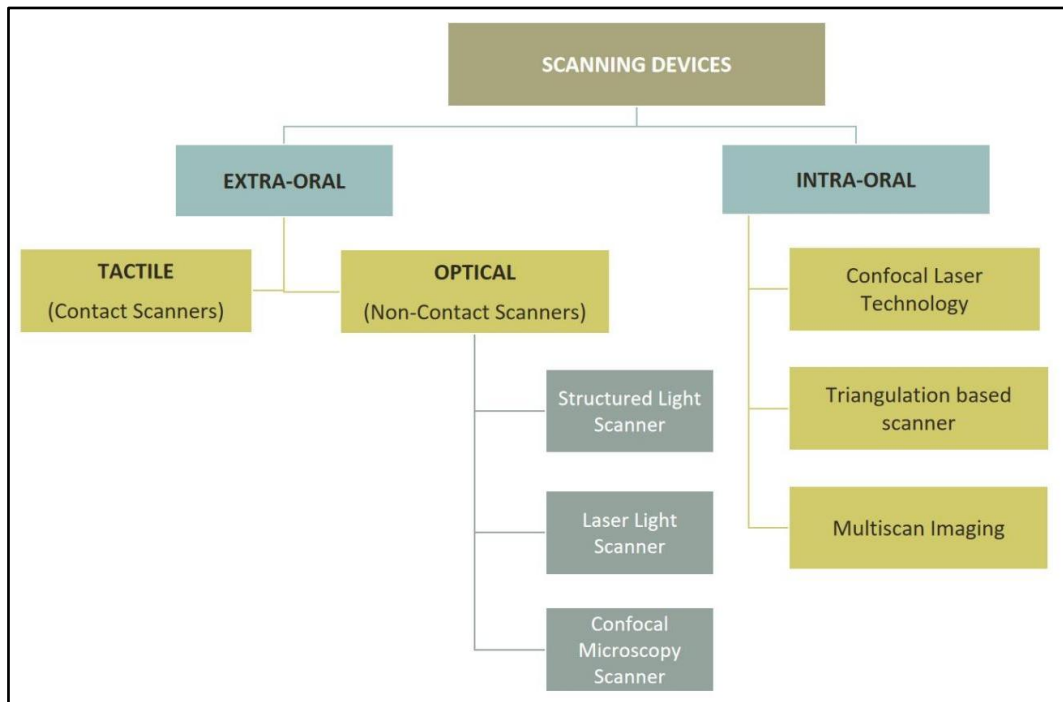
**2. Digital Devices:** Digital devices including digital cameras, intraoral and extraoral scanners, Digital Impression Systems and CAD/CAM systems are employed for successful acquisition of accurate virtual images.

- **Digital Scanner:** In contemporary dental practices, optical impressions taken with digital scanners are now replacing the conventional tray and impression material techniques. Various scanners are presently available based on the data capture principles. (Figure 2)

Extraoral tactile scanners are based upon attaining mechanical contact between the detection unit and the object to be scanned. On the other hand, optical scanners utilize electromagnetic wave, specifically light in a non-contact mode to detect surface details.

The digital impression data obtained from the scanners is imported into stipulated softwares for processing, designing and planning the 3D models with powerful milling machines.

The CBCT data set in DICOM file is exported and combined as a Standard Tessellation Language (STL) file using intraoral digital impression system. The STL file contains geometrical information of an object by illustrating it in terms of dense connected triangles based on initial resolution and mathematical algorithms. Digital impression systems are pivotal for designing the treatment plan and fabrication of a guide for better scrutiny and visualization of access cavity during endodontic procedures.



**Figure 2:** Types of Scanning Devices

- **CAD/CAM:** The terminology CAD/CAM is an acronym that stands for Computer-Aided Design (CAD) and Computer-Aided Manufacturing (CAM). These systems comprise of various hardware and software used for data acquisition as well as designing and manufacturing of restoration. They serve the following functions:
    - 3D generation of digital data set
    - Design manipulation for generating the manufacturing data set
    - Fabrication of dental restorative works using a digitally controlled system
    - **Indirect CAD/CAM:** The workflow for indirect technique is based on scanning gypsum models and cast made from conventional impression. These systems work with laboratory scanners.
    - **Direct CAD/CAM:** The workflow commences by scanning the prepared teeth directly with intraoral scanners.
- 3. Processing Software:** Software programs are used for planning and designing digital models prior to the process of 3D printing.

With technological advancements in software programs and availability of open-source inexpensive programs, replication of anatomical structures, image rendering and designing has become more predictable.

The ease of inter-operability between imaging devices, 3D virtual planning systems and 3D printers permits efficient fabrication of 3D guides by conversion of volumetric data in DICOM format to STL file format representing the virtual 3D surface shape.

Data obtained from optical intra-oral/plaster model scans and is imported as STL formats in 3D virtual planning systems. The resultant 3D image is then merged with CAD software to create a blueprint of the 3D printed object.

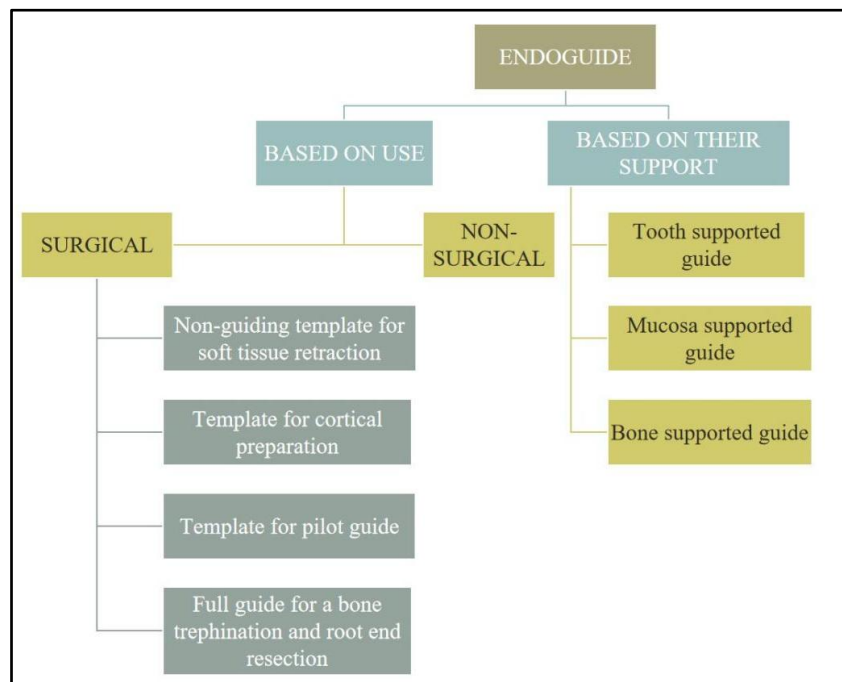
**4. Manufacturing Tools:** Additive manufacturing synonymous with 3D Printing, has created a revolution in the diagnostic and treatment protocols in dentistry by reconstructing digital models using computer-aided softwares. The 3D printers are based upon the following basic mechanisms

- Fused deposition modeling (FDM)
- Selective laser sintering (SLS)
- Stereolithography (SLA)/Direct Light Processing (DLP)
- Poly-jet printing
- Bioprinting

The present evidence of literature suggests that integration of additive manufacturing in the endodontic clinical management has a strong prospective of achieving precision in dentistry.

#### IV. ENDODONTIC GUIDES

Three dimensionally printed guide or template for endodontic purpose is called Endoguide or endodontic guide. It is a template fabricated to guide drills into pre-planned positions for better localization and exploration of root canal orifices, or bone trephination and root end re-section in endodontic surgeries. Endoguides can be classified depending upon the specific use and type of support established during the procedure. They may be classified as follows: (Figure 3)



**Figure 3:** Classification of Endoguides

- 1. Nonguiding 3D Printed Template to Help Access:** These aid in defining the surgical area and retraction of soft tissues to enable access to the surgical site.
- 2. 3D printed Template for Cortical Preparation:** This guide helps in defining the exact site of cortical bone penetration for root-end resection and in localizing the osteotomy site over the apical portion of the root.
- 3. Pilot Guide:** This guide helps in initial drilling through the template and the resulting bony cavity. It provides guidance to subsequent drills that are applied without the template.
- 4. Full Guide for a Bone Trephine:** This guide facilitates performing both the osteotomy and the root-end removal in the same session.

Following points should be considered while designing the endoguide:

- **Offset of the Guide:** 0.15mm is considered ideal
- **Thickness of the guide:** 3.5 mm is recommended
- **Coverage of the Guide:** Including the adjacent teeth in the design is necessary for establishing stability
- **Thickness of Connector:** Affects the overall stability of the automatically connected parts of the 3D guide

## V. TYPES OF GUIDED APPROACH

3D guided approach for endodontic purposes can be obtained in the following ways: (Table No.1)

- Static Navigation (SN)
- Dynamic Navigation (DN)

In SN approach, the optical impression is merged with the 3D data obtained from CBCT for designing of a virtual drill path prior to the clinical procedure.

On the other hand, DN is a newer technology which utilizes stereoscopic monitoring camera to dynamically guide the operator's instruments to the exact location with precision (for a stipulated procedure ex: localization of orifices, apicoectomy, etc.) in real-time. Both the techniques present correspondent advantages and disadvantages. (Table No. 2)

**Table 1: Characteristics of Static and Dynamic Approach in Guided Endodontics**

BASIS	STATIC NAVIGATION	DYNAMIC NAVIGATION
PRE-OPERATIVE REQUISITES	CBCT and Diagnostic Optical Impression	CBCT
ARMAMENTARIUM	Surgical Guide/ Endoguide, Surgical Motor, Dental Operating Microscope and Surgical instruments	Hand-piece attachment, patient jaw attachment, stereoscopic camera and scanner, computer with navigation software
WORKING PROTOCOL	Optical Impression, CBCT Imaging, Superimposition of data and digital planning, 3D template fabrication, Try-on, Guided procedure	3D real time planning, tracing of specific anatomical landmark, Placement of 3D guide, Drilling dynamically
OPERATOR ACCESSIBILITY	Limited	Good
MODIFICATION OF TREATMENT PLAN	Not possible after fabrication of the 3D guide	Possible to modify treatment plan at any time of the procedure

**Table 2: Comparison of Static and Dynamic Navigation Techniques**

BASIS	STATIC NAVIGATION	DYNAMIC NAVIGATION
ADVANTAGES	<ul style="list-style-type: none"> <li>• Accurate details and reproduction of scan</li> <li>• Printing of complex geometric shapes possible</li> <li>• Reduction of production-related material loss</li> <li>• Produces single objects in small quantities faster and at low cost</li> </ul>	<ul style="list-style-type: none"> <li>• CT scanning, planning, and surgery in a single appointment</li> <li>• Errorless and superior in accuracy</li> <li>• Reduces potential risk of damaging critical structures</li> <li>• Greater flexibility offered to the operator</li> <li>• Adjustments dictated by clinical situation can be made to the working plan at any time</li> </ul>
DISADVANTAGES	<ul style="list-style-type: none"> <li>• Possibilities of inaccuracy in image registration and 3D printing</li> <li>• Larger deviations, Over-penetration of drill, Trepine fracture</li> <li>• 3D guides are not re-useable</li> <li>• Resin guides cannot be heat sterilized</li> <li>• Resin guides may cause inflammation and irritation on contact</li> <li>• Lack of long term success</li> </ul>	<ul style="list-style-type: none"> <li>• More steps &amp; Learning curve</li> <li>• Longer surgical time</li> <li>• Entire procedure is supervised by computer software, time lag for processing commands in computer might lead to iatrogenic errors.</li> <li>• Possible inaccuracies due to improper registration</li> </ul>

## VI. WORK FLOW FOR GUIDED ENDODONTIC APPROACH

In addition to planning the protocol of the 3D guided procedure, the endodontist is mainly responsible for verification of various aspects that may cause in interference with the final result of treatment. A virtual planning report is sent by the Planning Centers that provide information about the 3D scans, trajectory of the drill, dimensions of 3D guide. It is of utmost importance to understand the digital workflow to eliminate possible failures while performing the endodontic procedure. (Figure 3 and Figure 4)



- Acquisition of Preoperative CBCT images (stored as DICOM files)
- Capturing of surface profile using a 3D-intra-oral
- Surface scanner (Stored as STL files)
- Matching of Scans and uploading CBCT Data into a planning software
- Creation of a virtual image of a commercially available bur and virtual sleeve for guidance
- Designing of Virtual Template
- Creation of 3D template by milling
- Fabrication and integration of designed sleeves in 3D template using Computerized Numerical Control (CNC) technology
- Attachment of 3D template to the teeth and verification of reproducible fitting
- Setting of drill mark through the template sleeves to indicate the region of access cavity.
- Removal of enamel and dentin using a diamond bur
- Gaining access to pulp chamber with the specific bur
- The final position is reached when the bur hits the mechanical stop of the sleeve

**Figure 3:** Workflow for Static Guided Endodontic Procedures

- 1. Pre-operative Planning**
  - Acquisition of pre-operative CBCT Scan
  - Plan endodontic treatment on CBCT file in the dynamic navigation software
- 2. Trace Registration**
  - Mounting jaw/head tracker on the patient for DNS in real time
  - Registering the CBCT scan to the teeth and/or bone by calibrated tracer
  - Matching of CBCT images with the teeth
- 3. Calibration**
  - Mapping the drill tip to the Drill Tag
  - Calibration of drilling axis prior to the start of the procedure
  - Calibration of drill tip location after each drill change
- 4. Tracking:**
  - Mapping the Drill Tag (Handpiece attachment) to the Jaw Tag (Jaw attachment)
  - Dynamic Navigation is performed throughout the operation by the optical tracking system

**Figure 4:** Workflow for Dynamic Navigation in Endodontic Procedures

## VII. INDICATIONS OF GUIDED ENODONTICS

- 1. Minimally Invasive Endodontic Access Cavities:** Ultra-conservative access cavities are gaining popularity in routine endodontic practice as they preserve maximum sound tooth

structure, and reduce instrument stresses during procedure. GE facilitates conservation of the crucial pericervical dentin and performing minimally invasive access opening according to the projection of root canals.

- 2. Pulp Canal Obliterations and Calcified canals:** Pulpal calcifications and root canal obliteration predispose many clinical challenges for endodontists. Use of high-speed drills in association with 3D guides curtails the operation time, and reduces the risks of endodontic mishaps in obliterated canals.
- 3. Fiber Post Removal:** In cases requiring endodontic retreatment, the practitioner's experience quantitatively affects dentin removal around the post. Problems associated with detection of tooth colored post systems may cause widening of the radicular portion of canal due to extra removal of dentin. GE provides satisfactory and faster results in removal of fiber posts by providing higher precise and accuracy.
- 4. Intraosseous Anaesthesia:** Dynamic Navigation Systems (DNS) allow for precise delivery of local anaesthetic agent with minimal or no root perforation in intraosseous anaesthetic techniques. Accuracy in drilling of the injection sites is possible due to precise entry, horizontal deviation, and 3D tip deviation of DNS.
- 5. Endodontic Surgeries:** 3D-printed static aids have been successfully utilized for endodontic surgical procedures including osteotomy, root-end resections and apicoectomy. GE offers a minimally invasive approach for endodontic microsurgery by avoiding damage to anatomical structures, thus providing added benefits of postoperative patient comfort.

## VIII. FAILURES AND LIMITATIONS

The high cost of the digital system is the major limitation of guided endodontic systems. The maintenance and latest upgradation of system might be a financial concern for the dental practitioner. Since each system has its own peculiar planning software, it may be difficult to use any advanced software of another system due to possible incompatibility. Therefore, a significant learning curve is associated with this approach.

There is generally a wide variation in the radial dimensions of root canals, more specifically observed in calcified cases due to narrowing of canal diameter. The visualization of smaller diameters of calcified canals in CBCT is uncertain as the voxel size is larger. Thus the limited spatial resolution of CBCT may cause hindrance in the navigation of pulp obliteration. Another limitation is presence of metallic restorations of teeth that may lead to artifacts on acquired radiographic images.

Static guided approach is associated with the risk of over penetration of drill. Although this limitation can be overcome by using trephines with stop, the possibility of trephine fractures cannot be over-ruled. Also, trephine-based techniques result in a cylindrical shape of the osteotomy canal which might complicate debridement and cleaning of the site. Static guides work well only for the straighter portion of root canals, the access to root canal curvatures is questionable.

Despite the novelty of guided endodontic approach, the data on accuracy, complication rates, and reliance for long-term success is still lacking. Thus, further research is required in this direction.

## IX. FUTURISTIC TRENDS

- 1. 3D Printing in Auto-Transplantation:** The clinical application of a Computer-aided rapid prototyping (CARP) was first introduced in 2001 for auto-transplantation. This technique permits better simulation of the recipient bone contour using actual-sized CARP models of donor teeth and recipient alveolar bones pre-operatively. 3D-printed template make the procedure faster, predictable, and convenient.
- 2. Bioprinting:** 3D printing can be a promising technology that may allow designing of anatomically accurate scaffolds, which can be populated with various cells including stem cells from oral tissues, bone marrow stem cells, adipose tissue stem cells (ATSCs) etc.
- 3. Haptic Virtual Reality in Endodontics:** Haptic VR simulators have been recently introduced as training devices in the dental curriculum for enhancing clinical skills. They can be used as teaching aids for endodontic treatments by providing realistic simulation of a wide variety of nonsurgical and surgical procedures.

## X. SUMMARY

GE is an emerging technique in the field of endodontics offering high predictability of treatment outcomes with lowered risks of iatrogenic damage. It is a promising approach for performing minimally invasive procedures with accuracy and provides additional benefit of patient's comfort and reduced chairside time.

GE procedures utilizing either static or dynamic navigation approach seem to be a safe and precise method for detecting calcified root canals, performing endodontic re-treatments and surgical procedures.

With the continuous improvements in imaging, 3D printing, and virtual planning, the potential benefits of this technique can be used for the management of challenges in nonsurgical and surgical endodontic procedures.

## REFERENCES

- [1] Decurcio DA, Bueno MR, Silva JA, Loureiro MAZ, Damião Sousa-Neto M, Estrela C. Digital Planning on Guided Endodontics Technology. *Braz Dent J.* 2021 Sep-Dec;32(5):23-33.
- [2] Kulinkovych-Levchuk K, Pecci-Lloret MP, Castelo-Baz P, Pecci-Lloret MR, Oñate-Sánchez RE. Guided Endodontics: A Literature Review. *Int J Environ Res Public Health.* 2022 Oct 26;19(21):13900.
- [3] Connert T, Weiger R, Krastl G. Present status and future directions - Guided endodontics. *Int Endod J.* 2022 Oct;55 Suppl 4(Suppl 4):995-1002.
- [4] Ribeiro D, Reis E, Marques JA, Falacho RI, Palma PJ. Guided Endodontics: Static vs. Dynamic Computer-Aided Techniques-A Literature Review. *J Pers Med.* 2022 Sep 15;12(9):1516.
- [5] Moreno-Rabié C, Torres A, Lambrechts P, Jacobs R. Clinical applications, accuracy and limitations of guided endodontics: a systematic review. *Int Endod J.* 2020 Feb;53(2):214-231.
- [6] Lio F, Mampieri G, Mazzetti V, Leggeri A, Arcuri L. Guided endodontic microsurgery in apicoectomy: a review. *J Biol Regul Homeost Agents.* 2021 May-Jun;35(3 Suppl. 1):47-55.

- [7] Anderson J, Wealleans J, Ray J. Endodontic applications of 3D printing. *Int Endod J.* 2018 Sep;51(9):1005-1018.
- [8] Panithini DB, Sajjan GS, Kinariwala N, Medicharla UD, Varma KM, Kallepalli M. Real-time guided endodontics: A case report of maxillary central incisor with calcific metamorphosis. *J Conserv Dent.* 2023 Jan-Feb;26(1):113-117.
- [9] Kinariwala N, Samaranayake L, editors. *Guided endodontics.* Springer International Publishing; 2021.
- [10] Martinho FC, Griffin IL, Corazza BJ. Current Applications of Dynamic Navigation System in Endodontics: A Scoping Review. *European Journal of Dentistry;* 2022.