

# **ROLE OF BACTERIOPHAGES IN BURN WOUND HEALING – A RAY OF HOPE FOR ELIMINATING MULTIPLE ANTIBIOTIC RESISTANT BACTERIA**

## **Abstract**

Many cases of successful chronic nonhealing wounds healing had been done by us with bacteriophages. My clinical evidence of healing even extensive infected burn wound with bacteriophages is promising. We successfully treated a two years old child with multiple drug-resistant infected burn wounds with bacteriophages without any side effects. No contracture occurred, and no plastic surgical intervention was required. However, complete healing took place in 4 to 5 months. Bacteriophage the virus killing bacteria treatment is good weapon for eliminating multiple antibiotic resistant bacterial suppuration. Survival of extensive burn patients can be improved upon by use of bacteriophages.

Resistant superbugs can be destroyed by bacteriophages. The use of bacteriophages in preventing burn wound sepsis has a great ray of hope. Our using of bacteriophages topically on large antibiotic resistant bacterial infected burn wounds clinically given good result. Our clinical evidence is providing a ray of hope for eliminating burn wound infection successfully in future.

**Keywords:** Bacteriophages, antibiotics, multiple drug-resistant bacteria, burns

## I. BACK GROUND

River Ganga which we all are devoted to it as it is cradle of most ancient civilization is also important for its sacredness due to bacteriophages that is virus killing infective bacteria specifically without harming the human cells and is known to contribute in maintaining purity of Ganga water which is never spoiled and even by tradition given with tulsi leaves to dying people. My research is great revolution for the first time in treating very extensive septic burn patient who are resistant to almost all common antibiotics who have more than 90 percent incidence of mortality has been treated successfully with bacteriophages by us that is virus killing antibiotic resistant bacteria extracted from holy river Ganga done in Varanasi the place of our beloved MP and nation Prime Minister Modi ji. This is first time reported by us on application of Ganga water bacteriophages healing power on extensive infected burn patient without application of antibiotics and surgery. It is pointing to coming great revolution in horizon where it will overtake the role of antibiotics which are having side effects. However bacteriophages use do not cause side effects. This will have positive impact on economy as it is natural resource and easily available as there are 600 bacteriophages for one bacteria and so plenty available to be explored and is cheap as not much sophisticated technology required for extraction from holy Ganga water. The holiness of Ganga water is due to bacteriophages.

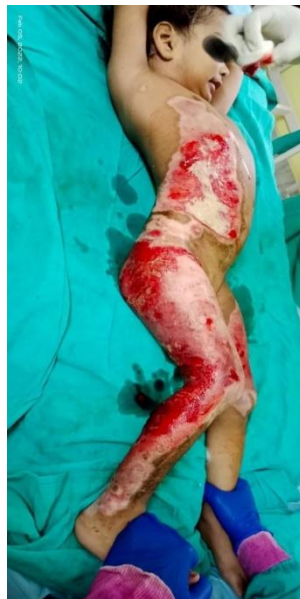## II. INTRODUCTION

Innovation is the hallmark of plastic surgeons. Bacteriophages spare human eukaryotic cells but eliminate bacterial cells for which they are intended. It is target specific and it has been found that there are more than 600 bacteriophages in nature against one bacteria and so dearth of shortage even if one gets resistant which happens sometimes and that too often after 3 weeks of topical treatment. Russia, Georgia and Poland have been using this. Soviet army had used this in past prophylactically for war wounds. We also have done lot of cases of non healing chronic wounds with bacteriophages and found encouraging clinical results in our place. Our clinical evidence of topical application of bacteriophages on extensive multi-drug resistant(MDR) bacterial infected burn wounds has been done for first time and reported as letter to editor in the literature[1].

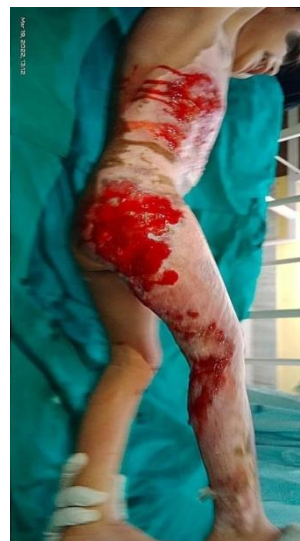Our clinical experience with bacteriophage therapy in a fifty percent infected one-month-old thermal burn wound in a child of 2 years of age has given very encouraging results [Fig. 1].The patient had a burn wound right lower limb almost circumferentially, on the left thigh and right part of the anterior abdomen and partially healing chest. There is full thickness loss with slough mostly in the abdominal region and rest having partial to deep burn wound. The initial burn wound culture showed the dreaded multi-drug antibiotic-resistant pseudomonas and E Coli. Almost all antibiotics like polymixin B, Amikacin, meropenem, cefepime, etc., were resistant. The patient was having fever, and blood tests also showed significant leucocytosis with a rise in neutrophils. We had no option but to take two physicians' advice and patient parent guardian consent on bacteriophage topical application on burn wound and was done on a compassionate basis as fear of mortality was high due to wound sepsis not responding to any antibiotics. E Coli got eradicated in a week, but the dreaded pseudomonas aeruginosa took about two months to be eradicated with a cocktail and customized bacteriophage therapy. However, the third- month wound culture detected bacterias like staphylococcus, klebsiella and Citrobacter having sensitive to few antibiotics,

but we continued treating them with customized bacteriophages to these bacterias [Fig 2]. The extensive, severe burn wound infected with antibiotic-resistant bacteria healed using bacteriophages without skin grafting [Fig. 3]. Antibiotics were avoided as they were mostly resistant and of no utility in this patient. The trial with bacteriophages was highly successful and encouraging.

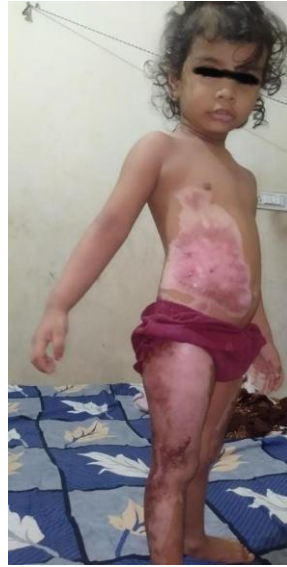However, it has taken 4-5 months duration. The left thigh healed within 3 months, followed by the right leg and deep abdomen wound with necrotic slough took the longest time, about 5 months. No contractures and minimum scarring occurred. It prevented burn wounds from becoming full thickness loss due to infection, which seemed partial-thickness. Deep burn with necrotic slough also healed with repeated alternate day topical application of bacteriophages.



**Figure 1:** Extensive infected thermal Burn wound 5th Feb. 2022.

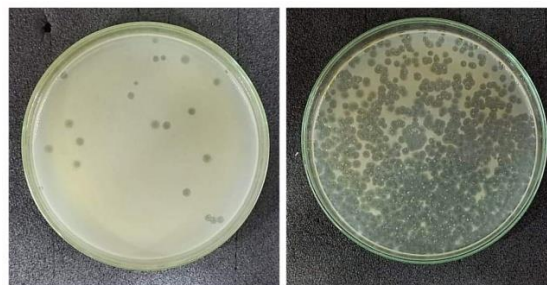


**Figure 2:** Progress of wound 19th March 2022



**Figure 3:** Burn Wound Healed By Bacteriophage Therapy 20th June 2022.

**Materials and Method:** Isolation of bacteriophages is done in microbiology lab [2]. 100ml of water specimen from river Ganga, hospital sewage and ponds are collected. It is centrifuged and supernatant is obtained. It is then treated for ten minutes with 1% chloroform. After that it is incubated for four hours to bring the lawn culture into log phase. This treated water is poured in 2 ml volume on 90mm petri plate and incubated overnight at 37 degree centigrade for plaque formation. If there is no plaques, the surface of plate is washed with 5ml TMG(Tris magnesium chloride) buffer(pH7.0). The washing is centrifuged and treated with chloroform 1% to lyse bacteria but sparing the protein coated viruses. The supernatant is now dropped on fresh lawn culture of the host bacterium in the log phase. The plaques are seen on next day after overnight incubation. The plaques having different morphology are cut and propagated on the host bacteria [Fig 4]. The number of specific phages is increased by inoculating larger surface area of Roux bottles. Then the sufficient harvested volume is subjected to membrane dialysis at 4 degree centigrade with three changes of 25 % PEG( polyethylene glycol) buffer three times. The purified phages are suspended in normal saline to have ready to use concentration of  $10^9$  CFU/ml of bacteriophages.



**Figure 4:** Double Layer Agar Method Showing Plaques of Different Size of Bacteriophages.

The dressing of infected burn wound is done by normal saline only. Betadine, spirit, chlorhexidine, or any antiseptics use is forbidden as it kills the bacteriophages and thus decrease its efficiency. The wound is washed with normal saline. Bacteriophages soaked sterile gauze pieces are applied on the wound surface topically. The wound is dressed with two layers of bandage only to hold the wet gauze pieces.

For 2 weeks initially, it was done in hospital and then patient attendant was taught about dressing at home and called weekly for clinical review. Proper inspection and investigations were done. According to culture customized bacteriophages were prepared. Sometimes along with that cocktail of bacteriophages were utilised for dressing. Bacteriophages were supplied in sterile falcon tubes and stored in freezer which can be kept for long time without losing potency. Before using, it was thawed to room temperature and once out of freezer it is not kept back in freezer.

The topical application of a maximum of 50 ml of  $1 \times 10^9$  CFU/mL of bacteriophage cocktail of 3 different phages were used on resistant bacterial infected burn wounds on alternate days. We used customized bacteriophages filtered and prepared in the Department of Microbiology for culture-resistant bacteria [2, 3, 4]. No debridement or slough removal was done, and slowly with time, necrotic slough disappeared with the healing power of bacteriophages. During application, there was no evidence of a sudden rise in leucocytosis, fever or other adverse side effects. After every two weeks, blood levels of bacteriophages were determined, and a concentration of  $1 \times 10^5$  CFU/mL was found.

### III. RESULTS AND DISCUSSION

The bacterial count concentration is decreased by debridement but not eliminated. Even the additional use of antibiotics and topical antiseptics will eradicate biofilm and persistent infection. Bacteriophages are seen to be effective in destroying all types of resistant bacteria, preventing and eradicating wound sepsis and thus avoiding the development of any septicemia. The advantages of bacteriophages over antibiotics are quick, simple and inexpensive collection in lab.

Bacteria becoming resistant to it is about ten times lower than developing antibiotic resistance. Phages survive and continue replicating even in harsh environments, controlling the host bacterial population significantly. They have high specificity for their host and work like targeted guided missiles, not affecting nearby other cells [5, 6, 7]. So they don't risk the natural microbiota of the human body. Thus they are without side effects associated with chemical antibiotics. The safety of phage therapy has been demonstrated with minor or minimal side effects. A study on topical use of bacteriophage in extensive burns like this case is lacking in the literature except which I reported as letter to the editor in one journal recently giving brief outlines [1]. Our study discovered it to be safe as no adverse side effects were seen clinically, like fever or the extreme rise of leucocyte count. The absence of significant scarring or formation of contracture without need of plastic surgical skin grafting procedure may be attributed to anti inflammatory and immune modulator properties of bacteriophages [8, 9]. However therapy is of long duration of conservative topical treatment. So superbugs will be taken care of by bacteriophages in future [10]. We are sure that the role of bacteriophage will be established very soon by further study in multiple drug-resistant infected wounds associated with biofilm.

ROLE OF BACTERIOPHAGES IN BURN WOUND HEALING – A RAY OF HOPE FOR ELIMINATING MULTIPLE ANTIBIOTIC RESISTANT BACTERIA.

Tomorrow’s trial needed: Bacteriophages depend on phage-bacterial and phage-host interactions. Despite the evident success of phage therapy; the issues of the evolution of phage-resistant bacteria during treatment, possible endotoxin storm by high doses of more than  $1 \times 10^9$  CFU/mL and fear of transfer of virulent and antibiotic resistance genes in commensal bacteria and immune neutralization, especially after 3 weeks of therapy are considered significant hurdles to be addressed in phage therapy[11].

As of today, phage therapy is the best biological weapon to destroy multidrug-resistant bacteria and can be tried in cases with high morbidity and mortality after high-risk consent [Fig 5].

**My initial tryst with bacteriophages in wound care clinical evidence**  
 SUDHIR SINGH MD [MBBS, MS (Surgery), MCh(Plastic Surgery), FICS, FIAMS.]  
 Member- Society for Bacteriophage Research & Therapy  
 HON. IMA PROFESSOR - ACADEMY OF MEDICAL SPECIALITIES & SENIOR CONSULTANT PLASTIC SURGERY, GETWELL HOSPITAL, VARANASI, UP, INDIA.

**Introduction:** Done lot of cases successfully with bacteriophages in small nonhealing chronic wounds in our region. In fact our clinical evidence of topical application of bacteriophages on extensive multi-drug resistant(MDR) bacterial infected burn wounds has been done for first time and never been reported in the literature.

**Method:** The use of antiseptics like betadine, spirit, chlorhexidine, etc. is forbidden as it decreases the efficacy of bacteriophage therapy by killing most of this biological weapon. After washing with normal saline sterilized gauze pieces soaked with bacteriophages is applied on the wound surface topically. According to culture customized bacteriophages were prepared and some times along with that cocktail of bacteriophages were used. Bacteriophages were supplied in sterile falcon tubes and stored in freezer and can be kept for long time without losing potency. The topical application of a maximum of 50 ml of  $1 \times 10^7$  CFU/ml of bacteriophage cocktail of different phages were used on resistant bacterial infected burn wounds on alternate days. We used customized bacteriophages filtered and prepared in the Department of Microbiology for culture-resistant bacteria[1, 2, 3]. No debridement or slough removal was done, and slowly with time, necrotic slough disappeared with the healing power of bacteriophages. During application, there was no evidence of a sudden rise in leucocytosis, fever or other adverse side effects. After every two weeks, blood levels of bacteriophages were determined, and a concentration of  $1 \times 10^7$  CFU/ml was found with no side effects.

**Material:** Isolation of bacteriophages is obtained from about 100ml of water specimens from river Ganga, hospital sewage and ponds in the lab. The purified phages at a concentration of  $10^7$  PFU/ml of bacteriophages are suspended in normal saline and is used for topical wound infection.

**RESULTS:** All wounds big or small healed irrespective of biofilm and persistent MDR infection. The absence of significant scarring or formation of contracture without plastic surgical skin grafting procedure and long duration of conservative topical treatment may be attributed to anti-inflammatory and immune modulator properties of bacteriophages [7, 8].

**DISCUSSION:** The advantages of bacteriophages over antibiotics are quick, simple and inexpensive isolation. Bacteria becoming resistant to it is about ten times less than developing antibiotic resistance. It is highly accurate to its target pathogens, and if it gets resistant, then mostly after 3 weeks, but there are at least more than 600 bacteriophages for one bacteria; therefore, there is no shortage of isolating proper bacteriophage without scarcity. Phages survive and continue replicating even in harsh environments controlling the host bacterial population significantly. They have high specificity for their host and work like targeted guided missiles, not affecting nearby other cells[4, 5, 6]. So they don't risk the natural microbiota of the human body. Thus they are without side effects associated with chemical antibiotics. The safety of phage therapy has been demonstrated with minor or minimal side effects. A study on topical use of bacteriophage in extensive burns like this case is lacking in the literature. Our study found it safe as no adverse side effects were seen clinically, like fever or the extreme rise of leucocyte count.

**SOCIAL IMPACT: GLOBAL**  
 It has high potential of growth and bring revolution in treating and saving septic patients at cheaper cost without side effects. It will have positive impact on economy and bring revolution in treating and saving septic patients at cheaper cost without side effects. Mankind will have no fear from superbugs. Innovation is the hallmark of plastic surgeons.

**Case - Wound over Pellets**  
 Case - Abscesses 23.03.2018  
 23.03.2018

**Acknowledgement:** Prof. Gopalnath, and Rajesh Kumar(Lab Tech), Microbiology deptt, IMS, BHU for providing bacteriophages.  
**REFERENCES:**

Figure 5: Bacteriophage in Wound Care Evidences.

**Acknowledgement**

I am really thankful to Sulekha Singh proprietor of Getwell Hospital, Gopal Nath Prof. of Deptt. of Microbiology IMS, BHU and Rajesh Kumar Lab Tech. of Deptt. Of Microbiology, IMS, BHU for providing necessary help. Bacteriophages were provided free to patients.

**Author Biography**

Sudhir Singh, Hony. Professor Academy of Medical Specialities – IMA and Sr. Consultant Plastic Surgery-GETWELL HOSPITAL, Varanasi-221005, UP, India

## REFERENCES

- [1] Sudhir Singh. Our clinical evidence on infected burn wound healing with the bacteriophages-future revolution on the horizon. *IP Indian J Clin Exp Dermatol* 2022;8(4):269-270.
- [2] Dev Raj Patel, Satyanam K Bhartiya, Rajesh Kumar, Vijay K Shukla, Gopal Nath :Use of customized bacteriophages in the treatment of chronic nonhealing wounds: a prospective study; *The International Journal of Lower Extremity Wounds*; Volume, 20, Issue, 1, Pages, 37-46.
- [3] Mayank Gangwar, Sonam Rastogi, Digvijay Singh, Alka Shukla, Neeraj Dhameja, Deepak Kumar, Rajesh Kumar, Gopal Nath :Study on the effect of oral administration of bacteriophages in charles foster rats with special reference to immunological and adverse effects; 2021, *Frontiers in Pharmacology*, Volume, 12
- [4] Archana Archana, Prem Shankar Patel, Rajesh Kumar, Gopal Nath :Neutralizing antibody response against subcutaneously injected bacteriophages in rabbit model; 2021/3, *Journal, Virusdisease*, Volume, 32, Issue, 1, Pages, 38-45.
- [5] Satyanam Kumar Bhartiya, Rina Prasad, Sumit Sharma, Vijay Kumar Shukla, Gopal Nath, Rajesh Kumar;Biological Therapy on Infected Traumatic Wounds: A Case-Control Study; 2022/1/5, *The International Journal of Lower Extremity Wounds*, Pages, 15347346211072779
- [6] Patrick Jault et al: Efficacy and tolerability of a cocktail of bacteriophages to treat burn wounds infected by *pseudomonas aeruginosa* (Phago Burn): a randomized, controlled, double-blind phase ½ trial; *The Lancet, Infectious Diseases*; Volume 19, Issue 1, page 35-45, Jan. 01, 2019.
- [7] Bahareh L A et al: Conventional treatment of burn wound infections versus phage therapy; *Iran J Med Microbiol* 2022, 16(3); 186-196.
- [8] Andrez Gorski et al: The fall and rise of phage therapy in modern medicine; Expert opinion on biological therapy: Vol. 19, 2019 – issue 11, pg 1115- 1117. <https://doi.org/10.1080/14712598.2019.1651287>
- [9] Marco Cafora et al: Phages as immunomodulators and their promising use as anti-inflammatory agents in a cftr loss-of-function zebrafish model; *Journal of Cystic Fibrosis* Volume 20, Issue 6, November 2021, Pages 1046-1052
- [10] Singh Sudhir: Clinical evidence based nano crystalline silver dressing rationality, efficacy and strategy in extensive burn patients survival; *IP Indian Journal of Clinical and Experimental Dermatology* 2020;6(3):268–273October 2020DOI: 10.18231/j.ijced.2020.054.
- [11] NIH US National Libraryof medicine: Phase therapy for the prevention and treatment of wound infections in burned patients; *Clinical.gov.identifier: NCT04323475*.