

DYNAMICITY OF HOMOEOPATHY IN OBSTETRIC DISORDERS WITH CASE ILLUSTRATIONS

Abstract

Homoeopathy in Obstetrics is much unexplored as the number of Obstetric patients approaching homeopathic physicians for treatment is far less reason being lack of knowledge among the patients as well as practitioners about the effectivity of homeopathic medicines in such cases. Homeopathy is a science based on Laws of Nature where life force is stimulated by potentised homeopathic medicines to address to the inner dynamic derangements and bring about cure. This holds true for all individuals of all age groups, genders, ethnicities and beyond. Likewise, it is also applicable to the in-vivo fetus as it is a part of this very same nature. In this chapter, we have attempted to share our knowledge and experience in this unexplored area of Obstetrics to reveal to the world the effectivity and utility of homeopathic medicines in Obstetrics and to inspire more Obstetricians and homeopathic physicians to positively and confidently approach Obstetric cases and help relieve the anxieties of suffering to-be parents.

Authors

Dr. Anand Suresh Kabra

M.D. HOM. Paediatrics
Professor and HOD
Homeopathy Pharmacy Department
SSVP Homeopathic medical
College and Research Institute
Hingoli, Maharashtra, India.

Dr. Archana Brijmohan Mundra

PhD (Scholar) M.D.Hom.Psychiatry
Associate Professor and HOD
Department of Organon of
Medicine and Homoeopathic Philosophy
Government Homeopathy
College and Hospital
Jalgaon, Maharashtra, India.

I. INTRODUCTION

Homoeopathy is a dynamic science based on dynamic, natural universal laws. Being dynamic, does it hold true and scientific in today's modern world? Today, the world demands evidences for authenticity. For ages homoeopathy has been ridiculed for its non-evidence basis and placebo effect. But with the advent of technology and its developments, recent studies have shown the presence of homoeopathic medications in form of nanoparticles in highly potentised homoeopathic dilutions as well. This is totally at par with the natural laws of physics which says 'matter is indestructible' and 'Energy can neither be created or destroyed, it can only be converted from one form to another.'

What happens in the body during pregnancy? Dynamic forces act to bring together genomes of two different DNAs and a new cell structure is formed with a totally different genetic make-up. This dynamicity brings about a chain of events in the body of the gravida. A lot of pregnant women have uneventful pregnancies and bring new life to life in perfect health. Though a few come up with certain disorders due to identifiable and unidentifiable reasons. Identifiable reasons like iron-deficiency anaemia are easy to modify and help the pregnant woman to lead a healthy pregnancy. But other disorders like abortions, placental and cord abnormalities, fetal problems etc. to name a few, have a very huge impact on the growth and development of the budding life and on the mother as well. Do we have any systems to measure this dynamic influence of nature? Since each of these is natural and dynamic, we have limitations to treat these with mainstream treatment methods. For all such cases and others, homoeopathy stands tall with its dynamic natural laws which aims at regulating and balancing the energies of the affected mother and the new life developing in her womb. It aims at rectifying the unidentifiable dynamic causes for such disorders to occur and rectify them with its power of similarity.

Below are a few illustrations of the above claims made by us a homoeopathic physicians. Role of Homeopathy in the field of gynaecology and obstetrics may not be a much explored area, but these cases will definitely give us insights about the power of dynamic homoeopathic medicines to rectify energy imbalances and thus restore the sick to health.

II. DISORDERS DURING PREGNANCY

1. Iron deficiency anemia
2. Gestational diabetes
3. Miscarriage
4. Fetal problems
5. Hypertension during pregnancy
6. Infections
7. Hyperemesis gravidarum
8. Abnormalities of placenta and cord
9. Pre-eclampsia
10. Preterm labour
11. Depression and anxiety

III.SCOPE OF HOMEOPATHY

- Miscarriage (abortions)
- Fetal problems
- Infections
- Placenta previa
- Placental abruption
- Depression and anxiety

IV.ABORTION

Abortion is the expulsion or extraction from its mother of an embryo or fetus weighing 500 gms or less when it is not capable of independent survival (WHO).

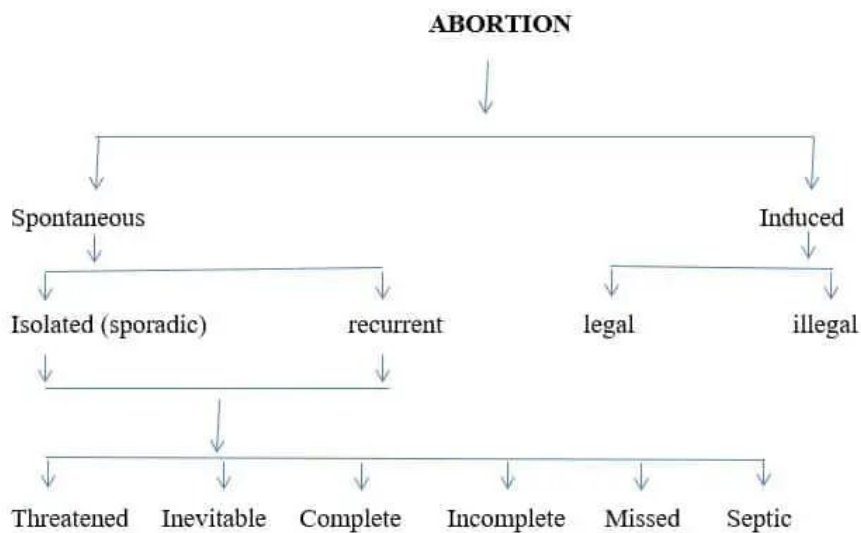


Figure 1: Classification of Abortion

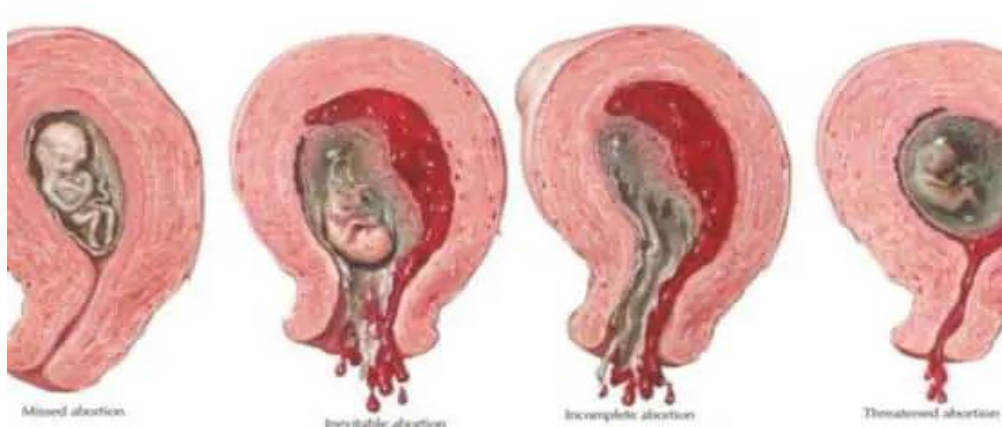


Figure 2: Diagrammatic Representation of Types of Abortions.

V. ETIOLOGY

- Genetic factors (50%)
- Endocrine or metabolic factors (10-15%)
- Anatomical factors (10-15%)
- Infections (5%)
- Immunological (5-10%)
- Others

1. First Trimester:

- genetic factors
- endocrine disorders (luteal phase defect, Thyroid, diabetes)
- Immunological disorders
- Infections
- Unexplained

2. Second Trimester:

- Anatomical abnormality
- Cervical incompetence
- Mullerian fusion defects (bicornuate uterus, bifid uterus, uterine synechiae)
- Maternal medical illness
- Unexplained

VI. MECHANISM OF ABORTION

- In early weeks, death of ovum occurs first, followed by its expulsion. In later weeks, maternal environmental factors are involved leading to expulsion of the fetus which may have signs of life but is too small to survive.
- **BEFORE 8 WEEKS:** ovum surrounded by villi with the decidual covering, is expelled out intact. Sometimes os fails to dilate so entire mass accommodates in dilated cervical canal called cervical abortions
- **8-14 WEEKS:** expulsion of fetus commonly leaving behind placenta & membranes. A part it partially separated with brisk hemorrhage or remains totally attached to uterine cavity
- **BEYOND 14 WEEKS:** like mini labour. Fetus followed by placenta after varying intervals.

VII. BOH

- **Bad Obstetric History (BOH)** The term 'Bad Obstetric History or BOH' is applied to mothers in whom a previous poor pregnancy outcome is likely to have a bearing on the prognosis of her present pregnancy.
- **The Habitual Abortion (HA)** is defined as the emergence of a number of at least three consecutive spontaneous abortions.
- Habitual abortion affects 1-3 % of fertile couples.

CASE NO. 1

Mrs. MRB

Date: 10/7/2019

Age: 22 yrs

Address: Jalgaon

C/O: Primigravida, LMP: 30/5/2019. Preg. 5weeks 5 days.

USG: early pregnancy with gestational age 5wks, 5 days, **large sub chorionic hematoma** is seen sized **3.1*0.9 cms**.

<ul style="list-style-type: none"> Female, reproductive system, cervix, vagina since 5 days Since 3 days 	<p>Leucorrhoea – small quantity, swelling, itching, no burning. Bleeding , light red colored</p>
---	--

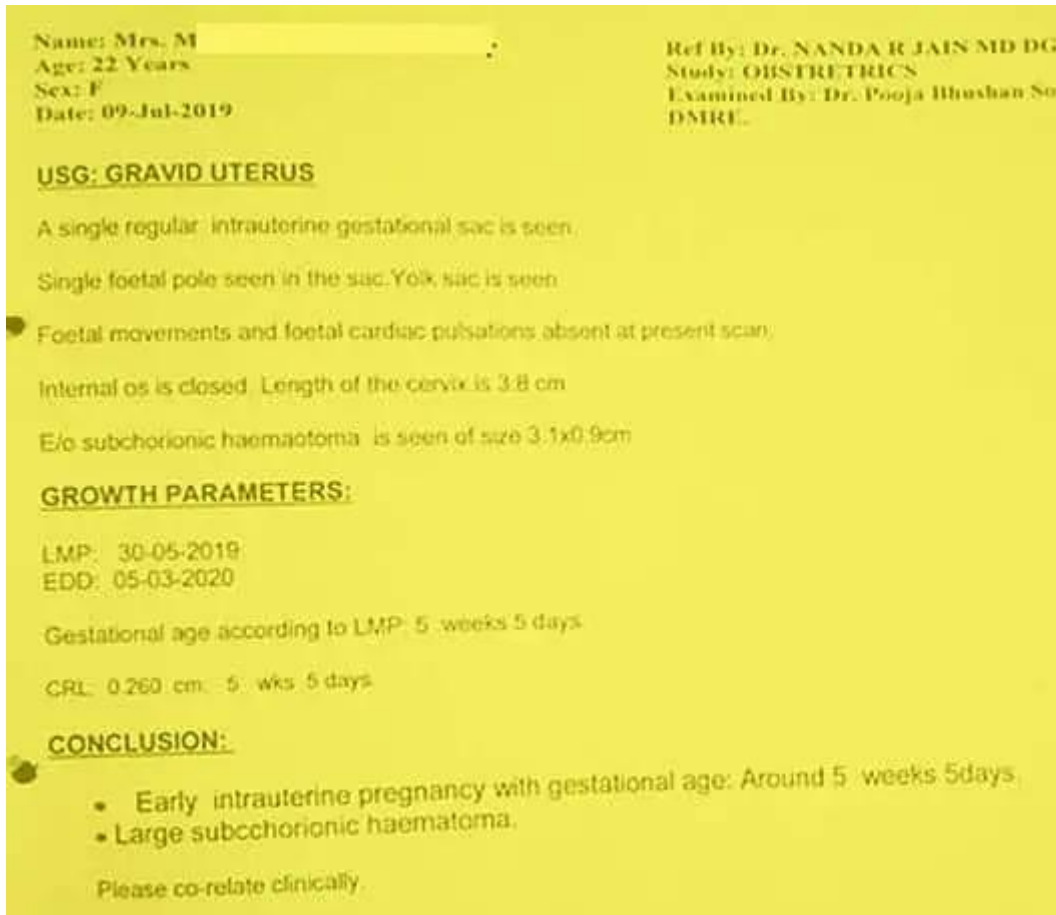


Figure 3: Ultrasonography Findings before Homoeopathic Treatment – Case-1

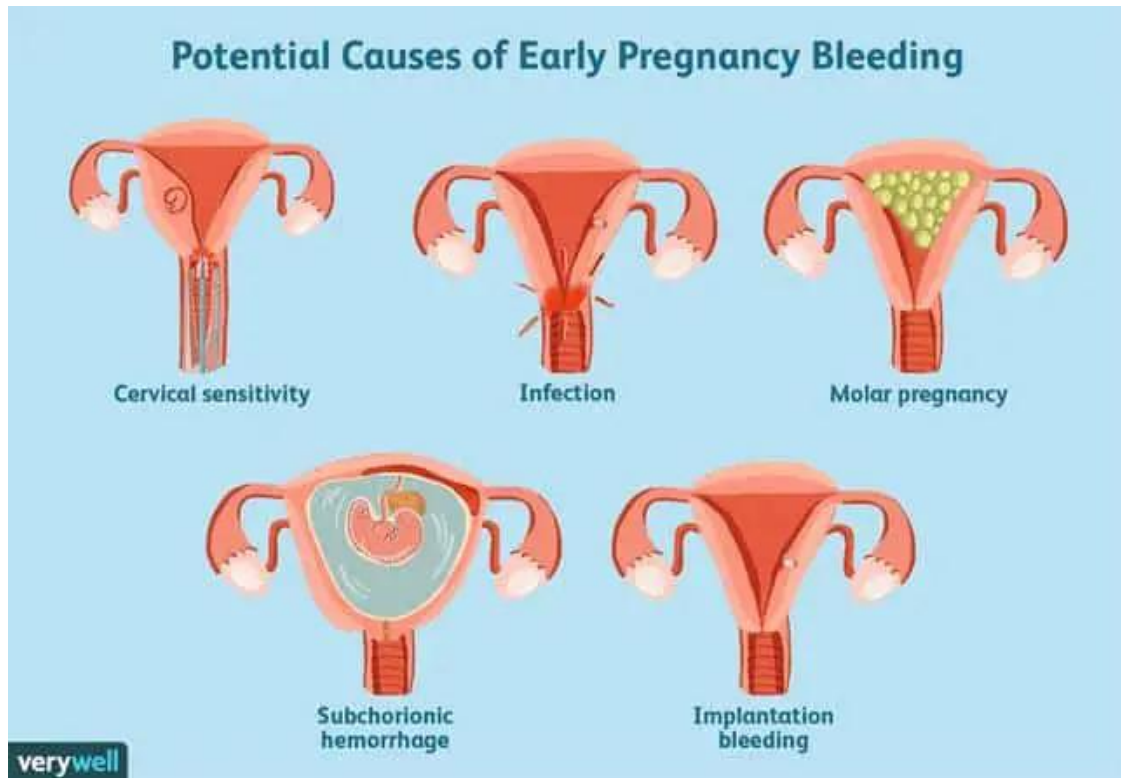


Figure 4: Potential Causes of Early Pregnancy Bleeding

VIII. ASSOCIATED COMPLAINTS

Skin since 3months Left hand thumb and lumbar region Skin of fingers Face,on and off	Fungal infection, Watery discharge blackness black spots	< brinjal Rx allopathic treatment, injections taken for it
---	---	--

- PAST HISTORY: Father – NAD, Mother – hypothyroidism.
- P/G: App- less, nausea
 Thirst: thirstless
 Stool- normal
 Urine- clear
 Sleep – sound
 Dreams- 0
 Desires – rice2
 Aversion -0
 Perspiration – anxiety after
 Thermals- HOT

IX. MENTAL GENERALS

- Studied till 10 std, scored 86% but no further study due to religious background, parents got her married.
- Husband is a fruit seller.
- After marriage stays in joint family.
- Fear – of everything, fear of dark, alone.
- Anxiety – future, worried about finances.
- Forgetfulness because of constant thinking.
- Extroverted And Expressive
- Irritability – when wronged, gets angry – stops talking, starts by herself after some time.
- Work speed is fast
- Fastidious wants everything neat and clean.
- Washing mania, wants cleanliness³,
- Clairvoyance²
- Restlessness and hurried³

X. TOTALITY OF SYMPTOMS

1. Cleanliness³, washing ³
2. Fear³, of dark, alone²,
3. Restlessness and hurried
4. Abortion in second month
5. HOT
6. Thirstlessness

Remedy Name	Thuja	Med	Sulph	Syph
Totals	7	9	9	9
Symptoms Covered	5	3	3	3
Kingdom				
[Complete] [Mind] Bathing, washing Desire for Cleanliness, mania for...	1	3	3	4
[Complete] [Mind] Bathing, washing Desire for Always Hands, her: (20)	1	3	3	4
[Complete] [Female Genitalia] Abortion, Month, week Second month: (1...	1			
[Murphy] [Mind] Restlessness, mental, (see Hurried, impatient): (411)	2	3	3	1
[Murphy] [Mind] Hurried, behavior, Mental, work, in: (8)	2			

Figure 5: Repertorisation Chart – Case-1

Remedy differentiation:

THUJA and MEDORRHINUM.

– Strong sycotic traits

- Symptom similarity

Final Remedy: THUJA 200

Follow up: Date: 23/7/2019, bleeding stopped completely on the next day, leucorrhea >>, itching1>, hand eruptions >, feeling fresh, app- normal, thirsty, st- normal, urine- clear, sleep –sound

Name: Mrs. M
Age: 22 Years
Sex: F
Date: 29-Jul-2019

Ref By: Dr. NANDA R JAIN MD DGO
Study: OBSTETRICS
Examined By: Dr. Pooja Bhushan Soni
DMRE.

USG: GRAVID UTERUS

A single regular intrauterine gestational sac is seen.

Single foetal pole seen in the sac. Yolk sac is seen.

Foetal movements and foetal cardiac pulsations are normal.

Internal os is closed. Length of the cervix is 4.2cm.

No iso subchorionic bleed is seen.

GROWTH PARAMETERS:

LMP: 30-05-2019

EDO: 06-03-2020

Gestational age according to LMP: 8 weeks 4 days.

CRL: 1.72 cm: 8 wks 3 days.

EEO according to USG 06-03-2020

CONCLUSION:

- Single live intrauterine pregnancy with gestational age: Around 8 weeks 3day.

Figure 6: Ultrasonography Findings after Homeopathic Treatment – Case-1

CASE NO 2.

Mrs. PDW

DATE: 29/8/2019

Age: 31 yrs

Address: JALGAON

C/O: USG shows 1-2 cms **funneling**, cervical length 1.6cm. G3P1L1A1. Preg. 6th month.

Right leg thigh from 2 months.	Pain ² Sudden, now increasing, so not able to walk	< walking, wake up, standing, slight movement.	Weakness ³ Swelling all over body.
GIT since 4 months	Nausea	< fasting, coconut water, empty stomach, morning	

Name	:	[REDACTED]	Age/Sex	:	31 YEARS/F
Ref By	:	Dr. Sushama Patil (MBBS DGO)	Date	:	29 Aug 2019

TEST: ANOMALY SCAN

Single live intrauterine gestation is noted.
Lie: changing presentation.

Foetal cardiac activity & movements: seen and are normal. FHR = 134 bpm.

Placenta: Fundo-posterior in location with Gr I maturity, no e/o placenta previa seen. No accessory lobe. Cord insertion is normal.

Amniotic fluid: Adequate for gestational age.

Internal Os is open measuring 1.2 cm in width with "V" shaped funelling .
Residual cervical length is 1.6 cm.

Foetal biometry:

BPD : 4.90 cm : 20 Weeks and 6 Days.
HC : 17.9 cm : 20 Weeks and 3 Days.
AC : 15.9 cm : 21 Weeks and 0 Day.
FL : 3.47 cm : 21 Weeks and 0 Day.

LMP : 03 Apr 2019 : 21 Weeks and 1 Days. EDD by LMP : 08 Jan 2020

US AGE = 20 wks 6 days EDD (USG) :10.01.2020 EFW= 387 gms +/- 57 gms

Fetal Anatomical Survey:

Foetal heart : Appeared 4 chambered.

Viscero-atrial situs solitus noted.

RVOT, LVOT appeared normal.

Five chambered view and three vessel view appeared normal.

IVS is intact. Foraminal flap showed normal movements.

All 4 chambers are of normal size. No **gross** anomaly detected.

Lungs appeared normal.

Page 2:

KUB: Both kidneys are normal in size and echotexture. No hydronephrosis or hydroureter. Bladder is normal. Normal emptying is noted.

Skeleton: Fetal spine appeared normal in coronal, sagittal and axial sections. No obvious spinal defect noted. Extremities are normal. Hands and feet are normal. No e/o agenesis or CTEV. Ribs are normal.

Brain: Skull vault appeared normal. The parenchyma is normal. Choroid plexuses are symmetrical. Cerebellum is normal. No abnormal calcification or cystic lesion noted. NFT is normal.

Face: Fetal eyes are normal in appearance. The interorbital distance is normal. Fetal nasal bone is well visualized. No e/o cleft lip or palate.

GIT: The stomach bubble is seen at its normal position. Normal emptying is noted. Other bowel loops are normal. No e/o echogenic bowel loops. Diaphragm is seen at its normal location and is intact.

Doppler:


Umbilical cord showed three vessels.
Uterine artery showed good diastolic flow with absent notch, favoring adaptation of pregnancy. Umbilical arteries and vein showed normal flow patterns.

IMPRESSION: *Maternal abdominal obesity limits optimal evaluation.*

Single live intrauterine pregnancy of 20 wks 6 days, adequate fluid, incompetent cervix, no obvious anomalies seen.

I declare that while conducting ultrasonography on this patient, I have neither detected nor disclosed the sex of her foetus to any body in any manner.

Note : Correlation with patient history, bio-chemical examination and follow up scans/Foetal Echocardiography is suggested in all the pregnancies due to late development of certain foetal abnormalities even in a normal scan at present stage.


DR. NIKHIL CHAUDHARI
M.B.B.S., DNB (Radiodiagnosis)

2.

Figure 7: Ultrasonography findings before Homoeopathic Treatment – Case-2

Cervical funneling is a sign of cervical incompetence and represents the dilatation of the internal part of the cervical canal and reduction of the **cervical** length. Greater than 50% funneling before 25 weeks is associated with ~80% risk of preterm delivery.

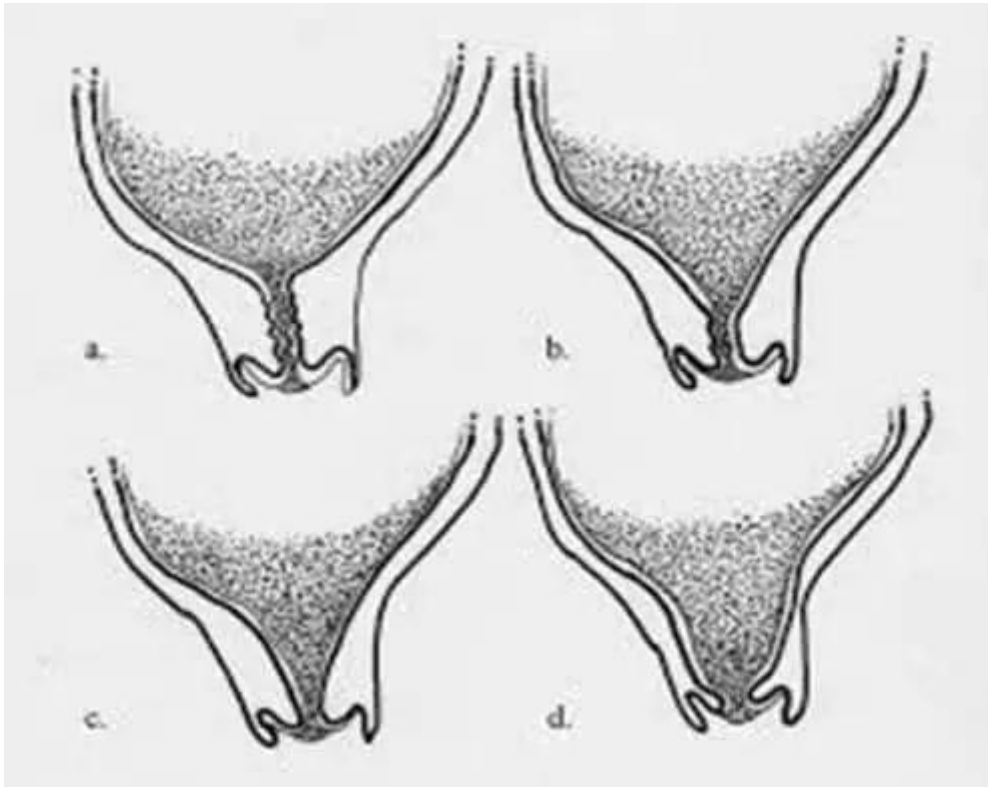


Figure 8: Stages of Funneling

P/H: 1 daughter 7yrs.

4 yrs back pregnancy aborted in 2nd month so D&C done.

Diagnosed with secondary infertility and IVF done

F/H: father- DM- police, Mother – house wife. 2 brothers. Patient is elder.

Education: BA, now housewife.

Husband: sales tax officer in GST bhavan.

P/G: App: good, easy satiety, Thirst: normal, stool- N, Urine: clear, Sleep: Disturbed due to pain in thigh. Dreams – 0,

Desires: sweets

Aversion: bitter,

Perspiration: scanty

Thermals: ambithermal

M/G: irritable, sudden mood changes.

Fastidious, wants everything neat and clean

Fear of hospital, injections

Impatience – wants to get over with pregnancy, problem should be solved.

Anticipatory anxiety²,

Introverted / inexpressive, express her feeling sometimes.

Childhood is good

Weeping while telling her symptoms about illness.

Totality

- Cervical os – half open
- Weeping while talking about illness
- Impatience
- pain in thigh < motion.

Symptoms: 4		Remedies: 326		Hide Repertorisation Tools		
Remedy Name		Sep	Nat-m	Staph		
Totally		11	10	10		
Symptoms Covered		4	3	3		
Kingdom						
[Murphy] [Female] DILATATION, genitalia Uterus, cervix, os, Half open: [...]		2				
[Complete] [Mind] Weeping, tearful mood: Telling about ones illness, ...		4	3	3		
[Complete] [Mirilli's Themes] Impatience: (307)		4	4	4		
[Complete] [Extremities] Pain Thighs: Motion Agg.: (38)		1	3	3		

Figure 9: Repertorisation Chart – Case-2

REFERENCE

Female, dilatation, genitalia, , uterus, cervix, os, half open: remedies sepia 1, Secale cor 2
Septia 200 single dose, with sepia 0/10, 5 drops, in half cup of water, three times a day and SL 4 pills bd after food for 15 days., with that her hormonal (allopathic) treatment is also continued.

FOLLOW UPS

14/9/2019: palpitation & trembling of body³, thigh pain – sq, nausea>>, weakness>>, app-normal, thirst- normal, stool – N, Urine- Clear. – ct all for 15 days

30/9/2020: thigh pain – sq, nausea -0, weakness-0, palpitation & trembling of body – Sq, feeling fresh,

My thinking was everything is better but her thigh pain is –sq, so thought of giving constitutional medicine. Gave Lyco 200 single dose

16/10/2020: pain in abdomen left side, preg. 7 month started. Leucorrhoea started from yesterday, palpitation & trembling is –SQ, thigh Pain –sq, p.g. good, except sleep- which is disturbed and less – so given sepia 0/10, TDS for 15 days again.

31/10/2019: leucorrhoea -0, palpitation and trembling –sq, pain in abdomen-0, acidity-0. sleep improved. P.g. good, SL for 15 days

16/11/2019: palpitation-sq, sleep – less, no pain, acidity on & off, leucorrhoea-0, fresh

USG: liquor is slightly less AFI-7cm, cervix is closed, placenta – postero-lateral. – sl given for 15 days

And stopped medicine. Pt delivered healthy baby boy on 19/12/19, normal delivery, 15 days early with no need of admission in NICU

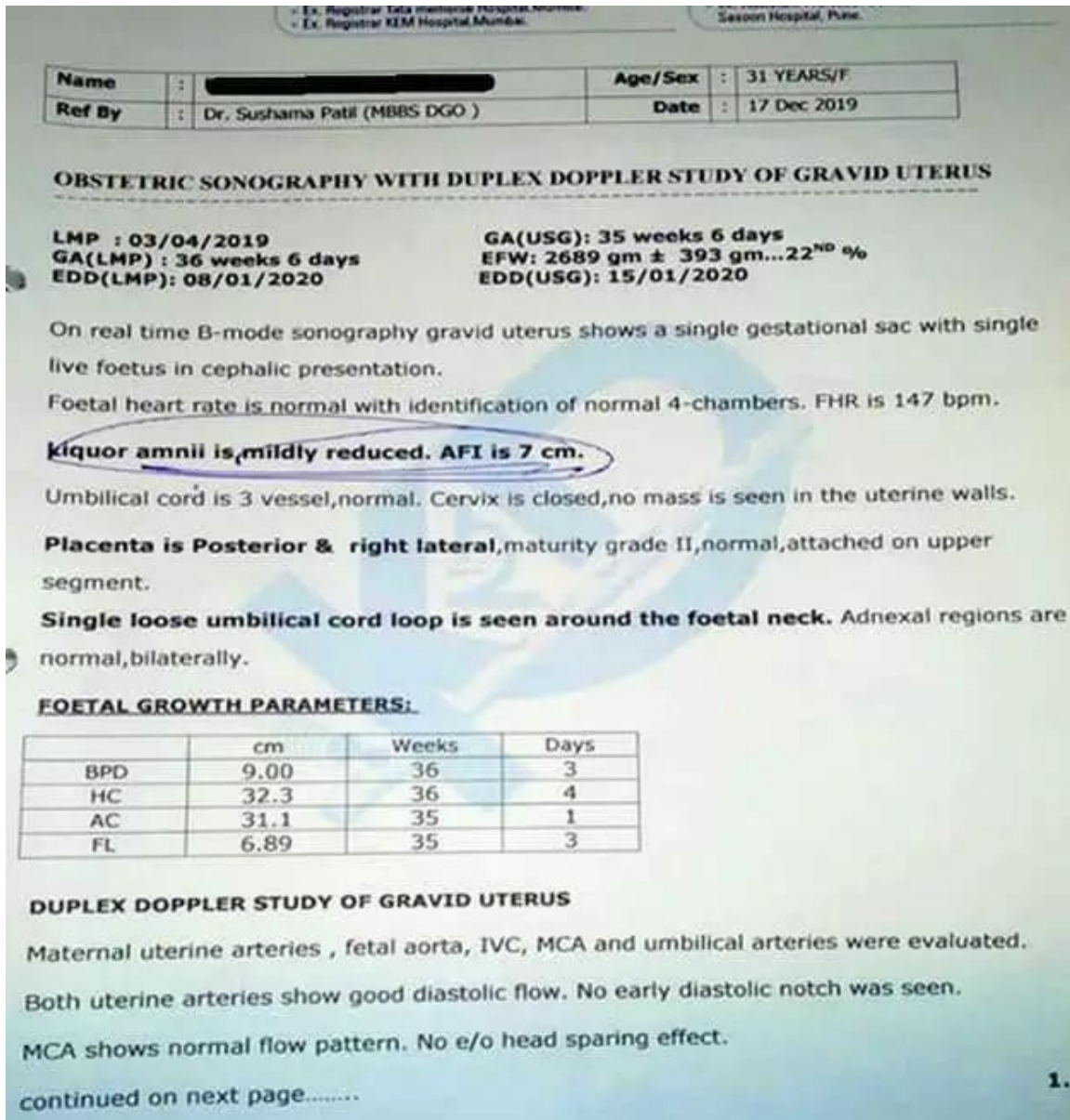


Figure 10: Ultrasonography findings after Homoeopathic Treatment – Case-2

CASE NO: 3

Mrs. PG

Date:22/4/2019

Age: 22 yrs

Add: Bhokardan. Dist- Jalna.

C/O: G5 P0 A4 L0 , LMP: 13/3/2019, UPT +ve but fetal pole not developed.

H/O BOH – Habitual abortions. (4 times). Inevitable abortions requiring D&C every time.

Each time, Patient complained of burning all over the body with pain in abdomen and sudden bleeding ,USG showing infant death.

1st– 5 yrs back – 2nd month

2nd– 4 yrs back – 2nd month

3rd– 3 yrs back – 3rd month

4th - 2 yrs back - 4th month
Married since 6yrs.
LMP: 13/3/2019

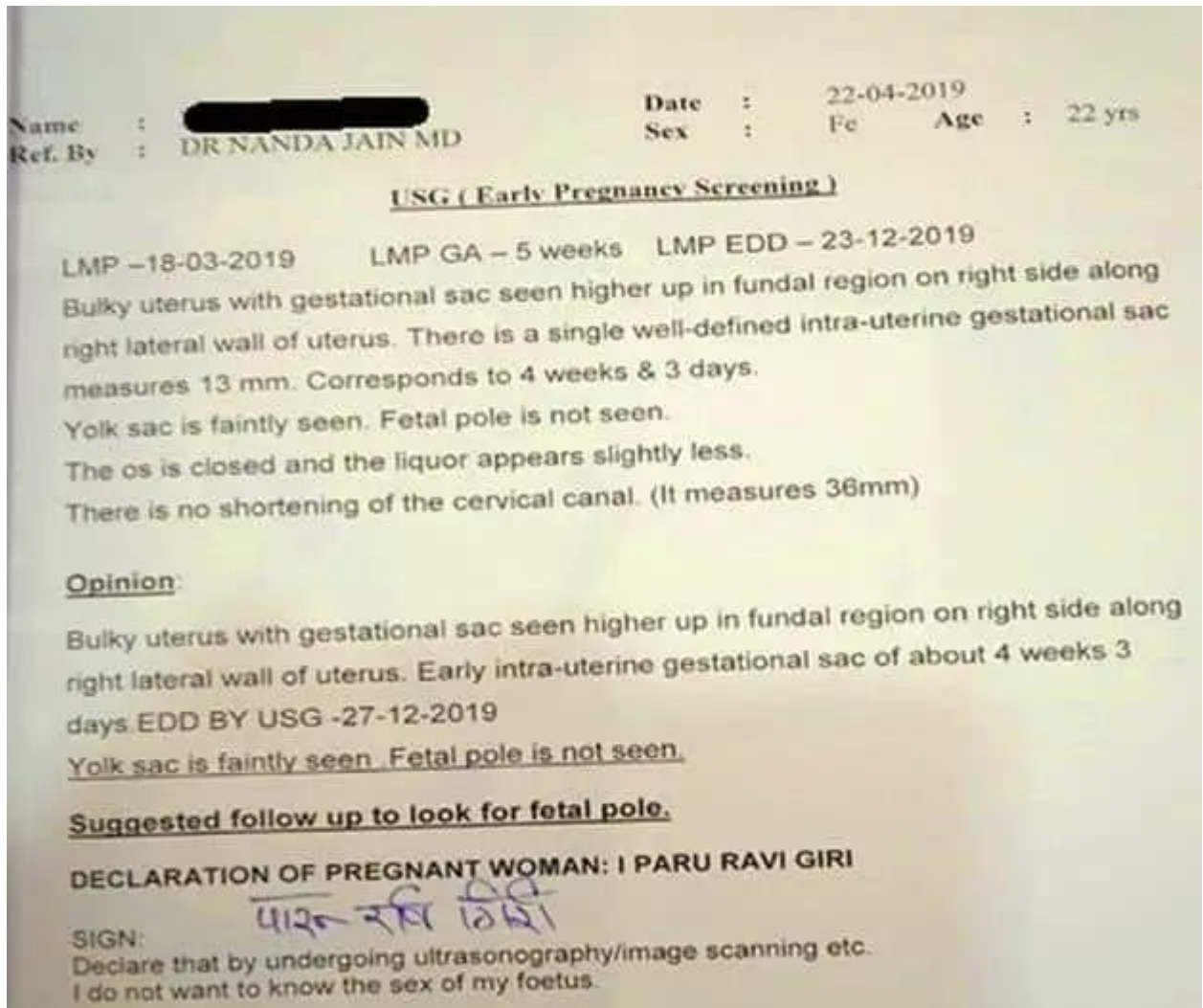


Figure 11: Ultrasonography findings before Homoeopathic treatment – Case-3

Family history

Father- T.B. Rx. Allopathic, perfume seller

Mother- NAD

4 brother & 5 sisters, patient is 3rd sibling. 1 sister expired Due to measles.

Education 7th std.

Husband: perfume seller working in Mumbai. Love marriage, consanguineous. H/O: consanguineous marriages in family.

XI. PHYSICAL GENERALS

App- good,
Thirst: Thirsty.
Stool- normal
Urine- frequent since 8 days
Sleep: sound
Dreams- 0
Desires: potato³, rice²
Aversion: peanuts, coconut, dry fruits.
Agg: coconut water – headache.
Perspiration: scanty
Thermals: Hot

XII. MENTALS

ANGER³, irritabilty³. with desire to kill.
Anger expressed over anyone.
Anger stops talking- once incident she stopped talking for 5 months., stops taking meal.
Others must listen her.
Talk – arrogant
Contradiction intolerance of³
Extroverted and expressive.
Tension of abortions – ghar kas chalnar, husband is only bread winner in family. FIL expired
6 yrs back.
Anxiety future about.
Superstitious.
Fear of dark³, shout loud if sudden darkness. Not able to be alone in dark.

Totality

- Fear of dark, alone.
- Anger, desires to kill
- Anxiety future about
- Superstitious
- Hot
- Thirsty




Remedy Name	Ars	Puls	Stram
Totality	8	7	6
Symptoms Covered	4	4	4
Kingdom			
[Complete] [Mind]Fear Alone, being Darkness, in: (16)	3	1	3
[Complete] [Mind]Anger Kill, desire to: (7)	1		1
[Complete] [Mind]Anxiety Future, about: (189)	3	3	1
[Complete] [Mind]Superstitious: (42)	1		1
[Complete] [Female Genitalia]Abortion Tendency to: (78)		2	
[Murphy] [Mind]Anger, general, (see Irritability, Rage):Talk, indispose...		1	

Figure 12: Repertorial Analysis – Case-3

Problems: USG was done very early with no fetal pole or cardiac activity seen in 5 weeks. Also, patient was not sure of LMP. As all we know it can take 6-8weeks for development of fetal pole, I was confused whether to wait or to start medicines. Patient has strong history of BOH, So thought of starting with constitutional medicine.

Remedy

Stram. 200 single dose, 0/1 5 drops in half cup of water TDS for 15 days and come with repeat USG report.

FOLLOW UPS

6/5/2019: no complaints, in mean time spotting which was reported by patient on phone. Her irritabilty >>, anger>>, patient is happy now. P.g.good- – stram 0/1 TDS continued for 1 month.

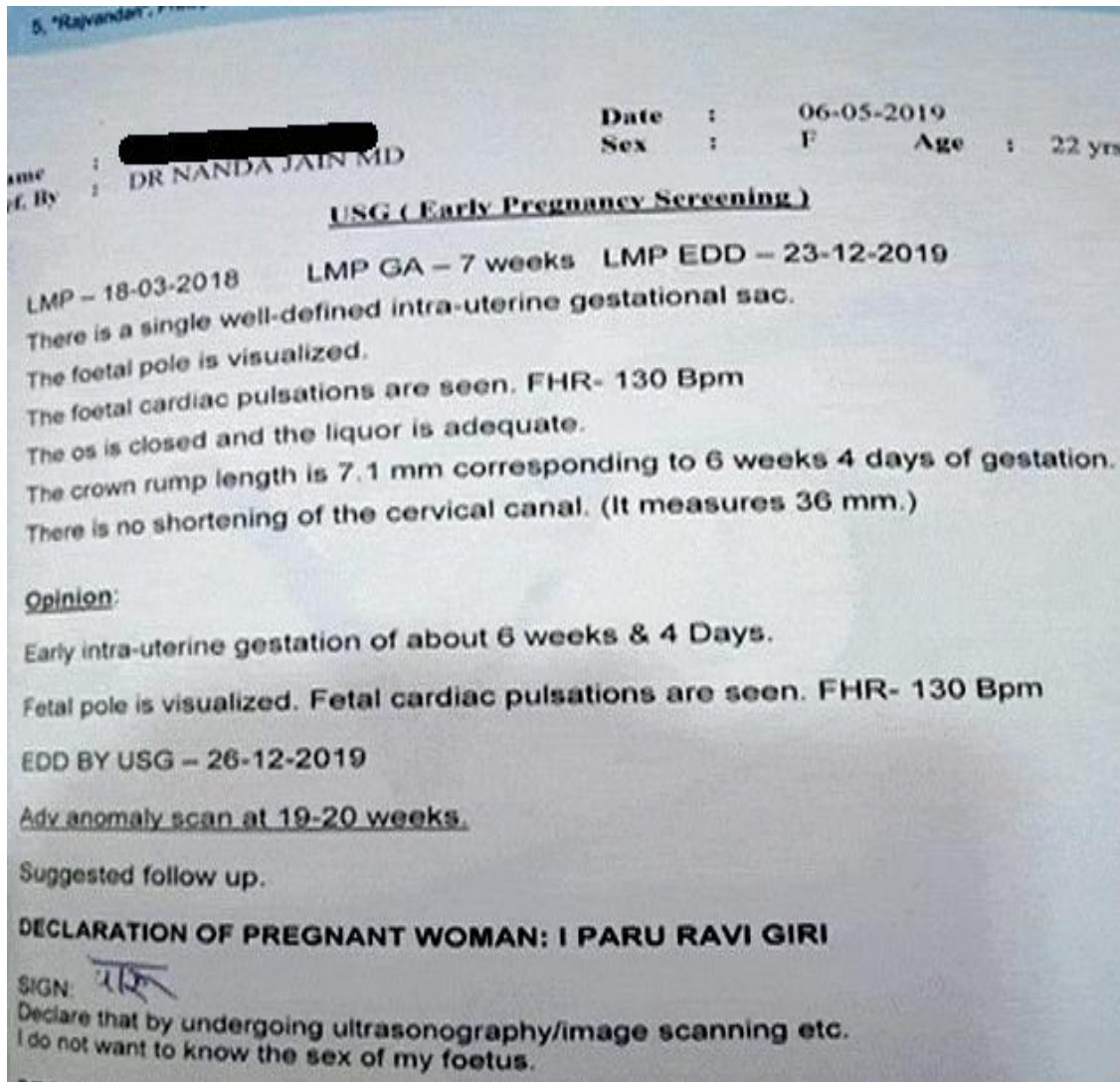


Figure 13: Ultrasonography findings after Homoeopathic treatment – Case-3

FOLLOW UP:

5/6/2019: nausea², occasional spotting , irritabilty >>, p. g. good sl for 1 month

5/7/2019: vomiting since 2 days with nausea due to some food changes. Irritabilty>>, acne< with black spots. – sl

6/8/2019: vomiting today¹, no nausea, usg – WNL

Vishal Diagnostics
X-Ray & Sonography Centre
5, "Rajvandan", Pratap Nagar, Near Swami Samarth Kendra, Jalgaon Ph : 0257-2240452

Dr. Vishal A. Piparia
M.B.B.S., D.M.R.D.
Consultant Radiologist
Reg.No. 89631

Name : PARU RAVI GIRI Date : 06-08-2019
Ref. By : DR NANDA JAIN MD Sex : Female Age : 22 yrs

USG (Pregnancy Anomaly Scan)

Single Live Intra Uterine Pregnancy in breech presentation.
Good Fetal Movements and cardiac activity seen.
Placenta - Fundal Posterior Grade - I
Liquor - Adequate
FHR- 141 Bpm
LMP -18-03-2019 LMP GA - 20 weeks 1 day LMP EDD -23-12-2019

Fetal Biometry

BPD	46 mm	19 weeks 6day
HC	172 mm	19 weeks 5day
AC	147 mm	19 weeks 5day
FL	32 mm	19 weeks 5day

Average Gestational Age 19 weeks 5 days.
EDD-26-12-2019
EFW- 328 grams.
Fetal skull, cerebral hemispheres , Falx, lateral ventricles-4mm, cisterna magna-6mm and cerebellum are normal. Transcerebellar diameter is-19mm.
Face, nasal bone, orbits and fetal lips appears normal.
Fetal spine appears normal.
Both fetal kidneys and bladder appears normal.
Fetal lungs and diaphragm appears normal.
Fetal stomach appears normal.

Dr. Vishal A. Piparia
M.B.B.S., D.M.R.D.

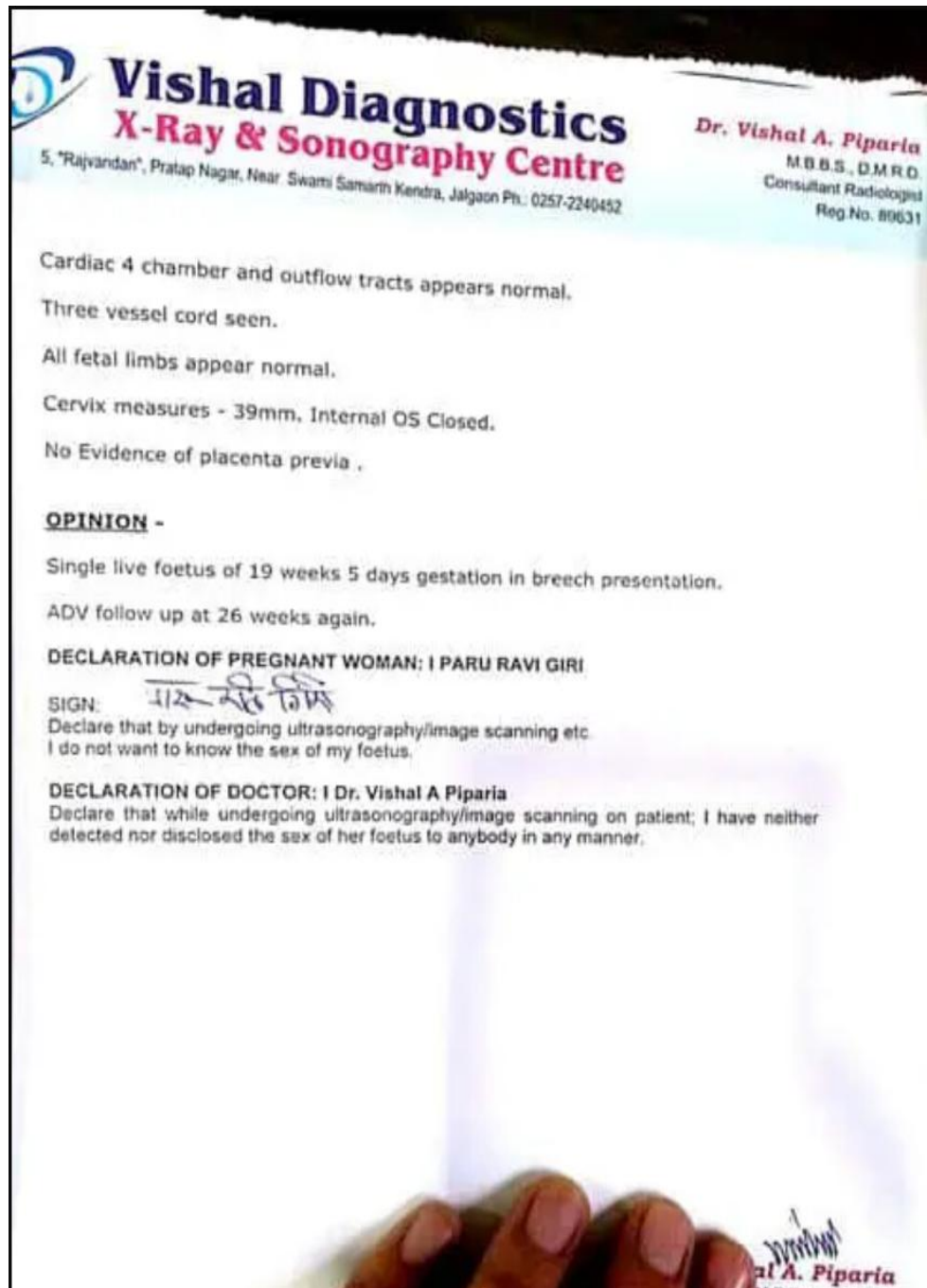


Figure 14: Ultrasonography Findings after Homoeopathic treatment – Case-3

9/9/2019: vomiting yesterday, pain in abdomen a/f outside food. Weakness, p.g. good- sl
Asked to stop medicine now.
Patient blessed with a healthy baby boy on **21/12/2019**, FTND at hometown in government
hospital.