

FUTURISTIC TRENDS IN RADIOLOGY

Abstract

Radiology is a field based on innovation with rapid changes and upgradation. In the past decades, radiology has continued to evolve as the imaging industry with the addition of MDCT and high field MRI and newer and advanced image guided interventional radiological procedures. As technology becomes more advanced, with the incorporation of artificial intelligence (AI) into healthcare, the Radiology subject or imaging standards are also going high. Various upcoming situations are impacting the healthcare system from the Radiology.

Keywords: Artificial Intelligence, Radiology, Magnetic Resonance Imaging (MRI).

Authors

Dr. Deb K. Boruah

Associate Professor
Department of Diagnostic & Interventional Radiology
All India Institute of Medical Sciences (AIIMS), Guwahati, India.
debpal80@gmail.com

Dr. Pranjal Phukan

Additional Professor
Department of Diagnostic & Interventional Radiology
All India Institute of Medical Sciences (AIIMS), Guwahati, India.
pphukan10@gmail.com

Dr. Kalyan Sarma

Assistant Professor
Department of Diagnostic & Interventional Radiology
All India Institute of Medical Sciences (AIIMS), Guwahati, India.
sarmakalyan@ymail.com

I. INTRODUCTION

Various key incoming are there to impact radiology in future. These are big data analytics, artificial intelligence, cloud storage, robotics & smart machines, 3D printing, augmented reality & virtual reality (AR&VR), radiogenomics, brain computer interface etc. World Wide Web remote availability impact radiology services worldwide and easy accessibility of radiological imaging and patient's data.[1]

II. ARTIFICIAL INTELLIGENCE (AI)

AI helps in early detection of a disease process, identify hidden abnormalities, increases patient accessibility and increases remote area coverage for remote/rural patient access.[2] AI also decreases the radiology staff shortages.[3]

III. INCREASED PRECISION AND AUTOMATION WITH ADVANCED IMAGING

Precision medicine has emerged as an approach to disease treatment and prevention. Due to this, radiomics has developed as a new field of radiology. With radiomics, radiologists and computers use deep learning to help AI find patterns of pixels. Precision medicine and radiomics will continue to grow, and with that comes the chance of some radiologists' tasks being automated, leaving more time to do other work like Interventional Radiology.

IV. ADVANCED IMAGING TECHNIQUES

There are many new techniques developed in Radiology.[4] Radiomics is currently developing and becoming popular. Along with radiomics, photoacoustic imaging and terahertz imaging are also in the works and play an important role. These techniques will allow for images to be taken of the body in far greater detail and accuracy than is currently possible.

V. RADIOGENOMICS

Radiogenomics able to provide the relationship/ associations between the radiological imaging features of a disease process and various genetical or molecular features. It helps the clinician to correlate the imaging findings to molecular/ genetical markers of the disease condition like cancer.[5,6] Radiogenomics helps in early detection of a disease process and to design a specific treatment for that condition.

VI. INTERVENTIONAL RADIOLOGY

Advancement in the various interventional radiological procedures, interventional materials, and devices increases the patient diagnosis and management in various imaging modalities like USG guided, CT guided, MRI guided and under DSA with keyhole procedure decreases the conventional surgical treatments.

1. Remove blood clots in a patient with stroke with aspiration/ retrieval of thrombus.
2. Treating life-threatening bleeding from any site/ organ.
3. Opening of occluded vessels.

4. Treated causes of subarachnoid hemorrhages with newer advanced in the techniques of management of aneurysm with the use of 3D coils [Fig 1&2], Flow diverter(FD) , Web device etc.
5. Treating complex AVM and AVF with use of liquid embolic agents like Onyx, Squid etc.
6. Doing various drainage procedures of abscess, collection etc.
7. Various biopsy procedures of diagnosis, especially in oncology setting.
8. Various ablative procedures like radiofrequency, laser ablation techniques in various oncologic as well as non-oncologic conditions. [7]
9. Pre-surgical tumor embolization. [Fig 3]

VII. PREVENTIVE CARE ASPECTS IN RADIOLOGY

As imaging evolves, radiology will play a bigger role in preventive care. Preventive imaging helps discover health issues before symptoms become more severe. Right now, there are preventive imaging techniques, such as getting a full-body MRI to detect any abnormalities, or getting regular mammograms to see if there are any changes in breast tissue.

Radiology is always striving to improve techniques and technology, so you can expect radiology to become more involved in preventive care. For instance, phase-contrast X-ray imaging, an imaging process used primarily in research labs, might be able to detect early-stage lung cancer.

VIII. RADIOLOGY FUTURE IN THE NEXT 20 YEARS?

There is potentially a huge upgradation in the future of radiology with advancement in technology, techniques, software and applications. Increasing use of quantitative and measurable data in CT and MR scans increases the diagnostic ability day by day and which will increase the standards in research and radiology practices. Even in the advancement of simulation, self-learning and AI in medical practices increases the applicability and productivity in the field of interventional radiology.

IX. FUTURE OF RADIOLOGY HELPS IN CLEARING THE VARIOUS QUARRIES IN THE DAY TO DAY MEDICAL PRACTICES LIKE

- 1. Helps in Early-Stage Diagnosis of Various Chronic Diseases:** Worldwide early diagnosis is a key to successful treatment in most of the chronic disease states.
- 2. Major Impacts During the COVID Pandemic with Chest Imaging:** Chest X-ray and HRCT scan of thorax play a key role in the early diagnosis, management and follow-up and identification of complications like mucormycosis, ARDS etc in patients with COVID-19 infection [8], especially in the second wave in India.
- 3. Teleradiology :** plays a big important role to improving radiology throughput, especially during the COVID pandemic, Teleradiology plays big role in solving the radiology reporting system.

X. NEWER ADVANCES IN THE FIELDS OF RADIOLOGY

Advancement of various technologies increases the output of radiologist works by providing clear high resolution images, easy access of the data, easy storage and easy communication.

- 1. Enterprise Imaging:** This newer imaging system increases the speed to access the various imaging data, reports and patients data from anywhere with the integration of vendor neutral archives (VNA) and which is gradually replacing the conventional PACS.
- 2. Off-Site Cloud Storage:** Storage of radiology department patient's data and images with cloud –based storage decreased the need of space of storage of physical data storages like CD,DVD, hard drives etc. for On Off-site cloud storage cloud based server provide spaces for cloud computing, where the saved data can be accessed anytime from any location.
- 3. Photon-Counting CT:** Use of photon counting detector, this newer CT technology enable higher spatial image resolution, crisp image post-processing, higher image contrast, reduced radiation doses and reducing various CT artifacts and multi-energy imaging capability over the conventional CT scan images and which helps in clear visualization of key anatomical organs or structures and increased confidence in radiologist reporting.[9]
- 4. Newer Advances in MRI Technology:** various new incorporations are coming in newer MRI machines like
 - Use of helium-free MRI system
 - Acceleration of MRI acquisition by use of compressed sense technique for saving valuable time
 - Incorporation of AI in various MRI techniques for diagnosis and depiction of various minute things, setting MRI protocols for saving time in MRI sequences.

Detailed anatomical and pathological informations of smaller organs with the use of various 3D sequences like inner ear structures [10], cranial nerves [Fig 4]., abnormal vascular loops, understanding chemical metabolites in normal brain parenchyma, tumor or altered signal intensity with the incorporation of single or multi-voxel MR spectroscopy, use of 3D-ASL for knowing the status of blood flow velocity to the abnormal lesion like tumor, inflammatory lesion or demyelinating lesions. Application of dynamic MRI images with kinetic curves in breast lumps [Fig 5], prostatic cancer, MSK tumor, liver masses are routinely used. Use of single or multi-voxel MR spectroscopy come to play an important role in the pre-surgical evaluation of brain tumor, breast tumor, prostatic cancer, solid abdominal organs neoplasm and MSK tumor etc.

- 5. Advances in Mammography:** Incorporation of Tomosynthesis, dynamic contrast enhanced mammography and 3D mammography increased the diagnostic ability and utility of the conventional/ standard digital mammography.3D Tomosynthesis provides more detailed and advanced imaging characteristics of breast tissues on mammography

and helps in early detection of breast cancers, crisp differentiations of various breast masses which further decreases the unnecessary breast biopsies.[11]

6. **3D Printing:** The various DICOM files of 3D images of CT scan and MRI scans were used after segmentations to create object by adding materials layer by layer manner. These 3D printing from the CT and MRI scan images used in various anatomical models for surgical planning, prosthesis and various medical devices. These 3D printing can be helpful for surgeons during complex surgical procedures.[12]
7. **Cinematic Rendering:** It provide more photorealistic of a 3D images data from CT and MRI scans. It is a 3D rendering algorithm superior to the standard 3D volume rendering technique (VRT). This cinematic rendering helps in detection of complex anatomy (diseases) coronary artery anatomy), complex anatomic relations and helps in planning complex surgical procedures like cardiac, vascular and neurosurgical surgeries. It also provides shape and depth perception.
8. **Virtual Reality and Augmented Reality (VR&AR):** Use of VR and AR in radiology implicate the change in clinical practices by providing imaging informations in virtual and augmented manners.[13] In VR, with use of head mounted display provide perception of something is there in non-physical world, while in AR, the virtual world or object is superimposed into a real world or object.[14] These VR and AR is adopted in radiology by using of 3D CT or MRI images of patients for proper delineation or review of complex anatomy or disease conditions in virtual environment. These VR and AR commonly useful in complex congenital heart disease and brain imaging prior to any surgical procedure.
9. **POCUS (Point of Care USG):** POCUS is an updated and advanced USG technique, which is used to perform in medical and surgical emergency and critical situations, like acute trauma, acute abdominal pain, acute airway compromise, acute pneumonia, pneumothorax, acute pulmonary edema, ectopic pregnancy, bleeding per vagina, left ventricular failure, pericardial effusion, pericardial tamponade etc.[15] Hence POCUS has been widely used for early and prompt diagnosis and further management of the various medical and surgical conditions.[12] During COVID-19 pandemic, POCUS plays an important role in diagnosis of acute pneumonia and follow up of COVID pneumonia patients.

XI. CONCLUSION

There will a significant changes in the coming decades in the field of imaging and interventional radiology. Due to rapid development of technology in the imaging and interventional radiology field, especially implication of AI in various segments of Radiology like high resolution digital X-ray, Ultrasonography, CT scan and MRI scan will contribute vast to the health care system and changes the imaging and interventional industry.

REFERENCES

- [1] Hricak H. Oncologic imaging: a guiding hand of personalized cancer care. *Radiology* 2011;259:63340.
- [2] S. Jha, E.J. Topol, Adapting to artificial intelligence, *JAMA* 2016; 316:2353

- [3] Koteluk O, Wartecki A, Mazurek S, Kołodziejczak I, Mackiewicz A. How Do Machines Learn? Artificial Intelligence as a New Era in Medicine. *J Pers Med.* 2021;7;11(1):32.
- [4] Boucher RC. Status of gene therapy for cystic fibrosis disease. *J Clin Invest* 1999;103:4415.
- [5] Rinaldi P, Menchini L, Martinelli M, Pastore G, Marano P. Computer-aided diagnosis. *Rays.* 2003;28(1):103-8.
- [6] C.F. Lundström, H.L. Gilmore, P.R. Ros, Integrated diagnostics the computational revolution catalyzing cross-disciplinary practices in radiology, pathology, and genomics, *Radiology* 2017; 285: 12–15.
- [7] Hamburg MA, Collins FS. The path to personalized medicine. *N Engl J Med* 2010;363:3014.
- [8] Wuni AR, Botwe BO, Akudjedu TN. Impact of artificial intelligence on clinical radiography practice: Futuristic prospects in a low resource setting. *Radiography (Lond).* 2021;27;1:S69-S73.
- [9] Nehra AK, Rajendran A, Baffour FA, Mileto A et al. Seeing More with Less: Clinical Benefits of Photon-counting Detector CT. *Radiographics.* 2023;43(5):e220158 doi: 10.1148/rg.220158.
- [10] B.M. Coursey, A reflection on the 150 anniversary of the birth of Marie Curie, *Appl. Radiat. Isot.* 2017; 130 :280–284.
- [11] A.S. Becker, M. Marcon, S. Ghafoor, M.C. Wurnig, T. Frauenfelder, A. Boss, Deep learning in mammography, *Invest. Radiol.* 2017; 52 :434–440.
- [12] F.S. Collins, H. Varmus, A new initiative on precision medicine, *N. Engl. J. Med.* 2015; 372:793–795.
- [13] Pelargos PE, Nagasawa DT, Lagman C, et al. Utilizing virtual and augmented reality for educational and clinical enhancements in neurosurgery. *J Clin Neurosci* 2017;35:1–4
- [14] Sutherland J, Belec J, Sheikh A, et al. Applying modern virtual and augmented reality technologies to medical images and models. *J Digit Imaging* 2019;32:38–53.
- [15] Wagner M., Shen-Wagner J., Zhang K.X., Flynn T., Bergman K. Point-of-Care ultrasound applications in the outpatient clinic. *South. Med. J.* 2018;111:404–410. doi: 10.14423/SMJ.0000000000000835

Figures:

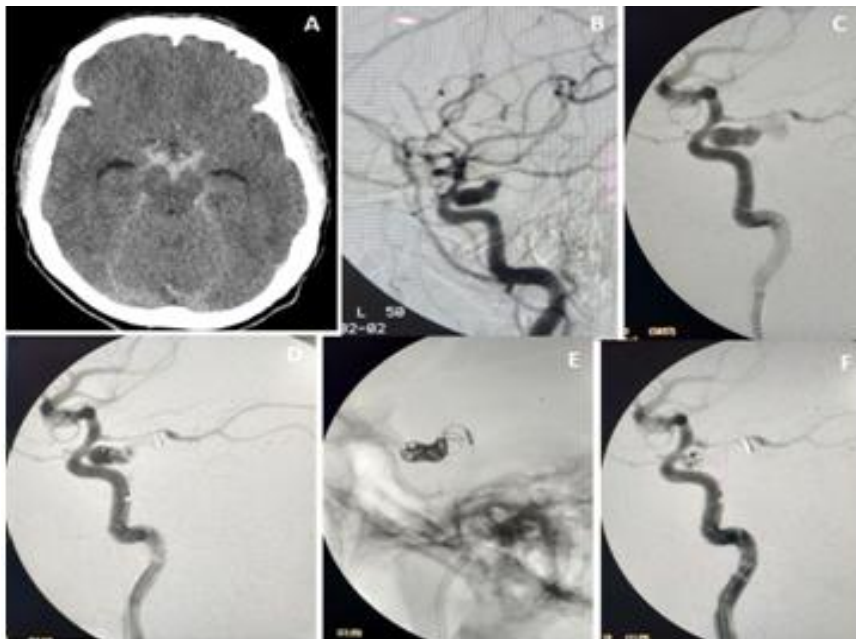


Figure 1: 43 Years Female with Grade-2 SAH. Axial Plain CT Scan of Brain (Image A) Shows Plain CT Hyperdense Extra-Axial Bleed of SAH in the Basal Cisterns. Left ICA Injection Angiogram Lateral Views (Images B and C) Shows an Aneurysm Arises from the Left Internal Carotid Artery of its Cavernous Segment. Microcatheter was Negotiated to Aneurysm Sac and Coil Embolization was Performed (Image D & E). Post Procedure Angiography Reveal (Image F) Near-Total Obliteration of the Aneurysmal Sac.

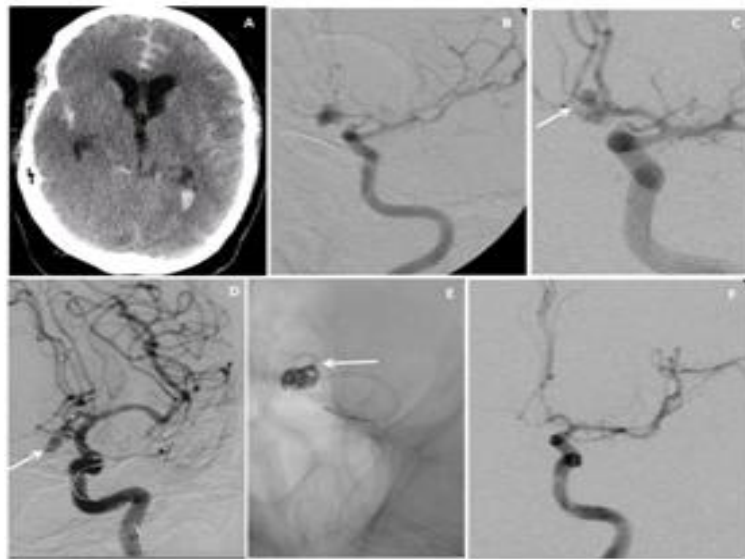


Figure 2: 47 Years Male with Grade-4 SAH. Axial Plain CT Scan of Brain (Image A) Shows Plain CT Hyperdense Extra-Axial Bleed of SAH in the Cisternal Spaces and Lateral Ventricles. Left ICA Injection Angiogram AP Views (Images B and C) Shows the Lobulated Ruptured Aneurysm from the Acom. Microcatheter was Negotiated to Aneurysm Sac and Coil Embolization was Performed (Image D & E). Post Procedure Angiography Reveal (Image F) Near-Total Obliteration of the Aneurysmal Sac.

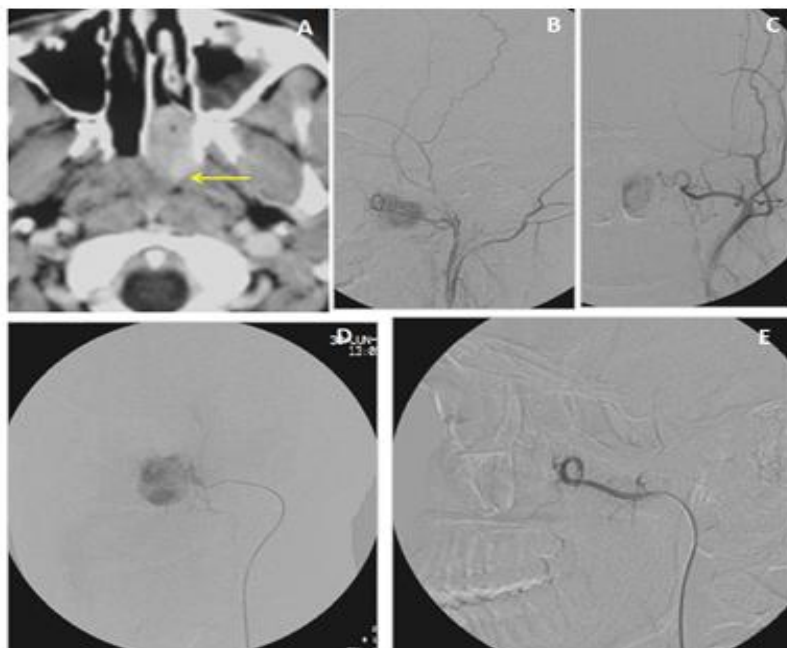


Figure 3: CECT (Image A) Reveal A Juvenal Nasopharyngeal Angiofibroma in Left Side of Nasopharynx Extends into the Posterior Nasal Choana. Angiography of Left External Carotid Artery (B& C) Reveals Abnormal Vascular Blush from Spheno-Palatine Branch of Left IMA. Microcatheter was Negotiated to Feeding A Artery And Embolization was Performed with PVA Particles (Image D). Post Procedure Angiography Reveal (Image E) Complete Obliteration of the Vascular Blush of the Tumor.

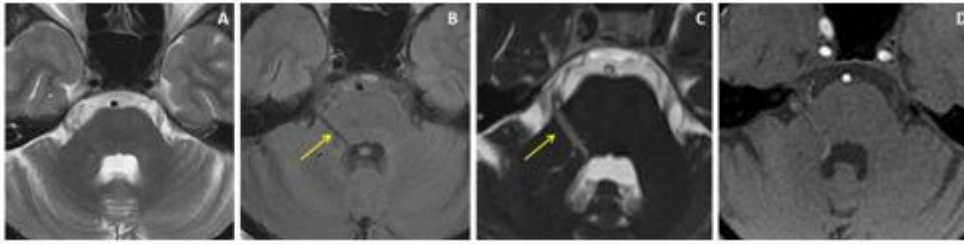


Figure 4: Cranial MRI Of 37 Yr Male Patient Of Trigeminal Neuralgia Presented with Lancing Pain in the Right Side of the Face Since 22 Years, Precipitated During Chewing, Exposure to Wind and During Winter Season. Axial T2W and FLAIR MRI Images (A & B) Showed an Abnormal Vascular Channel Running Over the Right Middle Cerebellar Peduncle. 3D-CISS Image and Source Image of 3D-TOF MRA (C &D) Showed the Abnormal Venous Angioma Started from the Ependymal Lining of 4th Ventricle and Extends Along the Right Trigeminal Nerve with A Positive NVB Contact (Arrows).

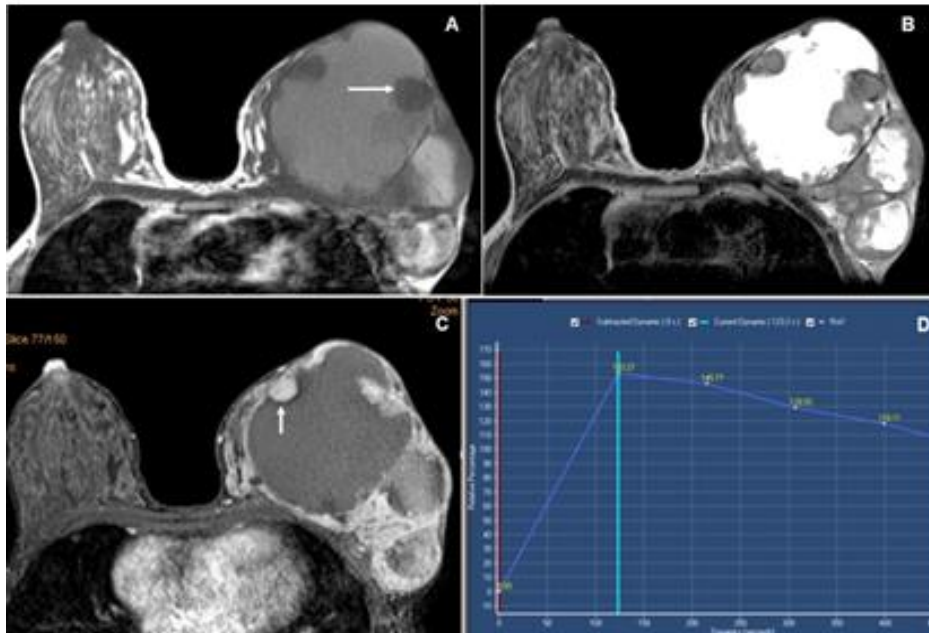


Figure 5: Breast MRI of 25 Years Female had Larger Lump in Left Breast. Breast MRI With Axial T1 and T2 Weighted Images (A &B) Shows A Larger Lobulated Solid-Cystic SOL in Left Breast with T1 ISO to Slight Hyperintense (Arrow) and T2 Hyperintense Cystic Component with Peripherally Located Soft Tissue Nodules, Which Shows T1 ISO to Slight Hypointense Signal Intensities. Contrast-Enhanced Dynamic E-Thrive Images (C & D) Showed Moderate Homogenous Enhancement of the Peripherally Located Solid Nodules (Arrow) with Non-Enhancing Central Cystic Area. Kinetic Curve Showed Type-III Curve and All Findings Representing BI-RADS-5 Lesion and HPE Showed Mucinous Carcinoma.