

# APPLICATION OF OPTIMIZED DEEP LEARNING MECHANISM FOR RECOGNITION AND CATEGORIZATION OF RETINAL DISEASE

## Abstract

Retinal disorders are one of the common eye problems and its complication affects the eyes. In some cases, the retinal diseases would not cause any symptoms or it only shows mild vision impairments. Finally, it causes no vision or blindness. So, earlier recognition of symptoms could help to avoid blindness. Routine screening is one of the methods for early diagnosis of retinal disease. Other common ways to identify retinal disease is to have an expert evaluate and rate eye photographs for the existence and severity of the illness. Unfortunately, in many parts of the world where retinal disease is common, but the medical specialists capable of recognizing DR are scarce. Hence, a novel optimized African Buffalo based deep Convolutional Neural Network (AB-DCNN) deep learning model is introduced in this article, which could detect the retinal disorders in the earlier stage from the fundus retinal image datasets and classify its stages. The proposed mechanism could detect diseases like Central Serous Retinopathy (CSR), Age-related Macular Degeneration (AMD), Diabetic Retinopathy (DR) and Macular hole (MH) and classify its stages as Severe, Moderate, Mild NPDR, PDR, and normal case. Depending upon the clinical importance, the impact of uncertainty on system performance and the relation among explainability and uncertainty are examined. The uncertainty evidences make the system more reliable for usage in clinical environments. The proposed methodology increases the operational speed and lessens the computation time of the algorithm. It also reduces the losses and enhances the classification accuracy.

**Keywords:** Retinal disease; Deep learning; African Buffalo optimization; Classification

## Authors

### Dr. M Nagalakshmi

Associate Professor  
Department of Computer Science &  
Engineering  
Marri Laxman Reddy Institute of  
Technology and Management  
Dundigal, Hyderabad, India  
nagalakshmi1706@gmail.com

### P. Nagaraju

Research Scholar  
Department of Computer Science and  
Engineering  
Kakatiya University, Warangal  
Telangana, India

## I. INTRODUCTION

As per the WHO's first World Report on Vision, approximately 2.2 billion people worldwide suffer from impaired vision or blindness. Furthermore, the world population's increase and changes in its age structure are leading this quantity to grow at a faster rate. The detection and prognosis of various eye illnesses from the muscle area is a critical issue for ophthalmologists (Abràmoff et al. 2018). As a result, illness progression is tracked and addressed through small vessel identification and structural and functional evaluation. Furthermore, the micro vascular networks and the retinal analysis structure are used to diagnose eye diseases for example macular edoema, glaucoma, and AMD. If retinal disease is detected earlier, it could be treated; otherwise, it might result in irreparable blindness. As a result, routine screening is critical for early diagnosis of retinal disease (Gadekallu et al. 2020). Unfortunately, in various regions of the world wherein the diabetes is more common, medical specialists capable of recognizing Diabetic Retinopathy disorder are scarce. There is enough data to suggest that retinal screening and diagnosis could help reduce unnecessary blindness. One of the simplest ways to identify retinal disorders is having an expert to evaluate and rate eye photographs for the existence and severity of the illness.

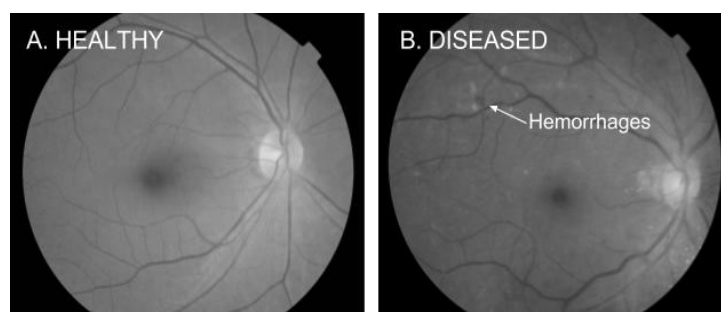The fundus camera was invented in 1926, and it changed the area of retinal screening and ophthalmology (Yannuzzi et al. 2004). The retinal images were acquired from a scanning laser ophthalmoscope or a fundus camera. For disease diagnosis and retinal analysis, a fundus picture is required. The growing need for retinal screening necessitates a fundus image that is both low-cost and ubiquitous. The posterior portion of the eye is photographed using normal fundus imaging camera that captures the fundus' RGB images. It is attached to a microscope with a flash-enabled camera. Fundus cameras are already accessible in clinics, which provide decent quality images, although they are typically big and expensive (Ghassabi, Shanbehzadeh, and Mohammadzadeh 2016). As a result, there have lately been major efforts to take use of recent advances in telecommunications and smartphone technique to develop convenient, cost-effective fundus cameras for ophthalmic screening in remote places. Fundus pictures could reveal and detect various critical retinal locations such as the Optic Disk, Ocular Centre, retinal vessel and Optic nerve head (ONH). An age-related macular degeneration (AMD), Diabetic retinopathy (DR), glaucoma, cataracts, and myopia everything could be detected with a fundus camera colour imaging approach, which is simple to set up. The blood vessels and optic disc in one's retina are easily affected by age-related macular retinal degradation, DR and glaucoma problems. However, there weren't enough extremely competent ophthalmologists participating in eye screening in many countries, particularly in low-income nations or regions with minimal healthcare resources.

Optical coherence tomography (OCT) is a mechanism that captures cross-sectional retinal pictures and facilitates to find abnormalities such as retinal tissue damages or fluid leakages. Therefore, it is clear that early diagnosis of the disorder is vital in preventing visual impairments in patients (Chowdhury, Chatterjee, and Banerjee 2019). The longer the condition is left untreated or undiagnosed, the more serious the problem would become. In the treatment of many diseases, machine learning techniques have become an extremely popular. The blood vessels and the optic disc in one's retina are highly influenced by age-related macular retinal degradation, DR and glaucoma of retinal illnesses. Diabetic retinopathy is a micro-vascular consequence of diabetics that creates gradual vision problems.

DR has been identified as a universal public healthcare issue, and diabetics based vision damage must be treated quickly to be avoided. According to epidemiological study, one for every 3 diabetics exhibits indications of DR, and a third of that may have eyesight retinal, which is classified as serious non-proliferative eye problems or diabetic maculae edoema (Orlando et al. 2017). Standard operating procedures are necessary to avoid the initiation and growth of DR, and DR screening programmes have always being suggested for diabetics. Because clear and sustainable programmes take significant resources to create and maintain, DR screenings is not extensively used as a federal programme around the world, and several individuals with diabetics are ignorant of high danger of DR and other relevant issues.

Slight Non-Proliferative Diabetic Retinopathy (NPDR), Severe and Moderate NPDR, and Proliferative Diabetic Retinopathy (PDR) are the four types of diabetic retinopathy (PDR). NPDR will be the first phase of diabetic retinopathy, which is characterised by microscopic aneurysm (MA), which is the smaller region of bulging in the retinal blood vessels. There seems to be no excessive bleeding in the retinal nerve, and if DR is discovered early enough, it may be possible to save the patient's vision with appropriate healthcare therapy. Slight NPDR escalates to a severe state if blood leaks from the clogged retina arteries if untreated. That's the Severe NPDR stage (H. Wang et al. 2000). Exudates (Ex) could be present at such time. Venous beading is caused by the dilatation and contraction of venous system in the retinal. In the Serious NPDR stage, a huge amount of blood vessels in the retinal are stopped, resulting in over 20 intra-retinal haemorrhages in all four retinal quadrants, or intraregional micro vascular abnormalities (IRMA), that could be seen as swellings of slender vessels that seem to tiny with pointed boundary red spots in at least one region and/or conclusive proof of VB in more than two quadrants. PDR is an extreme phase of the illness that develops whenever the problem is left untreated for a long time. Neovascularization (NV) represents the development of newly generated blood vessels in the retinal. Because these circulation arteries are generally fragile, there is a possibility of fluid leakage and tissue formation development. During this phase, various operational eye issues such as motion blur, limited range of view, and even full blindness may emerge.

The fundus pictures of a healthy and an impaired eye are illustrated in Figure 1.



**Figure 1: Healthy and Diseased Fundus Eye Pictures**

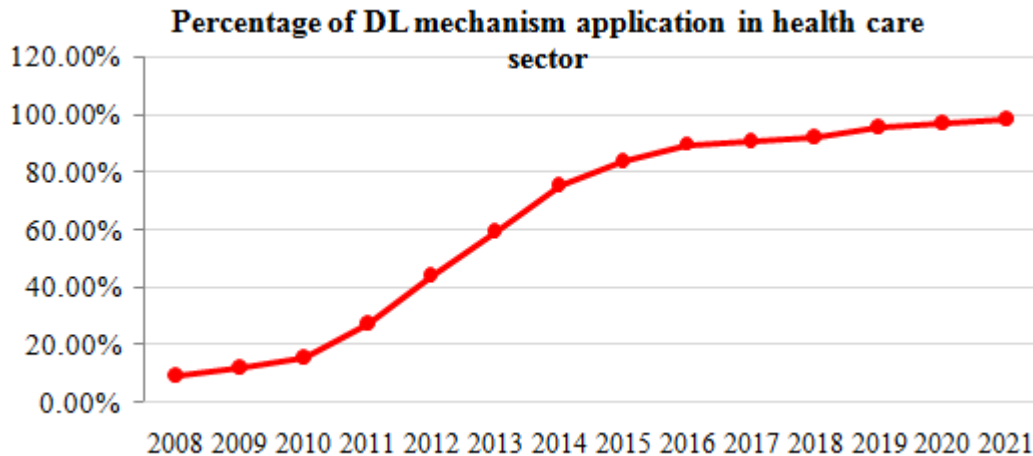
Ophthalmologists' manual diagnosis of retinal disease requires a lot of work, and is time-consuming, and is vulnerable to disease misdiagnosis. As a result, there is an emergency requirement for developing a simple and cost-efficient auxiliary diagnostic method for screening the ocular disorder. This problem could be handled with the use of a computer-

aided detection method which could prevent misdiagnosis and save time, money, and effort (Kanagasingam et al. 2018). Artificial intelligence (AI) was found to be an important and viable mechanism for automated diagnosis of eye diseases or detection based upon colour retinal fundus pictures, due to the progression of Artificial Intelligence mechanism in medical field over the last decades. In the last few decades, supervised deep learning techniques had attained outstanding specificity and sensitivity and in the AMD, DR, cataracts, pathological myopia and glaucoma detection, and have delivered advanced outcomes in the operation of classifying eye problems. However, since those models are trained with only a specific form of retinal disease, they might underperform in realistic conditions when the fundus picture utilised for interpretation would be neither healthy nor the particular ocular disorder being used in the training; in such cases, the system is certain to provide an inaccurate prognosis.

A multiclass approach that encompasses all sorts of eye illnesses could be a viable solution. But, such a model would involve vast datasets that were validated by ophthalmologists, but that would be time-consuming and costly. Moreover, due to the prevalence of some diseases and conditions, the whole range of probable abnormalities is rarely available. Artificial intelligence (AI) has found to be important and viable for automated screening of eye disease or detection based upon colour retinal fundus images, due to advancement of Artificial Intelligence in medicine throughout the last decades. In the recent years, the learning-based approaches aims for building a model based upon a set of attributes to recognize or categorize the outcome into various categories (Kavitha and Devi 2005). Amongst them, supervised deep learning algorithms have arisen and are being utilized in a numerous fields, particularly in the arena of medical image processing. It also has greater specificity and sensitivity in the analysis of retinal anomalies and gives advanced achievement in the categorization of eye diseases. Common machine learning approaches like Sparse Bayesian Classification, Multi-kernel extreme learning machines, Naive Bayes, Advanced Deep Learning, Support Vector Machines, and Random Forest algorithms have been broadly utilized for tackling medical issues and could also be used in identifying the Diabetic retinopathy disorder.

To overcome the DR challenges, sophisticated deep learning methods like CNN and Squeeze Net are used. Owing to its excellent performances in detecting patterns in big datasets, deep learning becomes a critical area in machine learning. In several fields, such as retinal imaging diagnosis, breakthroughs in automated illness identification utilising deep learning algorithms have resulted in superior performance to human vision. Deep learning algorithms may efficiently determine characteristics from data input for segmentation or classification, outperforming all other image analytic methods. Deep learning mechanism uses representation learning to uncover hidden patterns in massive amounts of data generated in this era of data explosion. It is designed to find representations for hidden features from datasets. It also offers a significant advantage over machine learning in terms of accuracy, making it significantly more accurate than machine learning. The efficiency of a deep learning framework increases with the amount of data used to train it. Therefore the more data we use, the more accurate will be the outcome. Deep learning, on the other hand, extracts features automatically and feeds them to the network to match with the item of interest. It's an essential part of the rapidly expanding discipline of data science. It establishes a rigorous conceptual framework for interpreting data and making decisions in diagnosis and

management. Figure 1 represents the application of Deep Learning mechanism in the health care industry from the year 2008 to till date (Srivastava et al. 2017).



**Figure 1: Application of DL Mechanism from 2008 to Till Date**

Despite the fact that DL-based techniques in healthcare are fast evolving, and several observational studies have shown that AI can function on pace with healthcare specialists, the majority of such techniques have yet to be examined in designed clinical predictive research (Lee et al. 2017). Many impediments, such as algorithmic accessibility, document management, confidentiality, and information standardization, impede actual deployment in patient-care situations. Furthermore, DL techniques are particularly 'data hungry,' necessitating vast amounts of health information to undertake huge investigations (He et al. 2019). Considering AI's quick and spectacular advancement, the healthcare industry is extremely hopeful that AI will eventually provide greater and lesser care (Stead 2018).

Typically, technicians travel to the rural places to acquire images, which are then reviewed and diagnosed by highly qualified clinicians. Their goal is to use technology to expand their efforts, i.e., to be able to automatically screen photos for disease and offer information on the severity of the problem. Medical experts are interested in computer-aided medical diagnostics for assisting in the assessment of medical pictures. In the last few decades, exploiting the potential of machine learning (ML) technologies and artificial intelligence (AI) mechanisms has attracted much interest. Deep learning (DL) algorithms, in particular, have also shown admirable performance when it comes to medical picture interpretation. Deep learning systems with economically comparable results have been established in ophthalmology for a variety of end tasks, such as the detection of various eye illnesses like DR, AMD and glaucoma (Ege et al. 2000). Yet, substantial, diversified, and precisely labelled data is required for the future growth, training, and evaluation of deep learning techniques. Obtaining good quality information from the diseased and healthy people comes at a higher expense in terms of both effort and money. Furthermore, as with many illnesses, the no. of observations is frequently insufficient to undertake statistically important analysis. Most significantly, ethical issues about privacy of patients and personalized medical information present important limits, potentially biasing

the outcome of the study, because all health professional must get genuine consent from patients, which is a legal, fundamental, and ethical necessity.

Throughout the disciplines of speech recognition, medication design, computer vision, medical image processing, and plenty of others, deep neural network has significantly contributed for investigation and decision making. The usage of sophisticated machine learning methodologies like Deep Neural network has made a substantial contribution to clinical screening and prediction of diseases, decreasing the need for human interpretation. In various domains, such as retinal imaging diagnosis, developments in automated illness identification utilizing deep learning approaches have resulted in performance incomparable to human observers over the previous decade. Currently, technological advancements have resulted in tremendous processing capacity, allowing neural networks to be applied in Machine Learning with the deep architectures. Building a deep learning approach could automatically assess the severity of blindness in a patient's ocular image. This automation technique can save a lot of time, which can be used to screen the approach of treating diabetic retinopathy in a broader scale. In tasks like segmentation and classification, deep learning algorithms for ocular diagnostics have shown a huge amount of potential. Softmax outputs pertaining to each of the target classes commonly make up the last layer of deep neural networks, which are used as classifiers. It's commonly misunderstood as the class probability. Despite having a higher softmax value, a model could be unreliable in prognosis because it learns during training to retain the value at its peaks for a lower loss function. Even when there is a little margin, deep learning-based classifiers normally deliver the group with the greatest softmax output as the outcome. End-users must be notified when a strategy is ambiguous in order to avoid making incorrect judgments.

The goal of the study is to create a web - based assistance diagnostics that can analyze input retina photos and categorise diabetic retinopathy stages using an optimum pre-trained DL-CNN model with different amounts of variables and tiers. It's difficult since fine-tuning of a pre-trained deep convolutional neural networks framework on Diabetic Retinopathy pictures may produce comparable findings. As a result, the problem must be met by choosing a proper technique for designing and building for DR picture categorization. As a result, in the study, an optimised deep learning architecture is given, in which the optimizing method addresses the obstacles in previous literature and produces a dependable result. The following is how the residue of the article is organised: Section 2 examines prior deep learning-based researches on the recognition of retinal disorders, whereas Section 3 discusses the issues in the retinal disease detection process, and Section 4 discusses the present research's proposed techniques, including algorithms and schematic explanations. The experimental results and discussion are described in Section 5, and the Section 6 provides the conclusion.

## II. RELATED WORKS

Some of the recent literatures that discusses about the detection of retinal disease is explained below and few of the existing literatures on detection of diabetic retinopathy disorder are framed in table.1.

(Pires et al. 2019) introduced a customized Convolutional Neural Network mechanism for distinguishing among referable and non-referable Diabetic

Retinopathy pictures. On the Messidor-2 dataset, the CNN was trained on Kaggle and attained an Area under ROC of 98.21 percent. (Hsieh et al. 2021) utilized three pre-trained Convolutional Neural Network models, Inception V3, Resnet152, Inception-Resnet-V2 to categorize Diabetic Retinopathy pictures as referable Diabetic Retinopathy or not. The Adaboost method was used to merge these Convolutional Neural Networks. They were able to achieve an Area under ROC of 94.6%. To categorise referable Diabetic Retinopathy images in a private dataset, (Liu et al. 2019) constructed a weighted pathways Convolutional Neural Network termed as WP-CNN. Their accuracy (ACC) was determined to be 94.23 percent. (Das et al. 2021) suggested two separate Convolutional Neural Network models to identify images as normal or Diabetic Retinopathy. On the DIARETDB1 dataset, their Convolutional Neural Network model has achieved an accuracy of 98.7 percent. Despite prior studies had successful outcomes in the detection of Diabetic Retinopathy disorder; they did not consider the five stages of Diabetic Retinopathy and their varied lesions. The binary classification technique's fundamental flaw is that it only groups the Diabetic Retinopathy pictures into two forms, disregarding the four states of Diabetic Retinopathy. The precise Diabetic Retinopathy stages must be identified in order to choose the appropriate treatment strategy and avoid retinal degeneration.

With the sensitivity of 96.8 percent to the pictures attained from the Messidor-2 dataset, a Convolutional Neural Network based Diabetic Retinopathy detector could properly determine referable Diabetic Retinopathy and cases on the threat of losing their sight. However, the system's efficiency in determining negative and low-quality photos is poor. For the semi-supervised data, (Cao et al. 2018) suggested a Multi-Instance Learning technique employing multiple kernels (MK-MLI) for predicting Haemorrhage-Microaneurysm (HMA) on the region of interest of fundus pictures acquired from the Messidor dataset. This approach has 91.6 percent accuracy, but it has several drawbacks, like difficulties finding information hidden beneath complicated structures and instantly collecting higher-order data. The candidate identification procedure in sparse Bayesian classification is a difficult operation to accomplish in a complex picture. (Molodij et al. 2014) proposed the Arteriolar-to-venular realistic identification technique. The early phases of hypersensitivity retinopathy are identified. As a result, a smaller proportion of pictures with a bigger retinal region are needed. The efficient method of SuperResolution (SR) revival was discussed by (Babacan et al. 2012). The micro-motion connectivity among hyperacuity and the human eye's retina are more accurate. There are several other forward-improving approaches with noise-suppression capabilities in it. There is a lower level of consistency attained. As a result, the super-resolution (SR) picture is dependent on the retina's micro-motion.

Recently reviewed retinal image improvement literature focused either on picture de-blurring or picture super-resolution. Various techniques for eliminating motion blur, improving contrast, and improving brightness of retinal fundus pictures have currently been presented. Contrast enhancement adaptive histogram equalisation (CLAHE) and Luminance gain matrix techniques have been offered as ways for enhancing luminosity and contrast (Zhou et al. 2017). To decrease the transparency and improve the sharpness of fundus pictures, (Mitra et al. 2018) employed the CLAHE and Fourier transform approach. (Xiong, Li, and Xu 2017) conducted the blurriness removing function by calculating the transmission map and backdrop illumination level. The previously disclosed approaches were confined to extremely particular scenarios since they required estimating the deterioration

model. (Williams et al. 2017) suggested a hierarchical CNN based system for classifying blurry and non-blurry photos, followed by image restoration. None of these strategies took spatial resolution into account as a degradation mechanism, nor could they test various types of blurring difficulties. Various fundus imaging super-resolution activities, on the other hand, have been completed.

(Bourouis et al. 2014) describe a novel innovation of a low-cost Mobile phone effective process with a microscopic lens which enables people in remote and inaccessible places to continue receiving eye checkups and illness diagnosis. The mobile diagnosis technology analyses the retinal pictures taken either by microscopic lens using an ANN method to recognise retinal illness situations. The embedded technique is used to improve the applications to enhance battery life and computational power. In Smartphone contexts, a switching frequency mechanism is also suggested to considerably increase the energy efficiency of the retinal scanning and diagnostic systems. According on overall findings of the analysis, the technology has competing retinal disease diagnosis accuracy higher than 87 percent. It can also identify retinal disorders sooner. (Mahapatra et al. 2017) developed a Generated Adversarial Network based methodology with retinal fundus imaging super-resolution that integrates saliency reduction for improved super-resolved photo quality. A progressively generative adversarial model was utilised to elevate fundus image database in a future review (Mahapatra, Bozorgtabar, and Garnavi 2019). Additional picture degrading models were not considered in such super-resolution studies. As could be observed, every one of those studies focused on a different aspect of picture super-resolution or blurs, and thus cannot be generalised for potential implementation.

The area identification structure for the registrations of retinal fundus pictures with greater resolution was described by (Ghassabi, Shanbehzadeh, and Mohammadzadeh 2016). In terms of consistency, rotational change, substance modification, and limited scale adjustment, the strategy provides good experimental findings. Nonetheless, multimodal identification of retinal images is not ever included. The retinal images including their blood vessels are segregated to use the segmentations. The SIFT analysis is used to estimate feature representations from the blood vessels of a retinal. As a result, this technique is preferred to physiologic and pathologic retinal images, but it has a higher computing complexity. (Chowdhury, Chatterjee, and Banerjee 2019) introduced an RF-based classifier to detect retinal abnormalities and provide doctors with a useful tool. The method has the important issue of falsely identifying the residual optic disc and blood vessels as lighter and darker lesion, lowering the software's accuracy significantly. To avoid the computation time of the SVM, (Singla et al. 2020) forecasted the Diabetic Retinopathy by assessing the microaneurysm and region of the fundus pictures utilizing Twin-SVM (TSVM) instead of a solo SVM. The TSVM is 4 times as quick as the standard SVM. The only factor influencing the TSVM's effectiveness is the amount of noise within database. (Kang, Fang, and Lai 2020) used an NB classification to tackle the DR problems by extraction textural properties in fundus images and classified them into 3 categories with a 93.44 percent ACC. Nevertheless, one drawback of this method is that it has low predictive accuracy when used to a limited database.

To diagnose eye illnesses, (H. Wang et al. 2000) used a Bayesian classification based on colour characteristics. They employed a complicated technique that integrated a lighting adjusting technique with classifications tasks and a validation approach depending on local



windows. The method had a decent rate of precision, but it required a lot of computational power. A multi-layer Neural Network was described for the identification of diseases in grey-scale retinal pictures (Gardner et al. 1996). Nevertheless, employing a wider dimensionality of inputs, the Neural Network-based technology has not been adequately assessed. (Rajalakshmi et al. 2018) analyzed the influence of an autonomous artificial intelligence model for Diabetic Retinopathy detection and sight threatening Diabetic Retinopathy identification and evaluated a mobile phone fundus photographic method for DR screening. Images were taken from enlarged patients' pupils to use the Remidio Fundus on Phone scanning gadget, portable fundus cameras, at a tertiary medical diabetes clinic in Madras. The EyeArt program examined the eyes of 296 individuals and assigned intensity ratings based on ICDRSS standards. The AI programme detected any DR with 96 percent sensitive and 80 percent specific and vision-threatening DR with 99 percent sensibility and 80 percent specificity, according to the findings.

(Kanagasingam et al. 2018) looked at how well the DL technology (Inception-V3) worked in patient healthcare. The classifier was tested using 30,000 photos from the public sphere (EyePACS, DiaRetDB1, and the Australian Tele-eye care Diabetic Retinopathy database), with ICDRSS criterion used to assess the degree of DR. A maximum of 193 diabetic patients were enrolled and 386 pictures were evaluated at a primary healthcare clinic in Western Australia. The analysis revealed that the specificity was 92 percent. (Ruamviboonsuk et al. 2019) used retina pictures from diabetic patients taking part in a countrywide screening programme to evaluate the effectiveness of the algorithm. There were 7517 individuals in the cohort, with 25,326 gradable pictures. The ICDRSS principles were used to classify DR and DME. The ratings assigned by a panel of foreign retina experts from the United States, India, Thailand and served as the basic method. The DL algorithm found attributable DR with a specificity of 97 percent, whereas regional grading identified it with a sensitivity of 74%. In terms of DME diagnosis, the DL algorithm exceeded individuals. The DL model, on the other hand, has significantly reduced particularities than human evaluators.

(Bellemo, Lim, Lim, et al. 2019) used DL to show the potentiality of AI in a Zambian setting. In the retinal fundus pictures from diabetic participants who took part in the SDRP, the group developed an ensembles DL models (VGGNet and ResNet). The DL method was then verified using retinal images of individuals with a self-reported diagnostic test who visited a portable testing facility in five cities in Zambia's Copperbelt area. A maximum of 4504 retinal fundus pictures was collected from 3093 pupils of 1574 Zambians having diabetic disease. For pertaining DR, the area under ROC of the Deep learning method was 0.973, with sensitivities of 92 percent and specificity of 89 percent. The diagnostic accuracy of vision-threatening DR was 99 percent, while DME sensitivities were 97 percent. (Hansen et al. 2015) utilized machine learning software to recognize sight-threatening Diabetic Retinopathy (moderate to severe Diabetic Retinopathy, and DME) in 6788 fundus pictures (3460 individuals) from the Nakuru Eye Study in Kenya. The obtained results are validated against Moorfields Reading Centre's grading, which followed ICDRSS norms. Overall, the sensitivity was 91 percent and the specificity was 70 percent.

(Hagos and Kant 2019) used the ImageNet database to trainngi InceptionNet V3 for five-class classifications using pre-training and obtained 90.9 percent accuracy. (Sarki et al. 2019) used ImageNet pre-train for training ResNet50, Xception Nets, DenseNets, and VGG

and attained 81.31 percent accuracy. Two research groups used databases provided by APTOS and Kaggle. (Selvathi et al. 2018) retrieved the characteristics from the full image to use a 2-D wavelet transforms and fed them into a neural network to training. They tested 45 photos from the HRF dataset and found that 95.8% of them were correct. (Maheshwari, Pachori, and Acharya 2016) used the wavelet technique to breakdown the retinal picture and then retrieved 12 core entropy characteristics from 4 separate colour channels - green, red, purple, blue, and greyscale. Lastly, the characteristics acquired were fed into a least squares support vector machine. The RIM-ONE database revealed an accuracy of 81.3 percent. (Guo et al. 2018) used U-net for separating the Optical Disk and Optical Cup regions, then retrieved 8 morphologic characteristics and submitted it to a RF classifier as an input. They used the ORIGA dataset to test and got an accuracy of 76.9% and an AUC of 83.1 percent. (Chakravarty and Sivaswamy 2016) utilized the Hough transform to determine the OD region, retrieved the projected textures and baggage of keywords characteristics from the identified OD, and then constructed a Classification model to distinguish among normal and glaucoma OD. On the DRISTI-GS1 dataset, they achieved an accuracy of 76.8% and an area under ROC of 78.0 percent.

(Abràmoff et al. 2018) studied a Deep Learning based method (Inception-V3) for the diagnosis of eyesight Diabetic Retinopathy, described as pre-proliferative Diabetic Retinopathy at worst, or DME, as measured by the NHS scales. The system was trained using 71,043 pictures obtained from LabelMe, which were rated by 27 ophthalmologists and a professional ophthalmologist. The DL technique was originally evaluated on 19,900 LabelMe pictures, yielding AUC, sensitivities, and specificity of 0.989, 97 percent, and 91 percent, correspondingly, for vision-threatening DR. Following that, the model's system was assessed on an adequate sample size of 35,201 pictures of Native Australians from the National Indigenous Eye Health Survey, Malays from the Singapore Malay Eye Study,. For AUC, sensitivity, and specificity, the overall classification efficiency for vision-threatening DR identification was 0.956, 93.0 percent, and 99.1 percent, correspondingly. (Priya and Aruna 2012) suggested utilizing colour fundus pictures to detect diabetic retinopathy phases using a computer vision-based technique. On a test set of 250 photos, they were able to extract attributes from the original picture utilizing image processing mechanisms and feed it into the support vector machine classifier for binary categorization, with accuracy, specificity and sensitivity of 97.6 percent, 96 percent, and 98 percent respectively.=

(Bajwa et al. 2019) was using a three-step process to place and retrieve the Optic Disk region: first, a region proposal system was being used to create a random number of rectangle objects, then the filtration pictures were given to a Convolutional Neural Network for discovering the objects with the best rating, and eventually, the bounding box regression has been utilized to pinpoint and retrieve the Optic Disk portion. The Optic Disk picture was classified in the second step using a CNN model. They attained sensitivities of 71.2 percent and an AUC of 87.4 percent on the ORIGA database. (Juneja et al. 2020) used the DRISHTI-GS database to estimate CDR after employing a U-net algorithm to partition the Optic Disk and Optic Cup; they observed mainly Optic Disk and Optic Cup classification with levels of accuracy of 95.8% and 93.0%, accordingly. (Karkuzhali and Manimegalai 2017) evaluated CDR, inferior-superior-nasal-temporal (ISNT), distances from central Optic Disk to optic nerve head, amount of blood vessels within optic nerve head, and the graylevel value among central Optic Disk and optic nerve face using superpixel segmented. To detect the issue,

neural networks were trained utilizing measures as characteristics and achieved 100% accuracy on 26 photos. Verifying on a limited collection of pictures, unfortunately, restricted the findings. (Mohamed et al. 2019) used simple linear popular technique superpixels to separate the Optic cup and Optic Disk regions after pre-processing the images to eliminate noise and improve contrasts. Finally, CDR was used to assess whether or not glaucoma was present. They found that non-glaucomatous images had a CDR around 0.4 and 0.6, but glaucomatous images had a CDR higher than 0.6.

(Orlando et al. 2017) manually clipped the region of Optic Disk before capturing the blood vessels and enhancing the contrast. The deep active attributes were then retrieved via VGG-S and OverFeat pre-trained systems and fed into a logistic regression framework. For the DRISTI-GS1 dataset, they attained an AUC of 76.26 percent. (Gómez-Valverde et al. 2019) presented five Convolutional Neural Network models based upon typical Convolutional Neural Networks—ResNet50, VGG19, GoogleNet and DENet, of which VGG19 scored well for the RIM-ONE dataset, having the sensitivity of 87 percentage, specificity of 89 percentage, and Area under ROC of 94 percent. MI-GAN was proposed by (Bellemo, Burlina, Yong, et al. 2019) for producing different medical pictures and associated segmentation coverings from a small amount of training data. The researchers designed a style transfer version that took into account the STARE and the DRIVE databases. They upgraded the generator 2 times as much as the discriminator for achieving faster resolution and a considerable reduction during the entire training time. When employed as an extra training dataset, the system improved the performance for image segmentation. (Asaoka et al. 2019) used the entire retinal images for pre-training the network based upon the ResNet framework. Employing 1768 normal eye images and 1364 glaucoma pictures from a local dataset, researchers were able to get an area under ROC of 94.8 percent.

Deep Convolutional Neural Networks are often used separately for categorization via transfer learning or finely-tuning the weights, according to some research. Individual deep Convolutional Neural Network, on the other hand, would yield inconsistent outcomes since deep Convolutional Neural Network models are rule-based approaches for constructing and predicting the parameter space. Deep CNN ensembles have been proved to be highly accurate and efficient than single Convolutional Neural Network ensembles. (Guibas, Viridi, and Li 2017) suggested a two-stage pipeline that comprising a DCGAN framework trained for synthesizing the ocular capillaries from noise and a second cGAN (Pix2Pix) trained on Messidor fundus pictures for generating the equivalent colour fundus picture. The researchers used the similar U-Net for training with the pair of real pictures and pair of synthetic images from DRIVE to measure the accuracy of the simulated data. They discovered that training with purely synthetic data produces only marginally poorer results by calculating F1 scores. Researchers also used the KL divergence score for calculating the differences between the actual and synthetic datasets, demonstrating that such synthetic data are distinct from the actual data and therefore don't replicate the original photos.

(Hemanth, Deperlioglu, and Kose 2020) proposed a hybrid algorithm to identify and classify the diabetic retinopathy disorder that used image processing and deep learning mechanism. The framework was tested utilizing the MESSIDOR database's retinal fundus dataset, which consisted of 400 pictures and yielded positive results. (Lunscher et al. 2017) created a computer-aided screening method which facilitated in the analysis of fundus

pictures with various lighting and angles. Machine Learning models were used to help identify the severity levels of Diabetic Retinopathy disorder in this investigation. To identify retinopathy lesion occurrences from non-lesions, the system utilized the AdaBoost classifier for extracting the features and K-nearest neighbour, Support Vector Machine and Gaussian Mixture Model to analyze the data.

For discovering the blood vessel, (Kavitha and Devi 2005) offer median filtering operation and morphological processes. They retrieve brighter regions by considering it as the optic disc or exudates using the multilevel thresholding. They identify the optic disc as the blood vessel convergence point, and then designate the other light areas as exudates. On low-contrast photos, the approach shows poor performance. The processes of region growing and for thresholding are simple, but choosing region seed points, threshold values, and the stopping criteria might be tricky. (Ege et al. 2000) employ a median filter for eliminating the noise, thresholding for segmenting the brighter and darker lesions, region growing operation, and Mahalanobis, Bayesian, and nearest neighbour classifiers for the detection of exudates regions. In low-quality photos, the technique was failed in exudate identification. (Zhu et al. 2019) suggested a technique for the classification of hyperspectral image that uses a Convolutional Neural Network and real capsule architecture as a 1D deep capsule architecture and a 3D deep capsule architecture. But, no effort was made to investigate the use of CapsNet in the classification of Diabetic Retinopathy.

**Table 1: Existing literatures of research on retinal disease detection**

Reference	Method	Drawback
(Pratt et al. 2016)	Convolutional Neural Network	The network found it difficult to learn deep sufficient attributes to recognize some more complex components of DR
(Carrera, Gonzalez, and Carrera 2017)	Support Vector Machine	It will not detect soft exudates and so the reduced accuracy
(Lam et al. 2018)	Binary classification method	It only categorize as DR or not DR but not all the five stages of DR
(Bellemo, Lim, Rim, et al. 2019)	Generative Adversarial Networks	As GAN could only handle retinal images with resolutions often lesser than those supplied by existing retinal fundus imaging, the synthesized datasets may be of bad quality
(S. Wang et al. 2021)	GAN	The output images has blurry and discontinuous edges which is not similar to that of the real fundus image dataset
(Gadekallu et al. 2020)	PCA + Firefly algorithm + Deep Neural Network	It will not provide optimal solution for better classification accuracy

### Key contribution of the research

Most of the literature on the subject divides the condition into two categories: healthy eyes and diabetic retinopathy-defective eyes. The present study's goal is to distinguish between the non-proliferative and proliferative phases of diabetic retinopathy. Normal (Healthy) eyes, mild, moderate, and severe NPDR, and PDR are the five types of eyes. Furthermore, one of the best scopes that have been explored in this work is retrieving manually made features from real photos after various processing.

The major contributions of the study is given as follows

- At first, the data set is trained in the proposed AB-DCNN model
- Consequently, the pre-processing is accomplished through the Gaussian filter for noise removal and enhancing the image and make it suitable for further processing steps
- The AB-DCNN mechanism extracts the relevant attributes accurately from the pre-processed picture and detects the retinal disorder and classify the stages of DR disorder more precisely
- Several key responsibilities in diagnosing and interpreting retinal disorders include separation of the optic disc (OD), retinal blood vessel, and optic cup (OC) using fundus pictures and retina layers in OCT pictures. The anatomy of the retina blood vessels alters when illnesses like DR are present. Because of the existence of glaucoma, the cup-to-disc proportion is modified. After separation, the density of retina layers can also be used to detect glaucoma
- Disease parameters are estimated, including as glaucoma diagnosis, DR stage grading, and AMD identification. The appearance of red lesions in the fundus pictures (micro-aneurysms, haemorrhage) is a helpful indicator for Diabetic Retinopathy grading
- Image enhancement evaluation, colour reproduction progression (deblurring, denoising of OCT pictures, super-resolution of fundus pictures), digital picture generation (to decrease the low database issue in medical imaging), and so on are some of the other tasks

### III. PROBLEM STATEMENT

Since before the Deep Learning era, synthesising accurate pictures of the ocular fundus has been a difficult undertaking. Recently, technological advancements have resulted in significant processing capacity, allowing Machine learning to progress to Neural networks with deep architectures. The quick improvement of the Deep learning mechanism aided in the creation of realistic-looking pictures, resulting in a technically stable and visually acceptable coloured retinal fundus picture. Screening for glaucoma in its earlier phases is difficult because it consumes more time, subjective, and labor-demanding, and there aren't enough eye experts (Sreng et al. 2020). Prior literature had excellent performance in recognizing Diabetic Retinopathy, but they didn't account for the 5 stages of DR and the varied lesions (Lam et al. 2018). The binary classification method's fundamental flaw is that it only categorizes DR pictures into two groups, ignoring the five stages of DR (Alyoubi, Abulkhair, and Shalash 2021). In (Kumar, Chatterjee, and Chattopadhyay 2021), since it uses cross datasets it would take larger computation time and hybrid DL mechanism make the model more complex.

The study's purpose is to create a model which could categorise DR pictures into five categories and has great result. Color fundus photos from five separate databases were used. The following are the major challenges: It achieved excellent outcomes when the picture had a high resolution. While developing the models, though, it necessitated a lot of computing power. Utilizing low-resolution photos, on either hand, resulted in poor simulation results. Additionally, photos with distortion and a wider availability among classifications may have an impact on the model's effectiveness. Multiple image classification techniques led to substantial improvements when used with certain databases, but applying the similar approach to different areas and database was a hurdle in machine learning and picture analysis. The determination of the exact eye disease is significant for choosing an appropriate treatment process and for the prevention of retinal deterioration. The use of deep learning mechanisms is significantly reduced due to the models' ambiguity and vulnerability in making incorrect decisions in complex situations (Singh et al. 2021). To address all of these concerns, several changes were made to the deep learning framework, which are described in detail below.

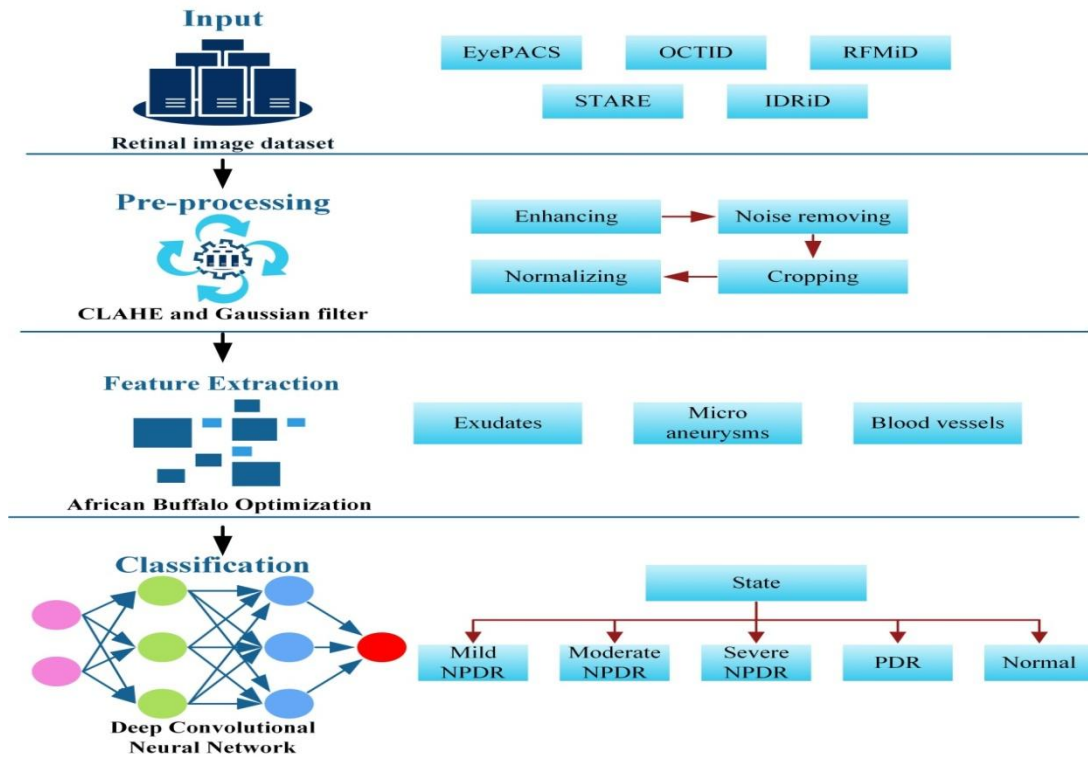
#### IV. PROPOSED AB-DCNN METHODOLOGY

The work represents the construction of a convolutional neural network that can diagnose retina illness and phases of diabetes retinopathy using colour fundus images as input. The proposed method uses an optimization mechanism along with the deep learning approach to make the design free from the fore-mentioned problems. The proposed mechanism's processing steps contains 4 phases namely, the Data gathering, Pre-processing, Feature extraction, and categorization followed by the performance evaluation. It utilizes a novel African Buffalo optimization mechanism based deep CNN (AB-DCNN). The ABO mechanism accomplishes the feature extraction operation followed by classification using the deep neural network model.

**1. Working of AB-DCNN mechanism:** The approach for establishing and verifying the suggested AB-DCNN technique and its various processing stages are depicted in Figure 2. The initial step was to gather fundus photos from multiple resources into a huge database that included both publicly available database and the unique database. The fundus photographs were then pre-processed, which included manually removing fundus images which were not suitable for diagnostic due to poor quality, as well as reducing images from various providers to a suitable size. The AB-DCNN methodology was built on the training and validation data in the third phase. The training dataset was used to optimise the model's learnable parameters, while the validating dataset was utilised to identify the best configurations of the hyper-parameters (such as training data, batch size, and velocity) using a randomized selection method. The ideal hyper-parameters are a set of hyper-parameters that allow the AB-DCNN modelling to get the best Area under curve on the testing dataset. In the final step, it is examined the completed model's potential to recognize 6 prevalent ocular diseases, varying severity levels of DR, and 36 various kinds of fundus aberrant abnormalities or disorders using internally and primary exterior testing dataset. The various stages and their severity levels of Diabetic retinopathy disease are shown below in table 2.

**Table 2: Classifying the stages of Diabetic retinopathy disorder**

Severity level	Stage
Mild NPDR	initial stage of DR
Moderate NPDR	progressive stage of DR
Severe NPDR	Severe stage of DR
PDR	Advanced stage of DR
Normal	-



**Figure 2: Processing phases of proposed AB-DCNN model**

- Data collection** The retinal fundus images are gathered from the online datasets. Datasets are utilized for training the model for detecting the referable retinal disorder. Four publicly available datasets namely, Optical Coherence Tomography Image Database (OCTID), Retinal Fundus Multi-Disease Image Dataset (RFMiD), STARE dataset, and Indian Diabetic Retinopathy Image Dataset (IDRiD) are utilized for training and validating the proposed model. Totally, 574 retinal fundus images are taken for analysis. Among which, 460 images are utilized for training and the residual of which are utilized for testing. Both the divisions comprise of normal fundus images as well as the diseased images like Macular hole (MH), Age-related Macular Degeneration (AMD), Central Serous Retinopathy (CSR), and Diabetic Retinopathy (DR). Total number of training and testing data for five cases is illustrated in table 3.

**Table 3: Datasets used for retinal disease detection**

Dataset	DR	CSR	AMD	MH	Normal	Total
Training	45	81	85	83	166	460

<b>Testing</b>	12	19	20	21	42	114
<b>Total</b>	57	100	105	104	208	574

- 3. Pre-processing:** Pre-processing is an essential phase for the enhancement of the retinal image quality and proceed to the successive phases with improved performance. The contrast of the fundus picture is improved through pre-processing. The datasets came from a variety of real-world sources, and their properties represent that some photographs are out of focus and have incorrect illumination, or contain noise and distortions that are irrelevant to the analysis. Such poor quality fundus images must be removed from those approaches to guarantee that they are not mistaken for abnormal pictures.

Pre-processing was carried out in two stages. The first is generic pre-processing, that is implemented to all of the dataset's pictures. The subsequent procedure is to accomplish specialised pre-processing based upon the attributes that will be retrieved. Green channel extraction, Resizing, and Contrast Limited Adaptive histogram equalization (CLAHE) are all part of the basic pre-processing stage. The real pictures are 1024x1024 pixels in size. Because the dataset is large, the photos are saved in.jpeg format with a resolution of 300x300 pixels to reduce computing time. Certain information such as the blue and red components of the picture is typically eliminated before processing for enhancing the contrast of retinal pictures. The green channel is commonly utilized in pre-processing because it shows the best vessels or background contrast as well as the highest contrast among the retinal tissue and the optic disc. The red channel is pretty bright, and the choroid's vascular arrangement may be seen. The retinal vessels are visible as well; however they have lower contrast than the green channel. The blue channel is noisy and lacks information. For contrast enhancement, CLAHE (Contrast limited adaptive histogram equalisation) is applied. It makes various image histograms and utilizes them to reassign the image's pixel intensity. As a result, CLAHE is better at improving edge improvement and regional contrast in every image region. The morphological procedure, median filter operation, and thresholding are used to accomplish particular pre-processing for the detection of exudates. The discovery of blood vessels and microaneurysms comes next.

**Detection of exudate:** Morphological dilation is accomplished through a 6x6 elliptical shaped structural component. For the reduction of noise, a non-linear median filter is utilized. The exudate intensity is much higher. Therefore, thresholding was utilized for extracting it. Followed by this pre-processing operation, the pixels with a luminance higher than 235 are converted to 255, and the residual are changed to 0. Then the region of exudates is found by the image traversing function.

**Detection of blood vessel:** The blood vessel is one of the most significant criteria for identifying diabetic retinopathy stages. After capturing the green channel picture and improving the image contrast, a variety of strategies have been used to eliminate blood vessels. In the picture, an alternative sequential filtering is used, with ellipse shaped and 3 distinct sized structural elements (5x5, 11x11, and 23x23). The generated picture is then deducted from the actual one. There are numerous minor sounds in the deducted image. Area parameter noise removal is utilized for eliminating such turbulences. The findContours() function is used for discovering the contours of every element, such as



sounds, and the `contourArea()` function is used for calculating the contour area and eliminate noises with an area equal to or greater than 200 pixels. The picture is then binarized by applying a threshold value. Finally, the no. of pixels required to cover the area of blood vessel is evaluated.

***Detection of microaneurysm:*** Microaneurysms are extracted from the green region of the RGB value. CLAHE is utilised for improving the contrast. The noise would then be discarded utilizing a median filter. For morphological operation, a  $7 \times 7$  elliptical-shaped parametric model is utilized. After the application of the morphological erosion process, the image is inverted. Morphological closing operation is utilised to link the discontinuous portions of blood artery. Subsequently, the picture was binarized. As the haemorrhage, blood vessel, and microaneurysm all have nearly the similar intensity, the binarized picture would identify all three elements simultaneously. As the microaneurysms are minor, the contour area was utilized for extracting them. The LBP texture descriptor is based on two attributes: shape and blood vessels. For detection of shape, the subsequent pre-processing procedures are utilized: Converting a colour picture into a grayscale picture is the starting stage. The grayscale picture is then filtered with a median filter in the next stage. The filtered picture is then applied with an adaptive histogram equalisation mechanism called the CLAHE (Zhou et al. 2017). The CLAHE enhanced picture is again given to another filter called the gaussian filter to remove even more noise. On a contrast enhanced picture, shade correcting function is applied. A big median filter is used to examine the posterior part of the picture during the shade correction operation.

The picture is then normalised, and the blood vessels could be observed using the morphological approach, which is the black top-hat operation. Blood vessels are another characteristics required for description of textures. The procedures for detecting blood vessels are as follows. The first step is to change a colour picture into grayscale. Implementing a gaussian filter to the grayscale picture is the final process. The picture is then processed using the CLAHE approach. The variation among the grey and median filtered images is then calculated, and the binary picture is obtained. The morphological dilation procedure is used, and the binary picture is converted to grayscale once more. Furthermore, the areas captured by fundus pictures are highly varied, owing to the various fundus cameras and configurations, which could allow the network to learn properties that are unrelated to illness detection. As a result, every fundus photos were clipped to save the equivalent amount of space and the picture sizes were standardised to 800 pixels wide and 660 pixels tall, respectively. In a pilot research, we explored picture resolutions varying from  $32 \times 32$  pixels to  $640 \times 640$  pixels for determining the best input picture quality for loading into the system. The maximum area under receiver operating curve was attained with a picture quality of  $256 \times 256$  pixels, according to the findings. As a result, when putting the fundus images into the AB-CNN model for training or interpretation, it is reformatted into  $256 \times 256$  pixels.

- 4. Feature extraction and classification:** Feature extraction is used to extract the essential features for categorization purpose. The primary concept behind feature extraction is to capture significant features or characters like shape, colour and boundaries, etc. Extraction of features could be accomplished using African Buffalo Optimization

mechanism (Odili, Kahar, and Anwar 2015). In the final part of the AB-DCNN model, the African buffalo optimization mechanism is used as an optimizer. The ABO mechanism attracts its inspiration from the African buffalo's characteristics in the wide savannah regions and the African forests. Since they search and trace the lush green pastures in different parts of Africa to satisfy their large appetites. Likewise, this mechanism traces the location of affected part in the retinal image using their fitness function. Some of the important features need to be identified for classifying the diabetic retinopathy disorder are Area of Exudates, Area of Micro aneurysms, Area of Blood vessels. It has been discovered through research into related studies that using deep learning-based classifiers for hand-crafted characteristics from unprocessed photos yields better accurate forecasting. An optimization strategy implemented in a deep convolutional neural network model was chosen for the research depending upon the findings.

***African Buffalo Optimization (ABO) mechanism:*** The ABO is a community stochastic optimization method inspired by the behaviour and attitude of African buffalos, a genus of wild cows comparable to domestic cows that traverse thousands of kilometres through African tropical rainforests and scrubland by travelling together and in large herds of up to a hundred buffalos. Their travel is motivated by a desire to find abundant grazing pastures. They tend to follow the wet weather to find abundant grazing meadows. Because the seasons vary from place to place across Africa's huge expanse, buffalos are constantly on the move in search of their preferred meadows. ABO algorithm is focused to analyse how buffalos use different modes of communication to organise themselves. They have utilized various modes of sounds to indicate the danger zone, good and bad area of grazing fields and to encourage their herds to stay and take use of the present resources. The 'waa' sound alerts buffalos to the existence of attackers or a paucity of pastures, prompting the herds to move on to safety or more profitable regions of the grassland. Once this cry is issued, the animals are instructed to remain vigilant and find a secure or better grazed field. The 'maa' sounds, on the other side, are being used to advise buffalos to relax because there are plenty of grazing pastures nearby and the environment is suitable to grazing. The herds are able to utilize their requirement for food sources using these signals.

Furthermore, it's learning factors assists in processing the buffalo movement. The helpful behaviour of buffalo is upgraded through  $le_1(\beta_p^{targ} - w_f)$  and the buffalo's intelligence is denoted by  $le_2(b_{p_{max}.f} - w_f)$ . Also, the fitness value is computed through eqn. (1).

$$m_{f+1} = m_f + le_1(\beta_p^{targ} - w_f) + le_2(b_{p_{max}.f} - w_f) \quad (1)$$

Here  $m_{f+1}$  denotes the next feature, also  $m_f$  represents the current feature value. In addition, new feature update is deliberated using Eq. (2).

$$w_{f+1} = \frac{w_f + m_f}{\lambda^*} \quad (2)$$

Where  $w_f$  and  $m_f$  indicate the respective exploration and exploitation fitness of  $f$ .

Thereby, it provides the best optimal feature set for making the classification accuracy higher. The Pseudo code of the African buffalo optimization mechanism is discussed below in algorithm 1.

**Algorithm 1: African Buffalo Optimization mechanism**

Function  $f(n) = (f_1, f_2, \dots, f_n)^k$

Place buffaloes in solution path

Input fitness values used Eq. (1)

Location Update  $\beta_p^{\text{arg}}$  and  $b_{p_{\text{max}.f}}$  using eqn. (2)

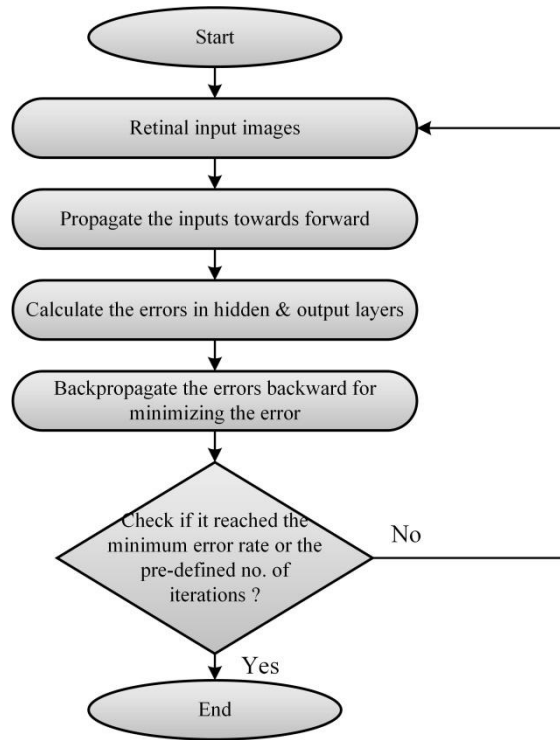
If  $b_{p_{\text{max}.f}}$  provides Yes, then proceed.

If  $b_{p_{\text{max}.f}}$  provides No, then back with initial step

Stopping procedure not performs, and then starts with fitness step

Get Output

The classification of diabetic retinopathy is accomplished through Deep Convolutional Neural Network mechanism. The delicate features included in the categorization tasks such as exudates, micro-aneurysms, and haemorrhages on the retina could be identified using deep convolutional neural network model resulting in an automated assessment. CNNs could be trained to recognize the symptoms of Diabetic Retinopathy in fundus pictures. The flowchart for detecting the retinal disease is represented below in Figure.3.



**Figure 3: Flowchart for training AB-CNN model**

The working of the proposed AB-CNN mechanism is represented below in algorithm 2.

**Algorithm 2: Working of AB-DCNN mechanism**

**Input:** Input retinal image

**Output:** Classification of DR classes

Import the data in the AB-DCNN model

Data is pre-processed

// image enhancing (CLAHE)

// noise removal (Gaussian filter)

// cropping

// normalizing

Feature extraction by African Buffalo

// Area of Exudates

Optimization mechanism

// Area of Micro aneurysms

// Area of Blood vessels

Classifying the stage of DR by Deep CNN

// Mild NPDR

// Moderate NPDR

// Severe NPDR

// PDR

*// Normal*

*Classify the retinal disease as AMD, MH,  
DR, CSR*

*Performance Evaluation*

Initially, the input retinal Image dataset is trained in the system. Subsequently, pre-processing is accomplished for enhancing the image quality for further processing. Followed by this, the core important step called feature extraction is performed for classification purpose. It is accomplished through African Buffalo Optimization (ABO) mechanism. Finally, the classification step is done to categorize the stages of Diabetic Retinopathy. It is accomplished through the Deep Convolutional Neural Network mechanism. The novel mechanism could offer an automated system for DR detection with Very high accuracy, instantaneous reporting of results, Consistency of interpretation (the algorithm will make the *same* prediction on a specific image every time).

## V. RESULT AND DISCUSSION

### Steps for performance evaluation

- Split the examples into training set X and test set Y randomly
- Use training set X to learn the model
- Evaluate using the testing set Y

The suggested methodology is dependent on the design of a Convolutional neural network. The design is comprises of convolutional layers that convolutions the input before passing it on to the pooling layer. The technique is repeated hundreds to thousands of times to feature extraction. As a result, the model is capable of extracting several characteristics from each input. The retinal picture is transformed to a grayscale picture and then pre-processed to retrieve the characteristics using the developed model. The African Buffalo Optimization algorithm is utilized to detect the attributes. Deep Convolutional Neural Networks are utilized for classifying the data. A total of 574 photos are taken, with 114 images being used for tests and the rest being used for training. The testing process takes longer than the training stage. The rate of learning is assumed to be 0.1. MATLAB was used to generate the simulations findings. Table 4 shows the comparison of datasets in existing deep learning mechanisms for classifying retinal diseases.

**Table 4: Comparison of datasets in existing deep learning mechanisms for classifying retinal diseases**

References	Dataset used	Lesion detection
(Wan, Liang, and Zhang 2018)	Kaggle	No
(Jiang et al. 2019)	Private dataset	No
(J. Wang et al. 2020)	Private dataset	Red lesion

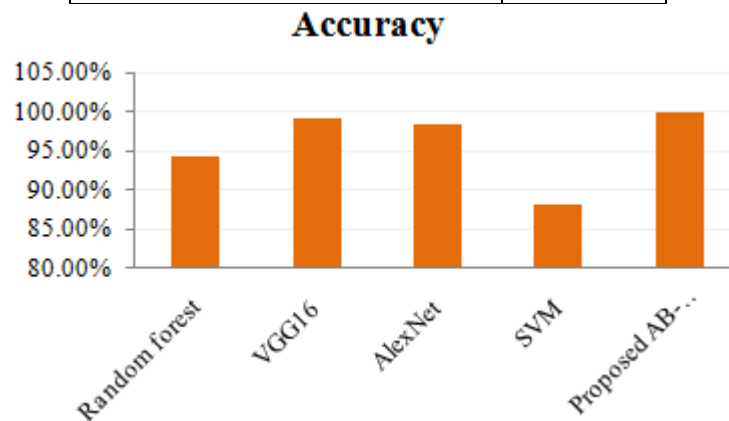
Proposed AB-DCNN model	5 datasets	Yes
------------------------	------------	-----

- 1. Performance evaluation:** Performance criteria like accuracy, recall, precision, F1-score, sensitivity, and specificity are utilized for calculating the suggested technique's effectiveness and reliability.
- 2. Accuracy:** The simplest intuitive performance metric is accuracy, which is expressed to be the proportion of precisely predicted observations to all observations. The proportion of precisely categorized patterns to the total no. of classified patterns is known as accuracy. It is calculated using eqn. (3) as follows,

$$Accuracy = \frac{tp + tn}{tp + fp + tn + fn} \quad (3)$$

**Table 5: Accuracy Comparison of existing deep learning mechanisms for classifying retinal diseases**

Methods	Accuracy
Random forest	94.2%
VGG16	99.17%
AlexNet	98.32%
SVM	88.25%
Proposed AB-DCNN model	99.82%



**Figure 4: Comparison of Accuracy**

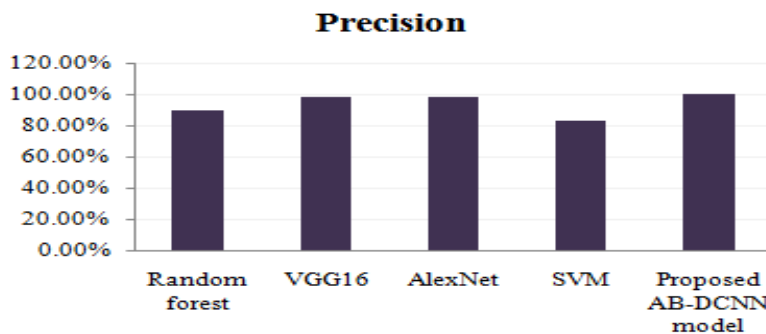
Table.5 represents the accuracy comparative analysis of the prevailing and the proposed approaches and its graphical representation is shown in fig.4.

- 3. Precision:** Precision is measured by the amount of positive class predictions which belongs to the positive class. Precision is expressed to be the ratio of the rate of correct classification of events among every detected event. It is computed using eqn. (4) as,

$$Precision = \frac{tp}{m + fp} \quad (4)$$

**Table 6: Precision Comparison of existing deep learning mechanisms for classifying retinal diseases**

Methods	Precision
Random forest	89.4%
VGG16	98.32%
AlexNet	98.32%
SVM	83%
Proposed AB-DCNN model	99.67%



**Figure 5: Comparison of Precision**

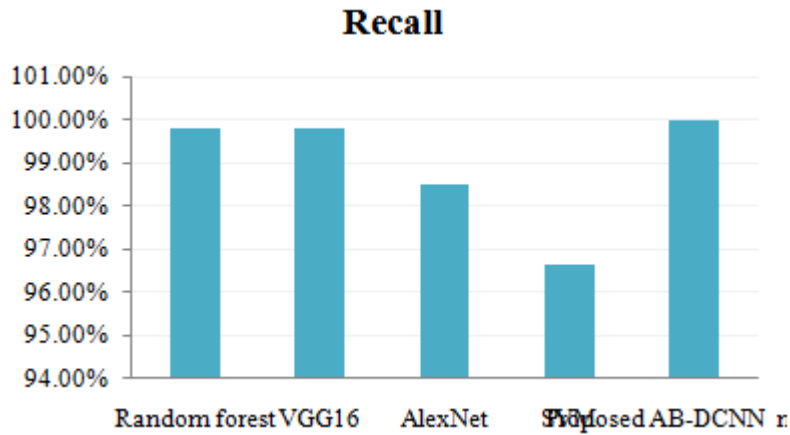
Table.6 represents the precision comparative analysis of the prevailing and the proposed approaches and its graphical representation is shown in fig.5.

- 4. Recall (or) Sensitivity:** Recall is described as the amount of positive class predictions that are made out of all positive examples in the dataset. The fraction of right events among all events is known as recall. It is calculated using eqn. (5) as follows,

$$Recall = \frac{tp}{tp + fn} \quad (5)$$

**Table 7: Recall comparison of existing deep learning mechanisms for classifying retinal diseases**

Methods	Recall
Random forest	99.80%
VGG16	99.79%
AlexNet	98.5%
SVM	96.63%
Proposed AB-DCNN model	100%



**Figure 6: Comparison of Recall**

Table.7 represents the recall comparative analysis of the prevailing and the proposed approaches and its graphical illustration is shown in fig.6.

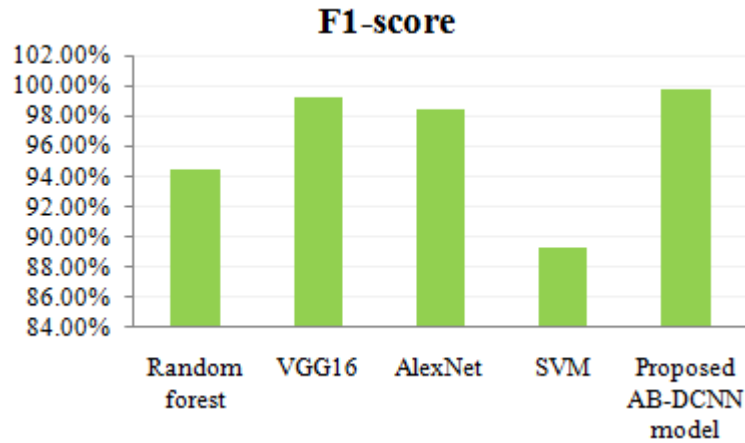
5. **F-measure:** F-measure is the degree of harmonic mean among recall and precision. It is the statistical degree utilized to rate the performance. F1-score is formulated in eqn. (6) as,

$$F - measure = \frac{2 \times Precision \times Recall}{Precision + Recall} \quad (6)$$

**Table 8: F1-score Comparison of existing deep learning mechanisms for classifying retinal diseases**

Methods	F1-score
Random forest	94.4%
VGG16	99.2%
AlexNet	98.42%
SVM	89.24%
Proposed AB-DCNN model	99.71%





**Figure 7: Comparison of F1-score**

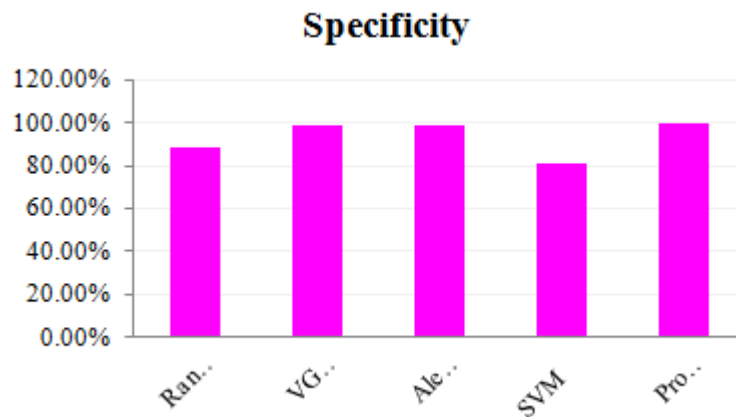
Table.8 represents the precision comparison of the prevailing and the proposed approaches and its graphical illustration is shown in fig.7.

6. **Specificity:** Specificity is described as the amount of negative class predictions that are made out of negative examples in the dataset. It's the probability that the screening process would accurately determine a disease-free person. It is calculated using eqn. (7) as follows,

$$\text{Specificity} = \frac{tn}{tn + fp} \quad (7)$$

**Table 9: Specificity comparison of existing deep learning mechanisms for classifying retinal diseases**

Methods	Specificity
Random forest	88.74%
VGG16	98.38%
AlexNet	98.43%
SVM	80.51%
Proposed AB-DCNN model	99.43%



**Figure 8: Comparison of Specificity**

Table.9 represents the precision comparison of the existing and the proposed approaches and its graphical representation is shown in fig.8.

## VI. DISCUSSION

Due to its significance in supporting ophthalmologists in screening glaucoma illness in a simpler and cheaper manner, a computerized retinal disease diagnosis system is an important function in saving people's vision. Due to the usage of diverse datasets and the absence of a consistent system for comparisons, the analyzed outcome is not always the greatest when compared to the preceding techniques. To make the verification requirements easier, all of the suggested methodologies' findings and results were matched to those of other studies and used the similar experimental results. Due to parameter sharing and reduced connectivity, the Convolutional Neural Network detects straight from image pixels with minimal pre-processing and greatest result utilising small parameters. The research offered a Deep learning model for retinal diagnosis that is both ambiguous and understandable. The end-user can deduce which areas the system examined and how confident the algorithm is in its projections before making a final decision. Splitting situations with higher levels of uncertainty for referrals might also aid predictive accuracy and establish credibility. These charts show how effective uncertain data is. Rather than misidentifying, reporting unclear pictures to a doctor can improve patient safety by improving assurance in the operating platform. Several broad conclusions concerning the link among ambiguity and the traits emphasized by solutions could also be reached. Cases with more variation between the components appear to be categorized more accurately. Clinicians also take into account the darkened areas, such as fluid build-up and new blood vessel shadowing. Ultimately, there is a link among a deep learning model's uncertainties, justifications, and reliability for retina OCT pictures. The work is a preliminary analytical study that results in various subjects for additional investigation.

## VII. CONCLUSION

On the premise of fundus pictures, the suggested methodology obtains greater precision, sensitivity, and specificity scores in identifying retinal disorders. It also overcomes

all the limitations in the existing model and it effectively detects and classifies the stages of DR disorder. The present work offers an efficient complete automatic screening model for assisting in the diagnosis of retinal disorders and it is cost-effective. The technique is more accurate than previous machine learning algorithms and takes less time. It also consumes massive volumes of information and works admirably, necessitating less picture pre-processing in the presence of noisy data. It suggests that such a model could be a useful and cost-effective tool for ophthalmologists to improve existing clinical pathways for identifying retinal illness phases in a less affordable and quicker manner. Future research is required to assess the usefulness of the Deep Learning approach in retinal illness screenings employing hybrid optimization techniques to enhance the program's reliability and efficiency.

Future research could extend the technique to a wider range of topics in order to improve deep neural networks for practical uses. This data could be utilized for improving the resilience of a model by changing the characteristics it learns. Additional approach might be to measure diseased traits like the light and density of the retinal pigment epithelium then link these to explanation and uncertainties. The fundamental impediments to acceptability of deep learning approaches in numerous areas, particularly medical diagnosis, could be overcome by developing uncertainties conscious and understandable systems.

## REFERENCES

- [1] Abramoff, Michael D., Philip T. Lavin, Michele Birch, Nilay Shah, and James C. Folk. 2018. "Pivotal Trial of an Autonomous AI-Based Diagnostic System for Detection of Diabetic Retinopathy in Primary Care Offices." *NPJ Digital Medicine* 1 (1): 1–8.
- [2] Alyoubi, Wejdan L., Maysoun F. Abulkhair, and Wafaa M. Shalash. 2021. "Diabetic Retinopathy Fundus Image Classification and Lesions Localization System Using Deep Learning." *Sensors* 21 (11): 3704. <https://doi.org/10.3390/s21113704>.
- [3] Asaoka, Ryo, Masaki Tanito, Naoto Shibata, Keita Mitsuhashi, Kenichi Nakahara, Yuri Fujino, Masato Matsuura, Hiroshi Murata, Kana Tokumo, and Yoshiaki Kiuchi. 2019. "Validation of a Deep Learning Model to Screen for Glaucoma Using Images from Different Fundus Cameras and Data Augmentation." *Ophthalmology Glaucoma* 2 (4): 224–31. <https://doi.org/10.1016/j.ogla.2019.03.008>.
- [4] Babacan, S. Derin, Reto Ansoerge, Martin Luessi, Pablo Ruiz Matarán, Rafael Molina, and Aggelos K. Katsaggelos. 2012. "Compressive Light Field Sensing." *IEEE Transactions on Image Processing* 21 (12): 4746–57.
- [5] Bajwa, Muhammad Naseer, Muhammad Imran Malik, Shoaib Ahmed Siddiqui, Andreas Dengel, Faisal Shafait, Wolfgang Neumeier, and Sheraz Ahmed. 2019. "Two-Stage Framework for Optic Disc Localization and Glaucoma Classification in Retinal Fundus Images Using Deep Learning." *BMC Medical Informatics and Decision Making* 19 (1): 1–16.
- [6] Bellemo, Valentina, Philippe Burlina, Liu Yong, Tien Yin Wong, and Daniel Shu Wei Ting. 2019. "Generative Adversarial Networks (GANs) for Retinal Fundus Image Synthesis." In *Computer Vision – ACCV 2018 Workshops*, edited by Gustavo Carneiro and Shaodi You, 11367:289–302. Lecture Notes in Computer Science. Cham: Springer International Publishing. [https://doi.org/10.1007/978-3-030-21074-8\\_24](https://doi.org/10.1007/978-3-030-21074-8_24).
- [7] Bellemo, Valentina, Gilbert Lim, Tyler Hyungtaek Rim, Gavin S. W. Tan, Carol Y. Cheung, SriniVas Satta, Ming-guang He, et al. 2019. "Artificial Intelligence Screening for Diabetic Retinopathy: The Real-World Emerging Application." *Current Diabetes Reports* 19 (9): 72. <https://doi.org/10.1007/s11892-019-1189-3>.
- [8] Bellemo, Valentina, Zhan W. Lim, Gilbert Lim, Quang D. Nguyen, Yuchen Xie, Michelle YT Yip, Haslina Hamzah, Jinyi Ho, Xin Q. Lee, and Wynne Hsu. 2019. "Artificial Intelligence

- Using Deep Learning to Screen for Referable and Vision-Threatening Diabetic Retinopathy in Africa: A Clinical Validation Study.” *The Lancet Digital Health* 1 (1): e35–44.
- [9] Bourouis, A., M. Feham, M.A. Hossain, and L. Zhang. 2014. “An Intelligent Mobile Based Decision Support System for Retinal Disease Diagnosis.” *Decision Support Systems* 59 (March): 341–50. <https://doi.org/10.1016/j.dss.2014.01.005>.
- [10] Cao, Peng, Fulong Ren, Chao Wan, Jinzhu Yang, and Osmar Zaiane. 2018. “Efficient Multi-Kernel Multi-Instance Learning Using Weakly Supervised and Imbalanced Data for Diabetic Retinopathy Diagnosis.” *Computerized Medical Imaging and Graphics* 69: 112–24.
- [11] Carrera, Enrique V., Andres Gonzalez, and Ricardo Carrera. 2017. “Automated Detection of Diabetic Retinopathy Using SVM.” In *2017 IEEE XXIV International Conference on Electronics, Electrical Engineering and Computing (INTERCON)*, 1–4. Cusco, Peru: IEEE. <https://doi.org/10.1109/INTERCON.2017.8079692>.
- [12] Chakravarty, Arunava, and Jayanthi Sivaswamy. 2016. “Glaucoma Classification with a Fusion of Segmentation and Image-Based Features.” In *2016 IEEE 13th International Symposium on Biomedical Imaging (ISBI)*, 689–92. IEEE.
- [13] Chowdhury, Amrita Roy, Tamojit Chatterjee, and Sreeparna Banerjee. 2019. “A Random Forest Classifier-Based Approach in the Detection of Abnormalities in the Retina.” *Medical & Biological Engineering & Computing* 57 (1): 193–203.
- [14] Das, Sraddha, Kriti Kharbanda, M. Suchetha, Rajiv Raman, and Edwin Dhas. 2021. “Deep Learning Architecture Based on Segmented Fundus Image Features for Classification of Diabetic Retinopathy.” *Biomedical Signal Processing and Control* 68: 102600.
- [15] Ege, Bernhard M., Ole K. Hejlesen, Ole V. Larsen, Karina Møller, Barry Jennings, David Kerr, and David A. Cavan. 2000. “Screening for Diabetic Retinopathy Using Computer Based Image Analysis and Statistical Classification.” *Computer Methods and Programs in Biomedicine* 62 (3): 165–75.
- [16] Gadekallu, Thippa Reddy, Neelu Khare, Sweta Bhattacharya, Saurabh Singh, Praveen Kumar Reddy Maddikunta, In-Ho Ra, and Mamoun Alazab. 2020. “Early Detection of Diabetic Retinopathy Using PCA-Firefly Based Deep Learning Model.” *Electronics* 9 (2): 274. <https://doi.org/10.3390/electronics9020274>.
- [17] Gardner, G. Gail, David Keating, Tom H. Williamson, and Alex T. Elliott. 1996. “Automatic Detection of Diabetic Retinopathy Using an Artificial Neural Network: A Screening Tool.” *British Journal of Ophthalmology* 80 (11): 940–44.
- [18] Ghassabi, Zeinab, Jamshid Shanbehzadeh, and Ali Mohammadzadeh. 2016. “A Structure-Based Region Detector for High-Resolution Retinal Fundus Image Registration.” *Biomedical Signal Processing and Control* 23: 52–61.
- [19] Gómez-Valverde, Juan J., Alfonso Antón, Gianluca Fatti, Bart Liefers, Alejandra Herranz, Andrés Santos, Clara I. Sánchez, and María J. Ledesma-Carbayo. 2019. “Automatic Glaucoma Classification Using Color Fundus Images Based on Convolutional Neural Networks and Transfer Learning.” *Biomedical Optics Express* 10 (2): 892. <https://doi.org/10.1364/BOE.10.000892>.
- [20] Guibas, John T., Tejal S. Virdi, and Peter S. Li. 2017. “Synthetic Medical Images from Dual Generative Adversarial Networks.” *ArXiv Preprint ArXiv:1709.01872*.
- [21] Guo, Fan, Yuxiang Mai, Xin Zhao, Xuanchu Duan, Zhun Fan, Beiji Zou, and Bin Xie. 2018. “Yanbao: A Mobile App Using the Measurement of Clinical Parameters for Glaucoma Screening.” *IEEE Access* 6: 77414–28.
- [22] Hagos, Misgina Tsighe, and Shri Kant. 2019. “Transfer Learning Based Detection of Diabetic Retinopathy from Small Dataset.” *ArXiv Preprint ArXiv:1905.07203*.
- [23] Hansen, Morten B., Michael D. Abramoff, James C. Folk, Wanjiku Mathenge, Andrew Bastawrous, and Tunde Peto. 2015. “Results of Automated Retinal Image Analysis for Detection of Diabetic Retinopathy from the Nakuru Study, Kenya.” *PloS One* 10 (10): e0139148.

- [24] He, Jianxing, Sally L. Baxter, Jie Xu, Jiming Xu, Xingtao Zhou, and Kang Zhang. 2019. "The Practical Implementation of Artificial Intelligence Technologies in Medicine." *Nature Medicine* 25 (1): 30–36.
- [25] Hemanth, D. Jude, Omer Deperlioglu, and Utku Kose. 2020. "An Enhanced Diabetic Retinopathy Detection and Classification Approach Using Deep Convolutional Neural Network." *Neural Computing and Applications* 32 (3): 707–21.
- [26] Hsieh, Yi-Ting, Lee-Ming Chuang, Yi-Der Jiang, Tien-Jyun Chang, Chung-May Yang, Chang-Hao Yang, Li-Wei Chan, Tzu-Yun Kao, Ta-Ching Chen, and Hsuan-Chieh Lin. 2021. "Application of Deep Learning Image Assessment Software VeriSee™ for Diabetic Retinopathy Screening." *Journal of the Formosan Medical Association* 120 (1): 165–71.
- [27] Jiang, Hongyang, Kang Yang, Mengdi Gao, Dongdong Zhang, He Ma, and Wei Qian. 2019. "An Interpretable Ensemble Deep Learning Model for Diabetic Retinopathy Disease Classification." In *2019 41st Annual International Conference of the IEEE Engineering in Medicine and Biology Society (EMBC)*, 2045–48. IEEE.
- [28] Juneja, Mamta, Shaswat Singh, Naman Agarwal, Shivank Bali, Shubham Gupta, Niharika Thakur, and Prashant Jindal. 2020. "Automated Detection of Glaucoma Using Deep Learning Convolution Network (G-Net)." *Multimedia Tools and Applications* 79 (21): 15531–53.
- [29] Kanagasingam, Yogesan, Di Xiao, Janardhan Vignarajan, Amita Preetham, Mei-Ling Tay-Kearney, and Ateev Mehrotra. 2018. "Evaluation of Artificial Intelligence–Based Grading of Diabetic Retinopathy in Primary Care." *JAMA Network Open* 1 (5): e182665–e182665.
- [30] Kang, Yafen, Ying Fang, and Xiaobo Lai. 2020. "Automatic Detection of Diabetic Retinopathy with Statistical Method and Bayesian Classifier." *Journal of Medical Imaging and Health Informatics* 10 (5): 1225–33.
- [31] Karkuzhali, S, and D Manimegalai. 2017. "Computational Intelligence-Based Decision Support System for Glaucoma Detection." *BIOMEDICAL RESEARCH-INDIA* 28 (11): 4737–48.
- [32] Kavitha, D., and S. Shenbaga Devi. 2005. "Automatic Detection of Optic Disc and Exudates in Retinal Images." In *Proceedings of 2005 International Conference on Intelligent Sensing and Information Processing, 2005.*, 501–6. IEEE.
- [33] Lam, Carson, Darvin Yi, Margaret Guo, and Tony Lindsey. 2018. "Automated Detection of Diabetic Retinopathy Using Deep Learning." *AMIA Summits on Translational Science Proceedings 2018*: 147.
- [34] Lee, Aaron, Paul Taylor, Jayashree Kalpathy-Cramer, and Adnan Tufail. 2017. "Machine Learning Has Arrived!" *Ophthalmology* 124 (12): 1726–28.
- [35] Liu, Yi-Peng, Zhanqing Li, Cong Xu, Jing Li, and Ronghua Liang. 2019. "Referable Diabetic Retinopathy Identification from Eye Fundus Images with Weighted Path for Convolutional Neural Network." *Artificial Intelligence in Medicine* 99: 101694.
- [36] Lunscher, Nolan, Mei Lin Chen, Ning Jiang, and John Zelek. 2017. "Automated Screening for Diabetic Retinopathy Using Compact Deep Networks." *Journal of Computational Vision and Imaging Systems* 3 (1).
- [37] Mahapatra, Dwarikanath, Behzad Bozorgtabar, and Rahil Garnavi. 2019. "Image Super-Resolution Using Progressive Generative Adversarial Networks for Medical Image Analysis." *Computerized Medical Imaging and Graphics* 71: 30–39.
- [38] Mahapatra, Dwarikanath, Behzad Bozorgtabar, Sajini Hewavitharanage, and Rahil Garnavi. 2017. "Image Super Resolution Using Generative Adversarial Networks and Local Saliency Maps for Retinal Image Analysis." In *International Conference on Medical Image Computing and Computer-Assisted Intervention*, 382–90. Springer.
- [39] Maheshwari, Shishir, Ram Bilas Pachori, and U. Rajendra Acharya. 2016. "Automated Diagnosis of Glaucoma Using Empirical Wavelet Transform and Correntropy Features Extracted from Fundus Images." *IEEE Journal of Biomedical and Health Informatics* 21 (3): 803–13.

- [40] Mitra, Anirban, Sudipta Roy, Somais Roy, and Sanjit Kumar Setua. 2018. "Enhancement and Restoration of Non-Uniform Illuminated Fundus Image of Retina Obtained through Thin Layer of Cataract." *Computer Methods and Programs in Biomedicine* 156: 169–78.
- [41] Mohamed, Nur Ayuni, Mohd Asyraf Zulkifley, Wan Mimi Diyana Wan Zaki, and Aini Hussain. 2019. "An Automated Glaucoma Screening System Using Cup-to-Disc Ratio via Simple Linear Iterative Clustering Superpixel Approach." *Biomedical Signal Processing and Control* 53: 101454.
- [42] Molodij, G., E. N. Ribak, M. Glanc, and G. Chenegros. 2014. "Enhancing Retinal Images by Extracting Structural Information." *Optics Communications* 313: 321–28.
- [43] Odili, Julius Beneoluchi, Mohd Nizam Mohamad Kahar, and Shahid Anwar. 2015. "African Buffalo Optimization: A Swarm-Intelligence Technique." *Procedia Computer Science* 76: 443–48.
- [44] Orlando, José Ignacio, Elena Prokofyeva, Mariana del Fresno, and Matthew B. Blaschko. 2017. "Convolutional Neural Network Transfer for Automated Glaucoma Identification." In , edited by Eduardo Romero, Natasha Lepore, Jorge Brieva, and Ignacio Larrabide, 101600U. Tandil, Argentina. <https://doi.org/10.1117/12.2255740>.
- [45] Pires, Ramon, Sandra Avila, Jacques Wainer, Eduardo Valle, Michael D. Abramoff, and Anderson Rocha. 2019. "A Data-Driven Approach to Referable Diabetic Retinopathy Detection." *Artificial Intelligence in Medicine* 96: 93–106.
- [46] Pratt, Harry, Frans Coenen, Deborah M. Broadbent, Simon P. Harding, and Yalin Zheng. 2016. "Convolutional Neural Networks for Diabetic Retinopathy." *Procedia Computer Science* 90: 200–205. <https://doi.org/10.1016/j.procs.2016.07.014>.
- [47] Priya, R., and P. Aruna. 2012. "SVM and Neural Network Based Diagnosis of Diabetic Retinopathy." *International Journal of Computer Applications* 41 (1).
- [48] Rajalakshmi, Ramachandran, Radhakrishnan Subashini, Ranjit Mohan Anjana, and Viswanathan Mohan. 2018. "Automated Diabetic Retinopathy Detection in Smartphone-Based Fundus Photography Using Artificial Intelligence." *Eye* 32 (6): 1138–44.
- [49] Ruamviboonsuk, Paisan, Jonathan Krause, Peranut Chotcomwongse, Rory Sayres, Rajiv Raman, Kasumi Widner, Bilson JL Campana, Sonia Phene, Kornwipa Hemarat, and Mongkol Tadarati. 2019. "Deep Learning versus Human Graders for Classifying Diabetic Retinopathy Severity in a Nationwide Screening Program." *NPJ Digital Medicine* 2 (1): 1–9.
- [50] Sarki, Rubina, Sandra Michalska, Khandakar Ahmed, Hua Wang, and Yanchun Zhang. 2019. "Convolutional Neural Networks for Mild Diabetic Retinopathy Detection: An Experimental Study." *BioRxiv*, 763136.
- [51] Selvathi, D., N. B. Prakash, V. Gomathi, and G. R. Hemalakshmi. 2018. "Fundus Image Classification Using Wavelet Based Features in Detection of Glaucoma." *Biomedical and Pharmacology Journal* 11 (2): 795–805.
- [52] Singh, Amitojdeep, Sourya Sengupta, Mohammed Abdul Rasheed, Varadharajan Jayakumar, and Vasudevan Lakshminarayanan. 2021. "Uncertainty Aware and Explainable Diagnosis of Retinal Disease." *ArXiv:2101.12041 [Cs, Eess]*, January. <http://arxiv.org/abs/2101.12041>.
- [53] Singla, Manisha, Samyak Soni, Prateek Saini, Abhishek Chaudhary, and K. K. Shukla. 2020. "Diabetic Retinopathy Detection Using Twin Support Vector Machines." In *Advances in Bioinformatics, Multimedia, and Electronics Circuits and Signals*, 91–104. Springer.
- [54] Sreng, Syna, Noppadol Maneerat, Kazuhiko Hamamoto, and Khin Yadanar Win. 2020. "Deep Learning for Optic Disc Segmentation and Glaucoma Diagnosis on Retinal Images." *Applied Sciences* 10 (14): 4916. <https://doi.org/10.3390/app10144916>.
- [55] Srivastava, Siddharth, Sumit Soman, Astha Rai, and Praveen K Srivastava. 2017. "Deep Learning for Health Informatics: Recent Trends and Future Directions." In *2017 International Conference on Advances in Computing, Communications and Informatics (ICACCI)*, 1665–70. <https://doi.org/10.1109/ICACCI.2017.8126082>.
- [56] Stead, William W. 2018. "Clinical Implications and Challenges of Artificial Intelligence and Deep Learning." *Jama* 320 (11): 1107–8.

- [57] Wan, Shaohua, Yan Liang, and Yin Zhang. 2018. “Deep Convolutional Neural Networks for Diabetic Retinopathy Detection by Image Classification.” *Computers & Electrical Engineering* 72: 274–82.
- [58] Wang, Huan, Wynne Hsu, Kheng Guan Goh, and Mong Li Lee. 2000. “An Effective Approach to Detect Lesions in Color Retinal Images.” In *Proceedings IEEE Conference on Computer Vision and Pattern Recognition. CVPR 2000 (Cat. No. PR00662)*, 2:181–86. IEEE.
- [59] Wang, Jialiang, Jianxu Luo, Bin Liu, Rui Feng, Lina Lu, and Haidong Zou. 2020. “Automated Diabetic Retinopathy Grading and Lesion Detection Based on the Modified R-FCN Object-Detection Algorithm.” *IET Computer Vision* 14 (1): 1–8.
- [60] Wang, Shuqiang, Xiangyu Wang, Yong Hu, Yanyan Shen, Zhile Yang, Min Gan, and Baiying Lei. 2021. “Diabetic Retinopathy Diagnosis Using Multichannel Generative Adversarial Network With Semisupervision.” *IEEE Transactions on Automation Science and Engineering* 18 (2): 574–85. <https://doi.org/10.1109/TASE.2020.2981637>.
- [61] Williams, Bryan M., Baidaa Al-Bander, Harry Pratt, Samuel Lawman, Yitian Zhao, Yalin Zheng, and Yaochun Shen. 2017. “Fast Blur Detection and Parametric Deconvolution of Retinal Fundus Images.” In *Fetal, Infant and Ophthalmic Medical Image Analysis*, 194–201. Springer.
- [62] Xiong, Li, Huiqi Li, and Liang Xu. 2017. “An Enhancement Method for Color Retinal Images Based on Image Formation Model.” *Computer Methods and Programs in Biomedicine* 143: 137–50.
- [63] Yannuzzi, Lawrence A., Michael D. Ober, Jason S. Slakter, Richard F. Spaide, Yale L. Fisher, Robert W. Flower, and Richard Rosen. 2004. “Ophthalmic Fundus Imaging: Today and Beyond.” *American Journal of Ophthalmology* 137 (3): 511–24.
- [64] Zhou, Mei, Kai Jin, Shaoze Wang, Juan Ye, and Dahong Qian. 2017. “Color Retinal Image Enhancement Based on Luminosity and Contrast Adjustment.” *IEEE Transactions on Biomedical Engineering* 65 (3): 521–27.
- [65] Zhu, Kaiqiang, Yushi Chen, Pedram Ghamisi, Xiuping Jia, and Jón Atli Benediktsson. 2019. “Deep Convolutional Capsule Network for Hyperspectral Image Spectral and Spectral-Spatial Classification.” *Remote Sensing* 11 (3): 223.