

IMPORTANT NON-ONCOGENIC IMMUNO SUPPRESSIVE VIRAL DISEASES OF CHICKENS

Abstract

Immunosuppressive non-oncogenic viral diseases in poultry birds cause heavy mortality and huge economic losses in infected chickens thus posing a great risk to poultry industry. Increased susceptibility to secondary infections and deficient response to vaccination further complicates the condition. This chapter provides an overview of various non-oncogenic immunosuppressive viral diseases of chickens with special emphasis on their transmission, pathogenesis and considerable immunosuppressive effect produced by such diseases. The important immunosuppressive diseases discussed in this chapter include Chicken Infectious Anaemia (CIA), Infectious Bursal Disease (IBD), Avian Reovirus (ARV) and Fowl Adenovirus (FAdV) diseases. CIA virus, ARV and FAdV follow both trans-ovarian route as well as horizontal route of transmission. However, IBD virus is transmitted only by horizontal route. CIA virus produces the immunosuppressive effect either alone or in combination with other viruses causing increased mortality, severe anaemia and generalized lymphoid atrophy. The virus replicates in lymphoid and erythroid progenitor cells, causing their severe depletion and distinct sub-clinical infections. IBD virus replicates in IgM⁺ cells of bursa of Fabricius and leads to destruction of bursal follicles causing immunosuppression. The mortality by IBD virus is variable and depends upon age of the chicken and more specifically virulence of the virus. ARVs and FAdV are opportunistic viruses and usually occur in combination with other immunosuppressive viruses. ARV commonly causes malabsorption syndrome, enteric disease, viral arthritis/tenosynovitis, stunting/runting syndromes,

Authors

Syedah Asma Andrabi

Division of Veterinary Pathology ,
Faculty of Veterinary Sciences and Animal Husbandry,
R.S. Pura, Sher-e-Kashmir University of Agricultural Sciences,
Jammu.
syedahasmaandrabi@gmail.com

Nawab Nashiruddin

Division of Veterinary Pathology,
Faculty of Veterinary Sciences and Animal Husbandry,
R.S. Pura, Sher-e-Kashmir University of Agricultural Sciences,
Jammu.
nawabn1@rediffmail.com

Shafiqur Rahman

Division of Veterinary Pathology,
Faculty of Veterinary Sciences and Animal Husbandry,
R.S. Pura, Sher-e-Kashmir University of Agricultural Sciences,
Jammu.
srahmanskuastj@gmail.com

Dawoud Aamir

Department of Veterinary Gynaecology and Obstetrics,
College of Veterinary Sciences, Rampura phul,
Bathinda, Punjab.
dawoud786@gmail.com

Jafrin Ara Ahmed

Division of Veterinary Physiology and Biochemistry,
Faculty of Veterinary Sciences and Animal Husbandry,
R.S. Pura, Sher-e-Kashmir University of Agricultural Sciences,

immunosuppression, and respiratory disease in young chickens. The virus interacts with B-lymphocytes in a similar manner as in IBDV, thus, producing lesions in bursa and other lymphoid organs. FAdV is an immunosuppressive pathogen, which causes Hydropericardium syndrome (HPS) and Inclusion body hepatitis (IBH) in 3–6-weeks old broilers. Mixed infections of immunosuppressive viruses are common, as compared to the individual infections. This results in synergic pathological effects that further deteriorates the health of the infected chickens. Proper vaccination strategies, diagnostic approaches and control measures should be followed to prevent the occurrence of such infections.

Jammu.

jafrinahmed@rediffmail.com

Keywords: ARV, CAV, Chicken, FAdV, IBDV, Immunosuppression.

I. INTRODUCTION

Immunosuppression is suppression of body's immune system to fight back infections and diseases. It is a major health concern in poultry industry, which leads to heavy mortality and severe economic losses. Immune compromised birds often become susceptible to various viral, fungal and secondary bacterial infections, thus further exaggerating the adverse effects produced by immunosuppression[1]. A wide variety of viruses cause mild to severe degree of immunosuppression, depending upon the tissue tropism. Viruses causing immunosuppression in poultry include Chicken Infectious Anaemia Virus (CIAV), Infectious Bursal Disease Virus (IBDV), Fowl Adenovirus (FAdV) and a group of tumour causing viruses viz., Marek's Disease Virus (MDV) and Avian Leukosis Virus (ALV). All these viruses produce direct effect on the various organs of the immune system, and mostly occur together leading to amplified adverse effects. Avian Reovirus (ARV) is believed to produce less marked effect on the immune system; however, exact mechanism of immunosuppression by the virus is still not fully understood. This chapter summarizes the current knowledge and understanding on various chicken non-oncogenic immunosuppressive viral diseases, their pathogenesis and pathogen-host interactions that may help devise successful diagnostic and control strategies.

II. CHICKEN INFECTIOUS ANAEMIA (CIA)

1. Infectious Immunosuppressive Viral Diseases: Chicken Infectious Anaemia (CIA) is a major immunosuppressive disease of chickens which is globally recognized in almost all poultry producing countries [2, 3]. The disease is known by its other names as well viz., Blue wing disease, Hemorrhagic aplastic anemia syndrome and Anemia dermatitis syndrome. CIA is caused by *Gyrovirus* of family *Circoviridae* which is the smallest avian virus (23-25 nm)[4, 5, 6]. The viral genome consists of a circular ss-DNA (2.3 kb) with three partially overlapping major open reading frames (ORFs) that encode for three proteins viz VP1, VP2 and VP3[7, 8]. VP1 is as a major capsid protein present in the virions, VP2 is essential for virus assembly and replication. VP3 or apoptin has an important role in disease pathogenesis as it causes apoptosis of infected cells[5].

CIA was recognized as a new disease in young commercial chickens in Japan, while investigating a contaminated Marek's disease vaccine accident with Reticuloendotheliovirus (REV) in Specific-Pathogen-Free (SPF) chicks[9]. In India, the first case of CIA in chickens was reported in 1994 [10]. Since then subsequent upsurge of the disease have been reported from many parts of the country[11, 12, 13, 14, 15, 16]. Development of clinical disease following infection with CIAV is dependent on number of factors such as age, route, challenge dose of virus, and presence of maternal antibodies [17, 18, 19]. Moreover, co-infection with other immunosuppressive viruses such as Infectious Bursal disease virus (IBDV), Marek's disease virus (MDV), Fowl Adenovirus (FAdV) and Avian Reoviruses (ARV) is another important epidemiological key factor[18, 19].

2. Transmission, Pathogenesis and Immunosuppression: The route of transmission for CIA is both vertical and horizontal[6, 17]. In vertical transmission, infected adult chickens transfer the virions to embryo during viraemia phase before neutralizing antibodies develop. Chickens hatching from such eggs develop symptoms of the disease such as anaemia and immunosuppression. Such newly hatched immunosuppressive chicks

become prone to secondary bacterial infections and simultaneously act as a source of infection for horizontal transmission; probably through faecal materials until neutralizing antibodies develop [19].

Chicken infectious anaemia virus (CIAV) is a potent immunosuppressive agent, which enters the target cells (Erythroid and lymphoid progenitor cells) by adsorption and penetration, then multiplies in the nucleus of these cells by a rolling circle model. The virus causes severe depletion of thymocytes, primarily attacking thymic lymphoblasts (CD4+, CD8+ T-cells) and anaemia by destruction of haemocytoblasts and erythroblastoid cells in young chickens. This leads to generalized lymphoid atrophy, chronic aplastic anaemia, thymus atrophy and immunodeficiency [20, 21, 22, 23]. In addition, severe muscular and sub-cutaneous tissue haemorrhages have also been reported in CIAV infected chickens [20, 24, 25]. The specific tropism of CIAV for lymphocytes explains the severe lymphocyte depletion caused by the virus in affected birds. CIAV leads to cytolytic infection by replicating primarily in cortical thymic precursor cells and hematopoietic precursor cells in bone marrow [26, 27, 22] and cell death by the mechanism of apoptosis prompted by the VP3 protein [28, 29]. Birds usually recover from depression and anaemia within 4-6 weeks after convalescent stage coincides with antibody development.

In young chicks, CIAV suppresses both helper (CD4+) and cytotoxic (CD8+) T lymphocyte cell population in thymus [30, 20] and causes marked depression of cellular and humoral immune functions thereby leading to decreased immunoprotective efficacies. The virus has detrimental effects on T-cell mediated functions such as lymphocyte transformation response to mitogens, macrophage functions, lymphokine production (IL-2, TCGF and IFN), phagocytosis and bactericidal activities [31, 32, 23]. Additionally, production of IL-1, IL-2 and Interferons is inhibited by CIAV, which causes adverse effects on molecular immunoregulatory responses in cytotoxic activities of macrophages, natural killer (NK) cells, cytotoxic T lymphocyte (CTL) and expression of surface receptors leading to severe immunosuppression. The affected birds become susceptible to infections by secondary pathogens, have depressed vaccinal immunity and show vaccination failure against poultry pathogens like Fowl pox, Infectious Laryngotracheitis, Marek's disease etc. [31, 33, 27, 25, 34, 19]. Under field conditions, birds infected with CIAV show few signs of the disease. Coinfection with other infectious agents viz Avian Reovirus (ARV) causes blue wing disease (BWD), with fowl adenovirus (FAV) causes aplastic anaemia syndrome, with IBDV causes haemorrhagic anaemia syndrome, and with *Clostridium perfringens* and *Staphylococcus aureus* causes gangrenous dermatitis, thus, further complicating the condition [17, 35, 18, 19].

- 3. Clinical Signs and Pathological Lesions:** Clinical signs of CIAV include diarrhoea, depression and lesions in the interior side of the wings [34, 36]. Mortality and morbidity may reach up to 55% and 80% respectively [3]. However, the peak mortality is observed after 5 to 6 days of onset of acute form that declines after a further 5 to 6 days [37, 38]. Most of the lesions are associated with the thymus, spleen, bursa, bone marrow and caecal tonsils [17, 39, 15]. CIAV infected birds show severe depletion of lymphocytes from both cortex and medulla of the thymus, bursa, spleen, and caecal tonsils followed by hyperplasia of reticular cells and atrophy of the haematopoietic elements of the bone marrow [40, 41, 17]. In long standing cases, lymphocytes replace haematopoietic cells in bone marrow and both erythropoietic and granulopoietic tissue becomes depleted. [42]. In

some cases, intranuclear inclusion bodies may be noticed in the thymocytes and reticular cells of the thymus and haematopoietic precursor cells of bone marrow [43, 44, 45, 22, 15]. Under field conditions, chicken carcasses are pale and icteric, subcutaneous oedema and skin haemorrhages are noticed that often extends to the underlying muscles. In much severe cases, multifocal haemorrhages in the muscles of pectoral region and markedly pale and icteric liver, kidney and bone marrow are well appreciated [45, 13]. Lesions can be noted in other visceral organs, especially liver, in which dilated sinusoids, distended endothelial cells, hyaline necrosis of hepatocytes and fatty degeneration with no evidence of infiltrating cells around the central vein can be seen [9, 46]. Lesions are more extensive in naturally occurring cases because other infectious agents like ARV accompany CIA [47].

- 4. Diagnosis:** CIA can be tentatively diagnosed based on clinical picture and related pathological lesions but various techniques have been described to arrive at a confirmatory diagnosis [48]. Immunohistochemical technique is successfully employed for detection of CIAV antigens in the thymus, bone marrow, proventriculus, spleen, lymphoid aggregates in the lamina propria of intestines, epithelium of crypts, villi and ascending duodenum of affected birds [17, 28, 49, 50]. Intensely stained large intranuclear inclusions of CIAV antigen have been detected in both thymic cortex and spleen of CIAV positive cases using immunohistochemistry [51, 52]. Immunoperoxidase staining technique on formalin fixed, paraffin-embedded tissues for detection of CIAV in affected birds have also been described [53, 17, 49]. Another, widely used molecular method, which detects CIAV DNA in tissues, sera and blood of infected birds is Polymerase Chain Reaction (PCR), [54, 55, 56, 57]. Samples like thymus, bursa, spleen and bone marrow are usually processed for the direct detection of CIAV DNA by amplification of VP1, VP2 and VP3 region or either of them using specific primers [58, 59, 12, 13, 60].

III. INFECTIOUS BURSAL DISEASE

Infectious bursal disease (IBD) also known as Gumboro disease is a pestilential acute viral disease of young chickens adversely affecting their immune system. It causes destruction of the lymphoid tissues especially the bursa of Fabricius leading to immunosuppression in nonfatal cases [61]. Infectious bursal disease is caused by a non-enveloped, double-stranded RNA (dsRNA) virus called *Avibirnavirus* of family *Birnaviridae* [62]. The virus contains two segments (segment A and B), Segment A (3.2 kb) encodes viral proteins (VPs): VP2, VP3, VP4 and VP5 by two overlapping open reading frames, whereas segment B encodes VP1 [63, 62].

IBD was first discovered from USA by Cosgrove in the year 1962. Since then it has occurred around the world and has been described as an endemic disease in many poultry producing areas [64]. Chickens act as main host of IBD infection, but ducks, ostriches, turkeys and guinea fowl may also be infected [65]. It usually affects the young chicks between 3-6 weeks of age [66, 67, 68]. The virus has two forms: low virulence IBDV and very virulent IBDV. The low virulence virus caused mortality of 1-2 % whereas high morbidity and mortality are reported with very virulent IBDV (vvIBDV), globally causing grievous economic losses to the poultry industry. A vvIBDV was first reported from Europe in the 1980s in broilers, and then it immediately spread to Asia, Africa, and Latin America [63, 69]. About

60%–76% of virulent (vv) IBDV strains from four continents have been reported [70]. With the emergence of vvIBDV strains, the mortality rates have increased to about 60% in young chickens, making it difficult to control and prevent its epidemic throughout the world [71]. IBDV was first reported from India, in 1971 [72]. Later continuous outbreaks were reported from different parts of the country with variant strains of the virus [73, 74, 75, 76, 77, 78].

- 1. Transmission, Pathogenesis and Immunosuppression:** Infectious Bursal Disease is horizontally transmitted by oral route but vertical transmission of the disease is not evident [79, 64]. Infected chickens disseminate the virus in their droppings, which acts as a major source of contagion to the rest of the flock [80].

Once IBDV gains its entry via oral or nasal route, replication starts in lymphocytes and macrophages of gut-associated tissue. Via blood stream, the virus reaches bursa of Fabricius, because of its selective tropism for B-lymphocytes causing pronounced depletion of the lymphoid follicles. The virus enters back into the blood stream and causes secondary viremia, resulting in its spread to other organs like kidneys and muscles manifesting pathognomonic clinical signs and death [81]. The virus can cause 70% mortality, and has the ability to suppress immunity provided by maternal antibodies.

Immunosuppression by IBDV is mainly attributed to the apoptosis and necrosis of B cells [82, 83, 84, 85]. Apoptosis is commenced by array of physiological stimuli, although pathological stimuli, such as viral infections, can also set off the phenomenon [61]. IBDV positive T-cell populations have been identified in the bursal follicles as well [68]. IBDV activates all branches of immune system, however, level of activation depends upon virulence of strains, immunity, age and genetics of affected chickens.

- 2. Clinical Signs and Pathological Lesions:** Birds affected with Infectious Bursal Disease mainly show ruffled feathers, exhaustion, dehydration, whitish watery diarrhoea, depression, huddling together, anorexia and prostration [61, 86]. Incubation period of the disease is 2-3 days, mortality in affected flock begins on third day, peaks on the fourth day, and the surviving birds show recovery after fifth to seventh day. Severity of IBD depends upon four factors i.e. age, breed sensitivity, virulence of IBDV strain and the degree of passive immunity [61]. IBD affected chickens show diffused haemorrhages likely due to impairment of the clotting mechanism in the visceral organs, pectoral and thigh muscles [86, 87]. Among various lymphoid organs, the lesions in the bursa are pathognomonic in the diagnosis of IBD, although lesions may be evident in thymus and bone marrow as well [88]. Bursa appears turgid, sometimes oedematous with a gelatinous yellowish transudate, and subsequently haemorrhagic and atrophic in affected chickens [61, 89, 15]. Severe lymphoid depletion in the bursa of Fabricius, as well as non-bursal lymphoid tissues can be evident. Among visceral organs, kidneys appear swollen, hypertrophic and whitish, with urate crystal deposits; mucosa of the proventriculus may show echymotic haemorrhages [61, 89, 86]. Lesions in liver include severe congestion, and spleen can be enlarged and mottled, or atrophied in several cases [86].

In experimental infections, vvIBDV leads to severe clinical disease and increased mortality. Characteristic histopathological lesions include necrosis of bursa and thymus, fatty changes in liver with acute hepatitis, aplastic anemia and systemic inflammatory response which further leads to the inflammation in the pulmonary capillary walls [90,91]. Some reports have shown remarkable alterations in the bone marrow characterized by lytic changes with depletion of heterophil myelocytes and pyknotic nuclear alteration on the second day after inoculation of chickens with HPS-2 strain of IBDV [92].

3. **Diagnosis:** Different strains of the virus produce pathology of varying degrees and lesions. To understand the association between the pathogenicity of IBDV and distribution of viral antigen, vvIBDV strains were compared with moderately pathogenic IBDV strains and it was concluded that the very virulent strains of IBDV brought about much decrease in the thymic weight index and severe lesions in the thymus, spleen, caecal tonsil and bone marrow [93]. Similarly, thymus atrophy is particularly analogous with the acute phase of the disease and might indicate the virulence of the isolate [91]. Such approach in IBDV diagnosis under field conditions could help to some extent in differentiating various strains of the virus. Additionally, flock history, clinical signs, post mortem lesions, and histopathological lesions combined with other serological, molecular and immunohistochemical techniques substantiate IBD infections in chickens. Commercially available antigen capture enzyme linked immunosorbent assay (AC-ELISA) kits successfully demonstrate presence of IBDV antibodies in sera of affected birds [94]. Meanwhile, Virus neutralization test (VNT) is the only reliable assay for differentiating IBDV isolate into antigenic serotype subtype [95].

In addition, immunostaining methods have been successfully used to demonstrate a higher frequency of antigen-positive cells in the bursa [96, 97, 98], thymus [90, 91, 92], spleen, bone marrow [93, 99, 100] and proventriculus of birds infected with vvIBDV [101].

In spite of multiple diagnostic approaches, none of them are valuable for the classification of IBDV strains. To classify the IBDV strains, Reverse transcriptase Polymerase chain reaction (RT-PCR) using essentially the variable domain of VP2 followed by sequencing and phylogenetic comparison has been successfully used [102].

IV. AVIAN REOVIRUS

Avian Reoviruses (ARV) were first isolated in 1954 from chickens [103]. About 85% to 90% of isolated Reoviruses are found to be non-pathogenic. The pathogenic strains cause malabsorption syndrome, enteric disease, viral arthritis/tenosynovitis, stunting/runting syndrome, immunosuppression, and respiratory diseases. Recently, the virus has been reported to produce neurological signs in chickens as well [104]. ARV belongs to the genus *Orthoreovirus* of family *Reoviridae* [105]. The virus particles have icosahedral symmetry with double-shelled arrangement of surface proteins, are non-enveloped, and consist of a double-stranded ribonucleic acid having ten segments. The genome can be distinguished into three size classes, viz: L (large), M (medium) and S (small). Similarly, proteins encoded by the genome are also divided into three size classes: X (large), p

(medium) or, a (small). Of eleven proteins, nine are structural (XI, X2, X3, μ_1 , μ_2/μ_2C , σ_1 , σ_2 and σ_3) and two non-structural (μ_{NS} and σ_{NS})[106].

- 1. Transmission, Pathogenesis and Immunosuppression:** ARV infection commonly occurs in chickens between 4 to 8 weeks of age, however, older birds also seem to acquire the infection[103]. Transmission of Avian Reoviruses is by both vertical and horizontal route[107, 108, 109, 110]. Transmission through egg is probably low under natural conditions; however, congenitally infected chicks act as the main source of infection to the rest of the batch, especially through faecal-oral route, or sometimes through the respiratory tract [111]. After the entry of virus via oral route, it establishes itself in the blood and leads to viraemia. The virus can be recovered from the erythrocytes, plasma and mononuclear cell fractions of blood within 30 hours of infection. By 3-5 days, virus distributes itself in the whole body[112]. Small intestinal epithelial cells and the bursa of Fabricius act as main sites of infection[113]. Experimental studies have also proposed the liver as a main target organ for ARV[114]. The virus can also gain its entry via broken skin of feet and gets established in the hock joint, producing relatable symptoms and lesions[109]. Virus may induce apoptosis in infected cells, which could be confirmed by characteristic intranucleosomal cleavage pattern of extracted DNAs using agarose gel electrophoresis on DNA[115]. ARV infections have been associated with immunosuppression and produce effect on both humoral and cellular immune responses in chickens [116, 117, 118, 119, 120]. In some cases, immunosuppression by ARV may not be evident[121, 122]. The virus interacts with B-lymphocytes in a similar manner as in IBDV, thus producing lesions in bursa and other lymphoid organs [123]. Experimental studies in chickens, have suggested possible role of ARV in inducing suppressor macrophages, which inhibits T-cell function to cause immunosuppression, rather than directly compromising the functional capabilities of T-cells[124]. In addition, the strain of ARV used for vaccination in chickens also determines the extent of immunosuppression [118]. Synchronous vaccination with turkeys herpesvirus vaccine (HVT) and ARV vaccine in day old chicks has been reported to increase the incidence of Marek's disease [117]. Therefore, experimental studies have suggested that in-ovo vaccination of embryos with commercial ARV vaccine should be avoided, otherwise, it may lead to immunosuppression in the chicks[125]. Other infectious agents that usually enhance the pathogenic effects produced by ARV include IBDV, CIA, *Staphylococcus aureus* and *Mycoplasma synoviae*[122, 126].
- 2. Clinical Signs and Pathological Lesions:** Birds affected with ARV are usually stunted, unthrifty, display poor feed conversion ratios, show orange tinged diarrhoea, and exhibit loss of color in the legs/beak, or have feathering problems, with usually low mortality in case of malabsorption syndrome [103]. In case of arthritis/ tenosynovitis syndrome, lameness and swelling of hock are evident[127]. Necropsy findings reveal reduced weight of bursa of Fabricius, spleen and presence of white spots on the liver with pericarditis, obvious lesions in the muscles and lesions on the skin [47, 112, 127, 128, 129]. In case of tenosynovitis syndrome, involvement of synovial membrane and surrounding tissues with lesions ranging from soft swelling to petechial haemorrhages and development of small erosive lesions on the articular cartilage are characteristic. In case of old birds, gastrocnemius may get ruptured and sometimes digital flexor tendon is also involved[130].

Histopathological features in affected birds include fibrinous exudation, marked granulation and capillary congestion of pericardium, marked atrophy and degeneration of myocardium; hepatic degeneration and periportal heterophilic cell infiltration in liver; and moderate to severe lymphoid depletion in bursa and spleen [47, 115, 128, 127]. Predominance of mononuclear cells in cutis and sub-cutis with depletion of lymphocytes and reticular cell proliferations can be demonstrated in the bursa, thymus and spleen of chickens infected with both ARV and CAV [47]. Small intestines often show vacuolar degeneration in the epithelium and sloughing may be evident in the tip of the villi. Congestion and haemorrhages in the respiratory tract [131, 132], are occasionally present, although lesions in the respiratory tract, especially lungs, are often associated with co-infection of ARV with *Pasteurella multocida* [133].

In tenosynovitis syndrome, lesions may range from mild thickening and oedema of tendon to severe synovitis, heterophilic infiltration, and occasional multifocal necrotic changes in tendons or accompanied with dystrophic calcification [127, 130, 134].

- 3. Diagnosis:** The lesions associated with Reoviruses are not pathognomonic and may resemble those caused by other bacterial infections like *Staphylococcus aureus* and *Mycoplasma synoviae*, and viral infections like IBD and CAV. Therefore, confirmation of the disease requires immunohistochemical, molecular and serological techniques. Immunohistochemical techniques have been used for demonstration of ARV in paraffin-embedded tissues where ARV antigens appear as dark brown granules in the cytoplasm of affected cells in liver, bursa of Fabricius, spleen, lung, kidney, intestine and pancreas [70, 131, 135, 136, 137]. Reoviruses can grow in yolk sac and chorioallantoic membrane of embryonated chicken eggs, and on various culture cells. Cell cultures of chicken origin when infected by Reovirus show characteristic syncytia formation as early as 24–48 hours, thenceforth monolayer degeneration with presence of giant cells. Infected cells exhibit eosinophilic or basophilic intracytoplasmic inclusions. The virus can be identified by electron microscopy, immunofluorescence, RT-PCR and sequencing of σ -C gene [138]. Additionally, full genome characterization of recently emerging ARV strains may be done by next-generation sequencing technique.

V. FOWL ADENOVIRAL INFECTION

Fowl Adenoviral (FAdV) infections have gained attention after frequent outbreaks of Inclusion Body Hepatitis (IBH) from various parts of the world [139]. It has emerged as an immunosuppressive disease of young chickens, especially broilers between 3-6 weeks of age. Infection with IBDV or CIAV may usually predispose the birds to FAdV and vice versa. In fact, chickens infected with CIAV have high susceptibility for FAdV, IBDV and MDV. Together these immunosuppressive viruses act synergistically and interfere with the development of host immune system [140]. Fowl Adenoviruses (FADVs) belong to the genus *Aviadenovirus* and family *Adenoviridae*. FADVs are non-enveloped, icosahedral, double stranded DNA viruses with nucleocapsid containing hexon, penton and fiber as structural proteins [141]. A major capsid protein exposed on the surface of the virus is known as Hexon, which consists of the loop-1 structure as subtype-specific antigenic determinants [142], the analysis of which allows for the type inference, with wide application in routine diagnostics of FAdV in the field [143]. Based on hexon gene, FAdV has been classified into 12 serotypes viz FAdV-1 to FAdV-7, FAdV-8a, FAdV-8b, and FAdV-9 to FAdV-11 [144]. FAdV-1 and

8b causes Adenoviral gizzard erosions (AGE), FAdV-4 causes Hepatitis-hydropericardium syndrome (HHS) or Hydropericardium syndrome (HPS), and FAdV-2, 8a, 8b and 11 causes Inclusion Body Hepatitis (IBH) in young chickens [145, 146]. HPS was first reported from Pakistan in the year 1987 [147]. Then massive outbreaks of the disease occurred across the country followed by its spread to India during early 1990's [148, 149]. Helmboldt and Frazier first reported IBH in chickens in the year 1963 [150].

1. Transmission, Pathogenesis and Immunosuppression: Transmission of FADV occurs vertically via eggs from hens to their off springs, and horizontally from infected chickens to rest of the flock via faeces, but rarely by respiratory droplets, and fomites [151]. Vertical transmission of the virus plays a critical role in the development of the disease, as maximum transmission of the virus occurs via this route. Chicks hatched from infected eggs normally shed the virus from day 1 post hatch, but do not develop symptoms of the disease till 2 to 4 weeks of age due to the presence of maternal antibodies. Subsequently, the shed virus could become source of infection for chicks with declining maternal antibodies [152]. The disease runs its course from 7 to 15 days, with mortality ranging from 20% to 70% [153]. Virus is excreted in very high titers through faeces, although isolation of the virus from nasal, conjunctival, tracheal mucosa and kidneys has been reported [154]. FADV has special affinity towards endothelial hepatic cells and lymphoid cells. After entry of the virus via oral route, it colonizes in intestinal epithelium at 12 hours post infection and disseminates in the blood at 24 hours post infection. After 2 to 3 days, virus can be detected in all target organs, including pancreas and liver. Then the virus starts multiplying in target organs producing pathological lesions that coincide with clinical manifestation of the disease [155]. Post infection recovery is usually noticed from 7 to 9 days onwards. However, virus can remain latent in the caecal tonsils, whereby recovered chickens can shed the virus via faeces for longer periods. The virus produces immunosuppression by damaging the lymphoid tissues [156], particularly after depletion of B and T cells, and their growth impairment in the bursa and thymus [157, 158, 159].

2. Clinical signs and pathological lesions: Flocks affected with IBH/HPS show abrupt mortality, with nonspecific clinical symptoms that vary among individual birds. At necropsy, affected chickens show enlarged and swollen liver, with yellowish discoloration and haemorrhagic or necrotic foci. Common findings in birds affected with HPS include accumulation of straw-coloured clear fluid in pericardial sac, hepatitis and nephritis [160]. Additionally, atrophy, necrosis and petechiae in the pancreas can be noticed in birds with IBH [161, 162]. Histologically, numerous eosinophilic intranuclear inclusions or sometimes basophilic can be seen in the hepatocytes [163]. In addition, multifocal coagulative necrosis and mononuclear cell infiltration in liver and pancreas are often noticed [162, 164, 165, 166]. Lymphoid degeneration along with lymphocytic depletion highlights the possible role of virulent FAdV strains in immunosuppression [157, 159, 167].

Mortality rates and incidence are much higher in birds with HHS than those affected with IBH [168]. Otherwise, both the diseases affect liver and other viscera including the lymphoid organs. On the other hand, highly virulent FAdV-1 causes gizzard erosions with discoloration of the koilin layer, gastric perforations, and dilated proventriculus [169]. In general, histologically glandular epithelial cells appear degenerated and necrosed and lymphatic cell infiltration with intranuclear inclusion bodies could be

appreciated in the lamina propria and muscular layers of the gizzard [170, 171, 172]. Experimental studies have revealed intranuclear inclusion bodies in the mucosa of gizzard up to two weeks post infection with pathological changes in the pancreas and/or liver in birds inoculated with adenovirus [169, 171].

- 3. Diagnosis:** Microscopic detection of inclusion bodies and specific lesions in the affected organs helps in initial diagnosis of FAdV infection followed by electron microscopy to study the virus morphology [173]. Additionally, recent conventional and molecular techniques successfully detect FAdV in suspected cases. Virus can be cultivated in chorioallantoic membrane and yolk sac of 8 to 12 days old embryonated chicken or duck eggs. Inoculated dead embryos display haemorrhages, curling, stunted growth, as well as presence of inclusion bodies in visceral organs. Isolation of FAdV is possible in cell cultures, where viruses can be propagated on chicken embryo fibroblasts, liver, kidneys, QT-35 cells and Vero cell lines [174, 175, 176]. Molecular diagnosis of FAdV is done using various techniques, viz. restriction endonuclease analysis (REA), in-situ hybridization using DNA probes, conventional PCR and real-time PCR (RT-PCR). Diagnosis by the conventional PCR is based on detection of hexon gene loop 1, but this technique cannot quantify the viral load [177, 178]. Therefore, SYBR-green based real-time PCR methods were used in multiple studies that identify and measure the quantity of all FAdV species [179, 180, 181, 182]. Additionally, several serological techniques like agar gel precipitation test, viral neutralization (VN) test, counter immune electrophoresis, indirect immunofluorescence assay [149], agar gel immunodiffusion test [183] and various modifications of an enzyme-linked immunosorbent assay (ELISA) can be employed for identification of FAdVs in tissue homogenates.
- 4. Mixed Infections of Immunosuppressive Viral Diseases:** Many researchers have reported mixed infections of immunosuppressive viruses in chickens under field conditions [17, 20, 47, 182, 186] and their combined effects have been experimentally elucidated in chickens as well. In one of the experiments, it was demonstrated that CIAV produced suppressed effect on vaccine immunity of turkey herpesvirus (HVT) and that the response was markedly depressed in chicks that were dually inoculated with CIAV and MDV or HVT, than those in chicks inoculated with CIAV alone [41]. In another study, dual infection of CIAV and IBDV in SPF chickens showed that, IBDV increased the susceptibility of birds for CIAV infection by as much as 100-fold, which resulted in increased mortality rates [26, 27, 184]. It was later proposed that IBDV infections should be controlled by vaccination programs in breeder flock to provide brood with maternal antibody and thus limiting the interactions between CIAV and IBDV. CIAV could also exacerbate the effect of virulent strains of MD virus challenge in poorly immunized birds [26, 27, 185]. In another report, ARV enhanced pathogenic effect of CIAV in chickens inoculated with both ARV and CIAV. This resulted in production of extensive lesions in bone marrow and thymus, produced by either of the virus alone [186]. A study suggested that IBDV produced immunosuppression due to development of suppressor cells in the spleen of infected chicks causing in vitro mitogenic hyporesponsiveness and impairment of helper T-cell function making birds susceptible to infection by MDV [187]. In addition, co-infection with CIAV and vvMDV strain aggravated mortality and thymus and bursal atrophy as compared to the infection with either virus alone. Thus, CIAV was considered as an important factor in increasing frequency of occurrence of MD [188, 189].

VI. CONCLUSION

Immunosuppressive viral disease of chickens have historically caused great loss to the poultry industry in terms of mortality. Therefore, proper strategies for controlling these viral diseases should be implemented which includes proper and timely vaccination for breeder as well as progeny flocks. Good managerial practices, proper biosecurity procedures especially in intensively housed chickens can reduce the rampancy of infections. Other procedures include annihilation of contaminated feed and water, regular disinfection of chicken houses and avoiding multi-age farms to prevent the spread of diseases among younger and older birds.

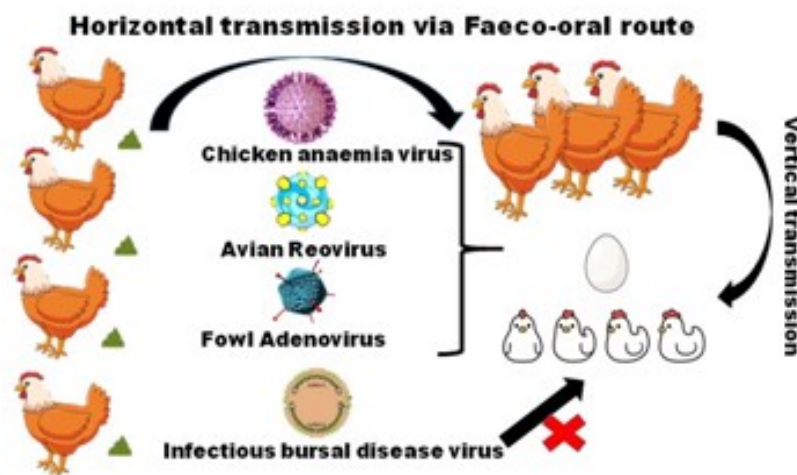


Figure 1: Route of Transmission of Immunosuppressive Viral Diseases

REFERENCES

- [1] Calcagni, E., & Elenkov, I. (2006). Stress system activity, innate and T helper cytokines, and susceptibility to immune-related diseases. *Annals of the New York Academy of Sciences*, 1069(1), 62-76.
- [2] Ducatez, M. F., Chen, H., Guan, Y., & Muller, C. P. (2008). Molecular epidemiology of chicken anemia virus (CAV) in southeastern Chinese live birds markets. *Avian diseases*, 52(1), 68-73.
- [3] AboElkhair, M., El-Razak, A., Alaa, G., & Metwally, A. E. Y. (2014). Molecular characterization of chicken anemia virus circulating in chicken flocks in Egypt. *Advances in Virology*, 2014.
- [4] Pringle, C. R. (1999). Virus taxonomy at the XIth international congress of virology, Sydney, Australia, 1999. *Archives of virology*, 144, 2065-2070.
- [5] Todd, D., Scott, A. N. J., Fringuelli, E., Shivraprasad, H. L., Gavier-Widen, D., & Smyth, J. A. (2007). Molecular characterization of novel circoviruses from finch and gull. *Avian pathology*, 36(1), 75-81.
- [6] Zhang, X., Liu, Y., Wu, B., Sun, B., Chen, F., Ji, J., & Xie, Q. (2013). Phylogenetic and molecular characterization of chicken anemia virus in southern China from 2011 to 2012. *Scientific Reports*, 3(1), 3519.
- [7] Miller, M. M., Jarosinski, K. W., and Schat, K. A. (2005). Positive and negative regulation of chicken anemia virus transcription. *Journal of Virology*, 79(5): 2859-868.
- [8] Natesan, S., Kataria, J. M., Dhama, K., Rahul, S., & Baradhwaj, N. (2006). Biological and molecular characterization of chicken anaemia virus isolates of Indian origin. *Virus research*, 118(1-2), 78-86.
- [9] Yuasa, N., Taniguchi, T., & Yoshida, I. (1979). Isolation and some characteristics of an agent-inducing anemia in chicks. *Avian Diseases*, 23: 366-385.

- [10] Venugopalan, A. T., Elankumaran, S., Raj, G. D., Manohar, B. M., Thangavelu, A., Ravikumar, G., & Raj, A. S. (1994). Isolation of chicken anaemia virus in Tamil Nadu. *Indian Veterinary Journal*, 71(4), 411-412.
- [11] Bhatt, P., Shukla, S. K., Mahendran, M., Dhama, K., Chawak, M. M., & Kataria, J. M. (2011). Prevalence of Chicken Infectious Anaemia Virus (CIAV) in commercial poultry flocks of Northern India: a serological survey. *Transboundary and emerging diseases*, 58(5), 458-460.
- [12] Wani, M. Y., Dhama, K., Latheef, S. K., Barathidassan, R., Tiwari, R., Chakraborty, S., & Singh, S. D. (2014). Experimental pathological studies of an Indian chicken anaemia virus isolate and its detection by PCR and FAT. *Pakistan journal of biological sciences: PJBS*, 17(6), 802-811.
- [13] Gowthaman, V., Singh, S. D., Dhama, K., Barathidasan, R., Srinivasan, P., Mahajan, N. K., & Ramakrishnan, M. A. (2014). Molecular characterization of chicken infectious anemia virus isolated from commercial poultry with respiratory disease complex in India. *Adv Anim Vet Sci*, 2(3), 171-176.
- [14] Ganar, K., Shah, M., Kamdi, B. P., Kurkure, N. V., & Kumar, S. (2017). Molecular characterization of chicken anemia virus outbreaks in Nagpur province, India from 2012 to 2015. *Microbial pathogenesis*, 102, 113-119.
- [15] Andrabi, S. A., Gupta, K., & Singh, A. (2018). Immunohistochemical localization of viral antigens causing immunosuppressive diseases in poultry under field conditions.
- [16] Sreekala, S.M., Gurpreet, K., & Dwivedi, P.N. (2020). Detection and molecular characterization of chicken infectious anaemia virus in young chicks in Punjab region of Northwestern India. *Brazilian Journal of Microbiology*, 51, 805-813.
- [17] McNulty, M. S., McIlroy, S. G., Bruce, D. W., & Todd, D. (1991). Economic effects of subclinical chicken anemia agent infection in broiler chickens. *Avian diseases*, 263-268.
- [18] Dhama, K. (2002). 'Pathogenicity and immunosuppressive effects of chicken infectious anemia virus (CIAV) in chicks and evaluation of diagnostic tests for its detection.' Ph.D. Dissertation, Deemed Univ., Indian Veterinary Research Institute, Izatnagar (UP.), India.
- [19] Schat, K. A. (2003). Marek's disease, Chicken infectious anemia and Immunosuppression: a nasty combination, the poultry research foundation / the world's poultry science association in proceedings of Australian poultry science symposium. *Annual Australian poultry science symposium*, 15: 51-57.
- [20] Adair, B. M. (2000). Immunopathogenesis of chicken anemia virus infection. *Developmental & Comparative Immunology*, 24(2-3), 247-255.
- [21] Noteborn, M., & Koch, G. (1995). Chicken anaemia virus infection: Molecular basis of pathogenicity. *Avian Pathology*, 24:11-31
- [22] Balamurugan, V., & Kataria, J. M. (2006). Economically important non-oncogenic immunosuppressive viral diseases of chicken-current status. *Veterinary Research Communications*, 30(5): 541-66.
- [23] Dhama, K., Mahendran, M., Somvanshi, R., & Chawak, M. M. (2008). Chicken infectious anaemia virus: an immunosuppressive pathogen of poultry-A review.
- [24] van Santen, V. L., Kaltenboeck, B., Joiner, K. S., Macklin, K. S., & Norton, R. A. (2004). Real-time quantitative PCR-based serum neutralization test for detection and titration of neutralizing antibodies to chicken anemia virus. *Journal of virological methods*, 115(2), 123-135.
- [25] Dhama K, Kataria J M, Kumar N S, Tomar S, Dash B B and Ghalsasi G R. 2003. Immunosuppressive effects of the Indian isolate of chicken anaemia virus (CAV) in specific pathogen free chicks. *Indian Journal of Poultry Science* 38(3): 185-94.
- [26] Smyth, J. A., & Schat, K. A. (2013). Virus-induced immunosuppression: chicken infectious anemia. *Immunosuppressive diseases of poultry. IM Gimeno, ed. Servet, Zaragoza, Spain*, 91-121.
- [27] Rosenberger, J. K., & Cloud, S. S. (1998). Chicken anemia virus. *Poultry Sciences*, 77: 1190-92.
- [28] Jeurissen, S. H. M., & De Boer, G. F. (1993). Chicken anaemia virus influences the pathogenesis of Marek's disease in experimental infections, depending on the dose of Marek's disease virus. *Veterinary Quarterly*, 15(3), 81-84.
- [29] Noteborn, M, H. (2004). Chicken anemia virus induced apoptosis: underlying molecular mechanisms. *Veterinary Microbiology*, 98(2): 89-94.
- [30] Hu, L. B., Lucio, B., & Schat, K. A. (1993). Depletion of CD4+ and CD8+ T lymphocyte subpopulations by CIA-1, a chicken infectious anemia virus. *Avian Diseases*, 492-500.

IMPORTANT NON-ONCOGENIC IMMUNO SUPPRESSIVE VIRAL DISEASES OF CHICKENS

- [31] Adair, B. M., McNeilly, F., McConnell, C.D.G & McNulty, M.S. (1993). Characterization of surface markers present on cells infected by chicken anemia virus in experimentally infected chickens. *Avian Diseases* **37**(4): 943-50. Xu, Y. E., & Uu, Z. G. (1995). Influence of chicken infectious anaemia virus infection on the immune system in chicks. *Chinese Journal of Veterinary Sciences*, **15**:33-37.
- [32] Pascucci, S. (1997). Immunosuppressive effect of chicken anaemia virus. *Selezione Veterinaria*, **8-9**: 599-609.
- [33] Todd, D. (2000). Circoviruses: Immunosuppressive threats to avian species: A review. *Avian Pathology*, **29**(5): 373-94.
- [34] Pope, C. R. (1991). Chicken anaemia agent. *Veterinary Immunology and Immunopathology*, **30**: 51-65.
- [35] Bougiouklis, P. A., Sofia, M., Brellou, G., Georgopoulou, I., Billinis, C., & Vlemmas, I. (2007). A clinical case of chicken infectious anemia disease and virus DNA detection in naturally infected broilers in Greece. *Avian diseases*, **51**(2), 639-642.
- [36] Engstrom, B. E., & Luthman, M. (1984). Blue wing disease of chickens: signs, pathology and natural transmission. *Avian Pathology*, **13**(1), 1-12.
- [37] Yuasa, N., Imai, K., & Nakamura, K. (1988). Pathogenicity of chicken anaemia agent in bursectomised chickens. *Avian Pathology*, **17**(2), 363-369.
- [38] Spackman, E., Cloud, S. S., Pope, C. R., & Rosenberger, J. K., (2002). Comparison of a putative second serotype of chicken infectious anemia virus with a prototypical isolate I. Pathogenesis. *Avian Diseases*, **46**: 945-55.
- [39] Taniguchi, T., Yuasa, N., Maeda, M., & Horiuchi, T. (1982). Hematopathological changes in dead and moribund chicks induced by chicken anemia agent. *National Institute of Animal Health Quarterly*, **22**(2), 61-69.
- [40] Otaki, Y., Tajima, M., Saito, K., & Nomura, Y. (1988). Immune response of chicks inoculated with chicken anemia agent alone or in combination with Marek's disease virus or turkey herpesvirus. *The Japanese journal of veterinary science*, **50**: 1040-47.
- [41] Lamichhane, C. M., Snyder, D. B., Goodwin, M. A., Mengel, S. A., Brown, J., & Dickson, T. G. (1991). Pathogenicity of CL-1 chicken anaemia agent. *Avian Diseases* **35**: 515-22.
- [42] Goryo, M., Suwa, T., Umemura, T., Itakura, C., and Yamashiro, S. (1989). Ultrastructure of bone marrow in chicks inoculated with chicken anaemia agent (MSBI-TK5803 strain). *Avian Pathology*, **18**: 329-43.
- [43] Toro, H., Ramirez, A. M., & Larenas, J. (1997). Pathogenicity of chicken anaemia virus (isolate 10343) for young and older chickens. *Avian Pathology*, **26**(3): 485-99.
- [44] Ledesma, N., Fehervari, T., Casaubon, M. T., Lucio, E., & Ratz, F. (2001). Chicken infectious anemia in Mexico: virus identification and serology survey. *Avian diseases*, 788-796.
- [45] Todd, D., McNulty, M. S., Adair, B. M., & Allan, G. M. (2001). Animal Circoviruses. *Advances in Virus Research*, **54**: 1-55.
- [46] Engström, B. E., Fossum, O., & Luthman, M. (1988). Blue wing disease of chickens: experimental infection with a Swedish isolate of chicken anaemia agent and an avian ARV. *Avian Pathology*, **17**(1): 33-50.
- [47] Goodwin, M. A., & Brown, J. (1992). Inability of so-called chicken anaemia agent (CAA) infections to be diagnosed by anemia and hematopoietic organ atrophy alone. *Avian Diseases*, **36**: 353-55.
- [48] Smyth J A, Moffett D A, McNulty M S, Todd O and Mackie D P. 1993. A sequential histopathologic and immunocytochemical study of chicken anemia virus infection at one day of age. *Avian Diseases* **37**: 324-38.
- [49] Hailemariam, Z., Omar, A. R., Hair-Bejo, M., & Giap, T. C. (2008). Detection and characterization of chicken anemia virus from commercial broiler breeder chickens. *Virology journal*, **5**(1), 1-11.
- [50] Haridy, M., Goryo, M., Sasaki, J., & Okada, K. (2009). Pathological and immunohistochemical study of chickens with co-infection of Marek's disease virus and chicken anaemia virus. *Avian Pathology*, **38**(6), 469-483.
- [51] Haridy, M., Sasaki, J., Ikezawa, M., Okada, K., & Goryo, M. (2012). Pathological and immunohistochemical studies of subclinical infection of chicken anemia virus in 4-week-old chickens. *Journal of Veterinary Medical Science*, **74**(6), 757-764.

- [52] Hoop, R. K., & Reece, R. L. (1991). The use of immunofluorescence and immunoperoxidase staining in studying the pathogenesis of chicken anaemia agent in experimentally infected chickens. *Avian Pathology*, 20(2), 349-355.
- [53] Sommer, F., & Cardona, C. (2003). Chicken anemia virus in broilers: dynamics of the infection in two commercial broiler flocks. *Avian Diseases* 47(4): 1466-73.
- [54] Barrios, P. R., Marín, S. Y., Resende, M., Rios, R. L., Resende, J. S., Horta, R. S., & Martins, N. R. S. (2009). Occurrence of chicken anemia virus in backyard chickens of the metropolitan region of Belo Horizonte, Minas Gerais. *Brazilian Journal of Poultry Science*, 11, 135-138.
- [55] Saini, N. S., & Dandapat, A. (2009). Diagnosis and Molecular Characterization of Chicken Anaemia Virus. *Veterinary World* 2(4): 156-60.
- [56] Oluwayelu, D. O. (2009). Detection of chicken infectious anemia virus DNA in archived infectious bursal disease (IBD) tissues and retrospective implications on IBD diagnosis. *Nigerian Veterinary Journal*, 30(2): 77-80.
- [57] Eltahir, Y. M., Qian, K., Jin, W., Wang, P., & Qin, A. (2011). Molecular epidemiology of chicken anemia virus in commercial farms in China. *Journal of Virology*, 8: 145.
- [58] Hiremath, C., Jhala, M. K., Bhandari, B. B., & Joshi, C. G. (2013). Cloning and sequence analysis of VP1, VP2 and VP3 genes of Indian chicken anemia virus. *Iranian Journal of Veterinary Research*, 14(4), 354-357.
- [59] Gholami-Ahangaran, M. (2015). Serological and molecular detection of chicken anaemia virus in Iranian poultry flocks. *Vet. Ital*, 51, 211-215.
- [60] Van den Berg, T. P., Etteradossi, N., Toquin, D., & Meulemans, G. (2000). Infectious bursal disease (Gumboro disease). *Revue scientifique et technique (International Office of Epizootics)*, 19(2), 509-543.
- [61] Mundt, E., & Müller, H. (1995). Complete nucleotide sequences of 5'-and 3'-noncoding regions of both genome segments of different strains of infectious bursal disease virus. *Virology*, 209(1): 10-18.
- [62] Van den Berg, T. P., Gonze, M., & Meulemans, G. (1991). Acute infectious bursal disease in poultry: isolation and characterisation of a highly virulent strain. *Avian pathology*, 20(1), 133-143.
- [63] Sharma, J. M., Kim, I. J., Rautenschlein, S., & Yeh, H. Y. (2000). Infectious bursal disease virus of chickens: pathogenesis and immunosuppression. *Developmental & Comparative Immunology*, 24(2-3), 223-235.
- [64] Saif, Y. M. (1998). Infectious bursal disease and hemorrhagic enteritis. *Poultry Science*, 77(8), 1186-1189.
- [65] Dobos, P. (1979). Peptide Map Comparison of the proteins of infectious bursal disease virus. *Journal of Virology*, 32(3): 1046-50.
- [66] Etteradossi, N. C., & Saif, Y. M. (2008). Infectious bursal disease. In: Saif Y M, Barnes H J, Glisson J R, Fadly A M, Mc Dougald L R and Swayne D E (Eds) *Diseases of Poultry*. 12th Edn. Iowa State Press, Ames, IA, pp. 185-208.
- [67] [68] Mahgoub, H. A. (2012). An overview of infectious bursal disease. *Archives of Virology*, 157: 2047-57.
- [68] Chettle, N. J., Eddy, R. K., Wyeth, P. J., & Lister, S. A. (1989). An outbreak of disease due to chicken anaemia agent in broiler chickens in England. *The Veterinary Record*, 124(9), 211-215.
- [69] Pantin-Jackwood, M. J., Spackman, E., & Day, J. M. (2007). Pathology and virus tissue distribution of Turkey origin reoviruses in experimentally infected Turkey poults. *Veterinary pathology*, 44(2), 185-195.
- [70] Li, K., Courtillon, C., Guionie, O., Allée, C., Amelot, M., Qi, X., & Etteradossi, N. (2015). Genetic, antigenic and pathogenic characterization of four infectious bursal disease virus isolates from China suggests continued evolution of very virulent viruses. *Infection, Genetics and Evolution*, 30, 120-127.
- [71] Mohanty, G. C., Pandey, A. P., & Rajya, B. S. (1971). Infectious Bursal Disease in chickens. *Current Science*, 40: 181-84.
- [72] Tiwari, A. K., Kataria, R. S., Viswas, K. N., Bais, M. V., & Suryanarayana, V. V. (2003). Isolates of infectious bursal disease virus from India are of very virulent phenotype. *Acta virologica*, 47(3), 173-177.
- [73] Mittal, D., Jindal, N., Gupta, S. L., Kataria, R. S., Singh, K., & Tiwari, A. K. (2006). Molecular characterization of Indian isolates of infectious bursal disease virus from broiler chickens: full Length Research Paper. *DNA sequence*, 17(6), 431-439.
- [74] Sreedevi, B., LeFever, L. J., Sommer-Wagner, S. E., & Jackwood, D. J. (2007). Characterization of infectious bursal disease viruses from four layer flocks in the United States. *Avian diseases*, 51(4), 845-850.

IMPORTANT NON-ONCOGENIC IMMUNO SUPPRESSIVE VIRAL DISEASES OF CHICKENS

- [75] Juneja, S. S., Deka, D., Oberoi, M. S., & Singh, A. (2008). Molecular characterization of field isolates and vaccine strains of infectious bursal disease virus. *Comparative immunology, microbiology and infectious diseases*, 31(1), 11-23.
- [76] Mor, S. K., Narang, G., Jindal, N., Mahajan, N. K., Sharma, P. C., & Rakha, N. K. (2010). Epidemiological studies on infectious bursal disease in broiler chickens in Haryana, India. *International Journal of Poultry Science*, 9(4), 395-400.
- [77] Morla, S., Deka, P., & Kumar, S. (2016). Isolation of novel variants of infectious bursal disease virus from different outbreaks in Northeast India. *Microbial pathogenesis*, 93, 131-136.
- [78] Benton, W. J., Cover, M. S., Rosenberger, J. K., & Lake, R. S. (1967). Physicochemical properties of the infectious bursal agent (IBA). *Avian Diseases*, 11(3), 438-445.
- [79] Zhao, Y., Aarnink, A. J. A., Cambra-Lopez, M., & Fabri, T. (2013). Viral shedding and emission of airborne infectious bursal disease virus from a broiler room. *British poultry science*, 54(1), 87-95.
- [80] Müller, H., Scholtissek, C & Becht, H. (1979). The genome of infectious bursal disease virus consists of two segments of double-stranded RNA. *Journal of Virology*, 31(3), 584-589.
- [81] Vasconcelos, A. C., & Lam, K. M. (1994). Apoptosis induced by infectious bursal disease virus. *Journal of General Virology*, 75: 1803-06.
- [82] Ojeda, F., Skardova, I. A., Guarda, M. I., Ulloa, J., & Folch, H. (1997). Proliferation and apoptosis in infection with infectious bursal disease virus: a flow cytometric study. *Avian diseases*, 312-316.
- [83] Tanimura, N., & Sharma, J. M. (1998). In-situ apoptosis in chickens infected with infectious bursal disease virus. *Journal of comparative pathology*, 118(1), 15-27.
- [84] Nieper, H., Teifke, J. P., Jungmann, A., Lohr, C. V., & Muller, H. (1999). Infected and apoptotic cells in the IBDV-infected bursa of Fabricius, studied by double-labelling techniques. *Avian Pathology*, 28(3), 279-285.
- [85] Aliyu, H. B., Sa'idu, L., Jamilu, A., Andamin, A. D., & Akpavie, S. O. (2016). Outbreaks of virulent infectious bursal disease in flocks of battery cage brooding system of commercial chickens. *Journal of Veterinary Medicine*, 2016.
- [86] Skeeles, J. K., Slavik, M., Beasley, J. N., Brown, A. H., Meinecke, C. F., Maruca, S., & Welch, S. (1980). An age-related coagulation disorder associated with experimental infection with infectious bursal disease virus. *American Journal of Veterinary Research*, 41(9), 1458-1461.
- [87] Brown, M. D., Green, P., & Skinner, M. A. (1994). VP2 sequences of recent European 'very virulent' isolates of infectious bursal disease virus are closely related to each other but are distinct from those of 'classical' strains. *Journal of General Virology*, 75(3), 675-680.
- [88] Khan, R. W., Khan, F. A., Farid, K., Khan, I., Tariq, M., Sheikh, F., & Lone, B. (2009). Prevalence of infectious bursal disease in broiler in district Peshawar. *J Agr Biol Sci*, 4, 1-5.
- [89] Nunoya, T., Otaki, Y., Tajima, M., Hiraga, M., & Saito, T. (1992). Occurrence of acute infectious bursal disease with high mortality in Japan and pathogenicity of field isolates in specific-pathogen-free chickens. *Avian Diseases*, 597-609.
- [90] Sharma, J. M., Dohms, J., Walser, M., & Snyder, D. B. (1993). Presence of lesions without virus replication in the thymus of chickens exposed to infectious bursal disease virus. *Avian diseases*, 741-748.
- [91] Inoue, M., Fukuda, M., & Miyano, K. (1994). Thymic lesions in chicken infected with infectious bursal disease virus. *Avian Diseases*, 839-846.
- [92] Tanimura, N., Tsukamoto, K., Nakamura, K., Narita, M., & Maeda, M. (1995). Association between pathogenicity of infectious bursal disease virus and viral antigen distribution detected by immunohistochemistry. *Avian Diseases*, 9-20.
- [93] Dwight, C.H., James, N. M., & Richard, L.W. (2004). *Veterinary microbiology 2 ed.* Asia: Blackwell, pp: 407-419.
- [94] Jackwood, D. H., & Saif, Y. M. (1987). Antigenic diversity of infectious bursal disease viruses. *Avian diseases*, 766-770.
- [95] Williams, A. E., & Davison, T. F. (2005). Enhanced immunopathology induced by very virulent infectious bursal disease virus. *Avian pathology*, 34(1), 4-14.
- [96] Hamoud, M. M., Villegas, P., & Williams, S. M. (2007). Detection of infectious bursal disease virus from formalin-fixed paraffin-embedded tissue by immunohistochemistry and real-time reverse transcription-polymerase chain reaction. *Journal of veterinary diagnostic investigation*, 19(1), 35-42.
- [97] Prabhu, S. N., Singh, A. P., Varghese, B. P., Kumar, M. A., Palanivelu, M., Dhama, K., ... & Singh, R. (2017). Comparative study of very virulent infectious bursal disease virus induced bursal pathology in experimentally infected Indian native Aseel and exotic White Leghorn chicken.
- [98] Tsukamoto, K., Tanimura, N., Mase, M., & Imai, K. (1995). Comparison of virus replication efficiency in lymphoid tissues among three infectious bursal disease virus strains. *Avian Diseases*, 844-852.

IMPORTANT NON-ONCOGENIC IMMUNO SUPPRESSIVE VIRAL DISEASES OF CHICKENS

- [99] Inoue, M., Fujita, A., & Maeda, K. (1999). Lysis of myelocytes in chickens infected with infectious bursal disease virus. *Veterinary pathology*, 36(2), 146-151.
- [100] Pantin-Jackwood, M. J., & Brown, T. P. (2003). Infectious bursal disease virus and proventriculitis in broiler chickens. *Avian diseases*, 47(3), 681-690.
- [101] Bayliss, C.D., Spies, U., Shaw, K., Peters, R. W., Papageorgiou, A., Muller, H. & Bournsnel, M.E.G. (1990). A comparison of thesequences of segment A of four infectious bursal disease virus strains and identification of a variable region in VP2. *Journal of General Virology*, 71, 1303–1312.
- [102] Van der Heide, L. (2000). The history of avian reovirus. *Avian diseases*, 44(3), 638-641.
- [103] Clark, F., Dustan, F., & Lie, M. (2003). Avian Reovirus Infections. *Poultry Science*, 8, 123-126.
- [104] Attoui, H., Becnel, J., Belaganahalli, S., Bergoin, M., Brussaard, C. P., Chappell, J. D. & Lefkowitz, E. J. (2012). Part II: the viruses—the double stranded RNA viruses—family Reoviridae.
- [105] Varela R & Benavente J. 1994. Protein coding of assignment of avian ARV strain S1133. *Journal of Virology* 70: 2974-81.
- [106] Van der Heide, L., & Kalbac, M. (1975). Infectious tenosynovitis (viral arthritis): characterization of a Connecticut viral isolant as a reovirus and evidence of viral egg transmission by reovirus-infected broiler breeders. *Avian Diseases*, 683-688.
- [107] Menendez, N. A., Calnek, B. W., & Cowen, B. S. (1975). Experimental egg-transmission of avian reovirus. *Avian Diseases*, 104-111.
- [108] Al Afaleq, A. I., & Jones, R. C. (1990). Localisation of avian reovirus in the hock joints of chicks after entry through broken skin. *Research in veterinary science*, 48(3), 381-382.
- [109] Al-Muffarej, S. I., Savage, C. E., & Jones, R. C. (1996). Egg transmission of avian reoviruses in chickens: Comparison of a trypsin-sensitive and a trypsin-resistant strain. *Avian Pathology*, 25(3), 469-480.
- [110] Jones, R. C., & Onunkwo, O. (1978). Studies on experimental tenosynovitis in light hybrid chickens. *Avian pathology*, 7(1), 171-181.
- [111] Kibenge, F. S., Gwaze, G. E., Jones, R. C., Chapman, A. F., & Savage, C. E. (1985). Experimental reovirus infection in chickens: Observations on early viraemia and virus distribution in bone marrow, liver and enteric tissues. *Avian Pathology*, 14(1), 87-98.
- [112] Jones, R. C., Islam, M. R., & Kelly, D. F. (1989). Early pathogenesis of experimental reovirus infection in chickens. *Avian Pathology*, 18(2), 239-253.
- [113] Jones, R. C., & Guneratne, J. R. M. (1984). The pathogenicity of some avian reoviruses with particular reference to tenosynovitis. *Avian Pathology*, 13(2), 173-189.
- [114] Lin, H. Y., Chuang, S. T., Chen, Y. T., Shih, W. L., Chang, C. D., & Liu, H. J. (2007). Avian reovirus-induced apoptosis related to tissue injury. *Avian Pathology*, 36(2), 155-159.
- [115] Springer, W. T., Olson, N. O., Kerr, K. M., & Fabacher, C. J. (1983). Responses of specific-pathogen-free chicks to concomitant infections of reovirus (WVU-2937) and infectious bursal disease virus. *Avian Diseases*, 911-917.
- [116] Van der Heide, L., Kalbac, M., & Brustolon, M. (1983). Development of an attenuated apathogenic reovirus vaccine against viral arthritis/tenosynovitis. *Avian diseases*, 698-706.
- [117] Rinehart, C. L., & Rosenberger, J. K. (1983). Effects of avian ARVs on the immune responses of chickens. *Poultry Science*, 62: 1488-89.
- [118] Montgomery, R. D., Villegas, P., Dawe, D. L., & Brown, J. (1985). Effect of avian reoviruses on lymphoid organ weights and antibody response in chickens. *Avian diseases*, 552-560.
- [119] Hill, J. E., Rowland, G. N., Latimer, K. S., & Brown, J. (1989). Effect of cyclosporine A on ARV-infected broilers. *Avian Diseases*, 33: 86-92.
- [120] Cho, B. R. (1979). Effects of avian ARV on Marek's disease (MD): Suppression of MD development. *Avian Diseases* 23: 118-26.
- [121] Moradian A., Thorsen J. & Julian R.J. (1985). - Single and combined infection of specific-pathogen-free chickens with infectious bursal disease virus and an intestinal isolate of reovirus. *Avian Diseases*, 34, 63-72.
- [122] Hirai, K., & Calnek, B. W. (1979). In vitro replication of infectious bursal disease virus in established lymphoid cell lines and chicken B-lymphocytes. *Infection and Immunity*, 25: 964-70.
- [123] Pertile, T. L., Karaka, K., Walser, M. M., & Sharma, J. M. (1996). Suppressor macrophages mediate depressed lymphoproliferation in chickens infected with avian ARV. *Veterinary Immunology and Immunopathology*, 53: 129-45.

- [124] Guo, Z. Y., Giambone, J. J., Liu, Z., Dormitorio, T. V., & Wu, H. (2004). Effect of in ovo administered reovirus vaccines on immune responses of specific-pathogen-free chickens. *Avian diseases*, 48(1), 224-228.
- [125] Bradbury, J. M., Garuti, A. (1978). Dual infection with *Mycoplasma synoviae* and a tenosynovitis inducing ARV in chickens. *Avian Pathology*, 7: 407-09.
- [126] Mosad, S. M., Elmahallawy, E. K., Alghamdi, A. M., El-Khayat, F., El-Khadragy, M. F., Ali, L. A., & Abdo, W. (2023). Molecular and pathological investigation of avian reovirus (ARV) in Egypt with the assessment of the genetic variability of field strains compared to vaccine strains. *Frontiers in Microbiology*, 14, 1156251.
- [127] Montgomery, R. D., Villegas, P., Dawe, D. L., & Brown, J. (1986). A comparison between the effect of an avian reovirus and infectious bursal disease virus on selected aspects of the immune system of the chicken. *Avian diseases*, 298-308.
- [128] Van Loon, A. A. W. M., Koopman, H. C., Kosman, W., Mumczur, J., Szeleszczuk, O., Karpinska, E. & Lütticken, D. (2001). Virology: Isolation of a new serotype of avian reovirus associated with malabsorption syndrome in chickens. *Veterinary quarterly*, 23(3), 129-133.
- [129] Jones, R. C. (2000). Avian reovirus infections. *Revue Scientifique et Technique-Office International des Epizooties*, 19(2), 614-619.
- [130] Songserm, T., Van Roozelaar, D., Kant, A., Pol, J., Pijpers, A., & ter Huurne, A. (2003). Enteropathogenicity of Dutch and German avian reoviruses in SPF white leghorn chickens and broilers. *Veterinary Research*, 34(3), 285-295.
- [131] Zaher, K. (2009). Diagnosis of Avian ARV Infection in Local Egyptian Chicken. *Global Veterinaria*, 3: 227 -31.
- [132] Dong-chao, Z., Ning-ning, Y., Yu-qing, L., Meng, L., Xiao-hui, L., Jian-fang, G., Ke-ke, G., & Tian-ming, J. (2015) Differential Diagnosis of Avian ARV and Pasteurella Mixed Infection in Broiler. *China animal husbandry and veterinary medicine*, 42(12): 3364-70.
- [133] Sharafeldin, T. A., Mor, S. K., Verma, H., Bekele, A. Z., Ismagilova, L., Goyal, S. M., & Porter, R. E. (2015). Pathogenicity of newly emergent turkey arthritis reoviruses in chickens. *Poultry science*, 94(10), 2369-2374.
- [134] Tang, K. N., & Fletcher, O. J. (1987). Application of the avidin-biotin-peroxidase complex (ABC) technique for detecting avian reovirus in chickens. *Avian diseases*, 591-596.
- [135] Sanchez-Cordon, P. J., Hervás, J., De Lara, F. C., Jahn, J., Salguero, F. J., & Gómez-Villamandos, J. C. (2002). Reovirus infection in psittacine birds (*Psittacus erithacus*): morphologic and immunohistochemical study. *Avian diseases*, 46(2), 485-492. The Netherlands, *Avian Pathology*, 36(4):293-299.
- [136] Judith M A, Van den Brand, Manvel R, Paul G, Kik M J L and Dorrestein G M. 2007. ARV infections associated with high mortality in psittaciformes in
- [137] Pitcovski, J., & Goyal, S. M. (2020). Avian reovirus infections. *Diseases of poultry*, 382-400.
- [138] Hess, M. (2013). Avidenovirus infections. In D.E. Swayne, J.R. Glisson, L.R. McDougald, L.K. Nolan, D.L. Suarez & V. Nair (Eds.), *Diseases of poultry*, 13th edn (pp. 290–300). Ames: Wiley-Blackwell.
- [139] Imai, K., Mase, M., Tsukamoto, K., Hihara, H., & Yuasa, N. (1999). Persistent infection with chicken anaemia virus and some effects of highly virulent infectious bursal disease virus infection on its persistency. *Research in Veterinary Science*, 67(3), 233-238.
- [140] Bertran, K., Blanco, A., Antilles, N., Nofrarías, M., Valle, R. M., Cobos, À (2021). A 10-year retrospective study of inclusion body hepatitis in meat-type chickens in Spain (2011–2021). *Viruses*, 13, 2170.
- [141] Norrby, E. (1969). The structural and functional diversity of adenovirus capsid components. *Journal of General Virology*, 5, 221–236.
- [142] Raue, R., & Hess, M. (1998). Hexon based PCRs combined with restriction enzyme analysis for rapid detection and differentiation of fowl adenoviruses and egg drop syndrome virus. *Journal of virological methods*, 73(2), 211-217.
- [143] Hess, M. J. A. P. (2000). Detection and differentiation of avian adenoviruses: a review. *Avian Pathology*, 29(3), 195-206.
- [144] Marek, A., Günes, A., Schulz, E., & Hess, M. (2010). Classification of fowl adenoviruses by use of phylogenetic analysis and high-resolution melting-curve analysis of the hexon L1 gene region. *Journal of virological methods*, 170(1-2), 147-154.
- [145] Schachner, A., Matos, M., Grafl, B., & Hess, M. (2018). Fowl adenovirus-induced diseases and strategies for their control—a review on the current global situation. *Avian Pathology*, 47(2), 111-126.

- [146] Anjum, A. D., Sabri, M. A., & Iqbal, Z. (1989). Hydropericarditis syndrome in broiler chickens in Pakistan. *The Veterinary Record*, *124*(10), 247-248.
- [147] Gowda, R.N.S. & Satyanarayana, M.L. (1994). Hydropericardium syndrome in poultry. *Indian Journal of Veterinary Pathology*, *18*, 159–161.
- [148] Kumar, R., Chandra, R., Shukla, S. K., Agrawal, D. K., & Kumar, M. (1997). Hydropericardium syndrome (HPS) in India: a preliminary study on the causative agent and control of the disease by inactivated autogenous vaccine. *Tropical Animal Health and Production*, *29*(3), 158-164.
- [149] Helmboldt, C. F., & Frazier, M. N. (1963). Avian hepatic inclusion bodies of unknown significance. *Avian diseases*, *7*(4), 446-450.
- [150] Pereira, C. G., Marin, S. Y., Santos, B. M., Resende, J. S., Resende, M., Gomes, A. M., & Martins, N. R. S. (2014). Occurrence of Aviadenovirus in chickens from the poultry industry of Minas Gerais. *Arquivo Brasileiro de Medicina Veterinária e Zootecnia*, *66*, 801-808.
- [151] Gupta, A., Ahmed, K. A., Ayalew, L. E., Popowich, S., Kurukulasuriya, S., Goonewardene, K. & Gomis, S. (2017). Immunogenicity and protective efficacy of virus-like particles and recombinant fiber proteins in broiler-breeder vaccination against fowl adenovirus (FAvV)-8b. *Vaccine*, *35*(20), 2716-2722.
- [152] Ahmad, I., Afzal, M., Malik, M.I., Hussain, Z., & Hanif, W. (1989). Studies on the disease pattern and etiology of hydropericardium syndrome (Angara disease) in broiler chickens in Pakistan. *Pakistan Journal of Agriculture Research*, *10*, 195–199.
- [153] Domanska-Blicharz, K., Tomczyk, G., Smietanka, K., Kozaczynski, W., & Minta, Z. (2011). Molecular characterization of fowl adenoviruses isolated from chickens with gizzard erosions. *Poultry Science*, *90*(5): 983-989.
- [154] Saifuddin, M., & Wilks, C. R. (1991). Vertical transmission of avian adenovirus associated with inclusion body hepatitis. *New Zealand Veterinary Journal*, *39*(2), 50-52.
- [155] Deepak, J.N., Kataria, J.M., Verma, K.C. & Somvansh, R. (1998). Immunosuppressive effects of fowl adenovirus serotype-4 isolated from cases of hydropericardium-hepatitis syndrome. *Proceeding of the 5th International Veterinary Immunology Symposium of the International Union of Immunological Societies (VIC IUIS)*, (PAU, Ludhiana, India, 8–13 November), 197.
- [156] Naem, K., Niazi, T., Malik, S. A., & Cheema, A. H. (1995). Immunosuppressive potential and pathogenicity of an avian adenovirus isolate involved in hydropericardium syndrome in broilers. *Avian Diseases*, *723-728*.
- [157] Mazaheri, A., Prusas, C., Voss, M., & Hess, M. (1998). Some strains of serotype 4 fowl adenoviruses cause inclusion body hepatitis and hydropericardium syndrome in chickens. *Avian Pathology*, *27*(3), 269-276.
- [158] Schonewille, E., Singh, A., Göbel, T. W., Gerner, W., Saalmüller, A., & Hess, M. (2008). Fowl adenovirus (FAvV) serotype 4 causes depletion of B and T cells in lymphoid organs in specific pathogen-free chickens following experimental infection. *Veterinary Immunology and Immunopathology*, *121*(1-2), 130-139.
- [159] Zhao, J., Zhong, Q. I., Zhao, Y., Hu, Y. X., & Zhang, G. Z. (2015). Pathogenicity and complete genome characterization of fowl adenoviruses isolated from chickens associated with inclusion body hepatitis and hydropericardium syndrome in China. *Plos one*, *10*(7), e0133073.
- [160] Winterfield, R.W., Fadly, A.M. & Gallina, A.M. (1973). Adenovirus infection and disease. I. Some characteristics of an isolate from chickens in Indiana. *Avian Diseases*, *17*, 334–342.
- [161] Grimes, T.M., King, D.J., Kleven, S.H. & Fletcher, O.J. (1977). Involvement of a type-8 avian adenovirus in the etiology of inclusion body hepatitis. *Avian Diseases*, *21*, 26–38.
- [162] Hair-Bejo M (2005). Inclusion body hepatitis in a flock of commercial broiler chickens. *Jurnal Veterinar Malaysia*, *7*: 23-26.
- [163] Tanimura, N., Nakamura, K., Imai, K., Maeda, M., Gobo, T., Nitta, S., Ishihara, T. & Amano, H. (1993). Necrotizing pancreatitis and gizzard erosion associated with adenovirus infection in chickens. *Avian Diseases*, *37*, 606–611.
- [164] Goodwin, M.A., Latimer, K.S., Resurreccion, R.S., Miller, P.G. & Campagnoli, R.P. (1996). DNA in situ hybridization for the rapid diagnosis of massive necrotizing avian adenovirus hepatitis and pancreatitis in chicks. *Avian Diseases*, *40*, 828–831.
- [165] Matos, M., Grafl, B., Liebhart, D. & Hess, M. (2016). The outcome of experimentally induced inclusion body hepatitis (IBH) by fowl aviadenoviruses (FAvVs) is crucially influenced by the genetic background of the host. *Veterinary Research*, *47*, 69.
- [166] Shivachandra, S.B., Sah, R.L., Singh, S.D., Kataria, J.M. & Manimaran, K. (2003). Immunosuppression in broiler chicks fed aflatoxin and inoculated with fowl adenovirus serotype-4 (FAV-4) associated with hydropericardium syndrome. *Veterinary Research Communications*, *27*, 39–51

IMPORTANT NON-ONCOGENIC IMMUNO SUPPRESSIVE VIRAL DISEASES OF CHICKENS

- [167] McFerran, J. B., & Smyth, J. A. (2000). Avian adenoviruses. *Revue scientifique et technique (International Office of Epizootics)*, 19(2), 589-601.
- [168] Lim, T. H., Kim, B. Y., Kim, M. S., Jang, J. H., Lee, D. H., Kwon, Y. K., & Song, C. S. (2012). Outbreak of gizzard erosion associated with fowl adenovirus infection in Korea. *Poultry science*, 91(5), 1113-1117.
- [169] Okuda, Y., Ono, M., Yazawa, S., Imai, Y., Shibata, I. & Sato, S. (2001). Pathogenicity of serotype 1 fowl adenovirus in commercial broiler chickens. *Avian Diseases*, 45, 819–827.
- [170] Ono, M., Okuda, Y., Yazawa, S., Imai, Y., Shibata, I., Sato, S. & Okada, K. (2003). Adenoviral gizzard erosion in commercial broiler chickens. *Veterinary Pathology*, 40, 294– 303.
- [171] Grafl, B., Liebhart, D., Günes, A., Wernsdorf, P., Aigner, F., Bachmeier, J., & Hess, M. (2013). Quantity of virulent fowl adenovirus serotype 1 correlates with clinical signs, macroscopical and pathohistological lesions in gizzards following experimental induction of gizzard erosion in broilers. *Veterinary Research*, 44(1), 1-8.
- [172] Ganesh, K., Raghavan, R., Gowda, R. N. S., Satyanarayana, M. L., & Suryanarayana, V. V. S. (2002). Purification and characterization of the aetiological agent of hydropericardium hepatitis syndrome from infected liver tissues of broiler chickens. *Tropical animal health and production*, 34, 7-17.
- [173] Oberoi, M., A. Singh., & B. Singh. 1996. Isolation of avian adenovirus from outbreaks of inclusion body hepatitis/hydropericardium syndrome in poultry. *Indian. J. Virol.* 12:123– 124.
- [174] Schonewille, E., R. Jaspers, G. Paul., & M. Hess. (2010). Specific pathogen-free chickens vaccinated with a live FAdV-4 vaccine are fully protected against a severe challenge even in the absence of neutralizing antibodies. *Avian. Dis.* 54:905–910.
- [175] Niczyporuk, J. S., Wozniakowski, G., & E. Samorek-Salamonowicz, E. (2015). Application of cross-priming amplification (CPA) for detection of fowl adenovirus (FAdV) strains. *Arch. Virol.* 160:1005–1013.
- [176] Raue R, Gerlach H, and Müller H (2005). Phylogenetic analysis of the hexon loop 1 region of an adenovirus from psittacine birds supports the existence of a new psittacine adenovirus (PsAdV). *Archives of Virology*, 150: 1933-1943
- [177] Mase, M., Mitake, H., Inoue, T., & Imada, T. (2009). Identification of group I-III avian adenovirus by PCR coupled with direct sequencing of the hexon gene. *Journal of Veterinary Medical Science*, 71(9), 1239-1242.
- [178] Romanova, N., Corredor, J. C., & Nagy, É. (2009). Detection and quantitation of fowl adenovirus genome by a real-time PCR assay. *Journal of virological methods*, 159(1), 58-63.
- [179] Steer, P. A., Kirkpatrick, N. C., O'Rourke, D., & Noormohammadi, A. H. (2009). Classification of fowl adenovirus serotypes by use of high-resolution melting-curve analysis of the hexon gene region. *Journal of clinical microbiology*, 47(2), 311-321.
- [180] Marek, A., Günes, A., Schulz, E., & Hess, M. (2010). Classification of fowl adenoviruses by use of phylogenetic analysis and high-resolution melting-curve analysis of the hexon L1 gene region. *Journal of virological methods*, 170(1-2), 147-154.
- [181] Günes, A., Marek, A., Grafl, B., Berger, E., & Hess, M. (2012). Real-time PCR assay for universal detection and quantitation of all five species of fowl adenoviruses (FAdV-A to FAdV-E). *Journal of virological methods*, 183(2), 147-153.
- [182] Verma, K.C., Malik, B.S., & Kumar, S. (1971). A preliminary report on the isolation and characterization of chicken embryo lethal orphan virus from poultry. *Indian Journal of Animal Science*, 40, 1002–1003
- [183] Adedeji, A. J., Sati, N. M., Pewan, S. B., Ogbu, K. I., Adole, J. A, Lazarus, D. D., Ijiwo, S. J, Okpanachi, A., Nwagbo, I. O., Joannis, T. M., & Abdu, P. A. (2016). Concurrent infections of chicken infectious anemia and infectious bursal disease in 5 weeks old pullets in Jos, Plateau State, Nigeria. *Veterinary Sciences: Research and Reviews*, 2(3): 60-65
- [184] Zhang, Y., Cui, N., Han, N., Wu, J., Cui, Z., & Su, S. (2017). Depression of Vaccinal Immunity to Marek's Disease by Infection with Chicken Infectious Anemia Virus. *Frontiers in Microbiology*, 8:1863.
- [185] McNeilly, F., Smyth, J. A., Adair, B. M., & McNulty, M. S. (1995). Synergism between chicken anemia virus (CAV) and avian ARV following dual infection of 1-day-old chicks by a natural route. *Avian Diseases*, 39(3): 532-37.
- [186] Sharma J M, Dohms J E & Metz A L. (1989). Comparative pathogenesis of serotype 1 and variant serotype 1 isolates of infectious bursal disease virus and their effect on humoral and cellular immune competence of specific-pathogen-free chickens. *Avian Diseases* 33: 112-24.

- [187] Miles, M. A., Reddy, S. M., & Morgan, R.W. (2001). Coinfection of Specific-PathogenFree Chickens with Marek's Disease Virus (MDV) and Chicken Infectious Anemia Virus: Effect of MDV Pathotype. *Avian Diseases*, **45(1)**: 9-18.
- [188] Yang, M., Cui, Z. Z., Su, S., Zhang, H., & Wang, X. (2010). Synergic suppression effect of co-infection of chicken infectious anemia virus and Marek's disease virus in SPF Chicken. *Chinese Journal of Animal Infectious Disease*, **4**: 003.