

ADVANCES IN SPACE MAINTAINERS

Abstract

Caries is one of the primary causes for loss of teeth in children. That apart, trauma, infection and crowding are other factors. Space maintenance due to lost teeth especially molars is necessary till the eruption of the permanents. Space maintainers are appliances used to maintain space created by the lost teeth. Due to delay in treatments just after extraction or early loss of space it becomes difficult for permanent successor to occupy the space. To prevent such a situation, space maintainers are used to preserve arch integrity so as to allow a normal eruption of the successor. There are many space maintainers that have been introduced in Pediatric dentistry. This chapter will deal with the advancements in this aspect of Pediatric Dentistry. Some of the examples can be digital space maintainers, dental-chairside space maintainers and the like.

Keywords: Pediatric dentistry, orthodontic, Maintainers.

Author

Dr. Ashwini Koti

Assistant Professor at SMBT Dental
College and Hospital
Department of Pediatric and Preventive
Dentistry
ashwinikoti7788@gmail.com

I. INTRODUCTION

Pediatric dentistry focuses more on conservative-restorative aspects rather than total pediatric patient care. Thus, all aspects of oral health care including diagnosis of disease, its prevention, medicinal aspect, restoration and correction of malocclusion are increasing the responsibilities of the pediatric dentist.¹

A sequence of events occurs in an orderly and timely fashion as the occlusion develops from the primary dentition through the transitional (or mixed) dentition to the permanent dentition. This sequence causes good functional, esthetic, and more stable occlusion. If this is altered, problems arise that might affect the final occlusal status of the permanent dentition.²

Early orthodontic intervention is done to improve dentoalveolar, skeletal and muscular development before complete eruption of the permanent dentition. The early orthodontic intervention can be broadly classified as preventive orthodontics and interceptive orthodontics. This treatment is to intercept a developing problem or to correct existing early malocclusion.³

According to the American Board of Orthodontics in 1977, most participants considered early interventions as viable option in many malocclusion cases. Early treatment is done for more benefits including better use of the patient growth potential, reduced need of extractions and orthognathic surgery, reduce risk of adverse iatrogenic effects, better patient compliance, and better and more stable results.⁴

Whenever there is premature loss of primary tooth, treatment like passive space maintenance, active tooth movement with space regaining, or a combination of both is required to optimize normal development of occlusion.

The premature loss of primary teeth due to caries, trauma, ectopic eruption, or other causes may lead to undesirable tooth movements of primary and/or permanent teeth including loss of arch length.⁵ Hence space supervision is important.

One of the important functions of the primary dentition is to maintain the arch length, so that there is sufficient space for permanent dentition to erupt. The three important features of primary dentition are spacing, anthropoid spaces mesial to the maxillary canine and distal to mandibular canines, and straight or mesial step primary second molar occlusion.⁶

Exfoliation of primary teeth and eruption of successor teeth is a normal physiological process. But sometimes there is a premature loss of primary tooth/ teeth. In such instance, space maintainer is the best way to maintain the arch space. It was stated that, space maintainers maintain function, preserve arch length and also maintain esthetics.⁷

Space maintainers are orthodontic appliance that is used to replace one or more primary teeth and maintain the space for the succedaneous tooth. In cases of primary tooth loss, a space maintainer preserves integrity of the arch and guides normal occlusal development of the mixed dentition. The remaining jaw growth and all the factors involved

for development of occlusion to be studied so that the space maintainer does not become a harmful action to the child and cause embarrassment to the clinician.⁸

Space maintainers can be classified as functional, advantages include: helps in mastication, prevents extrusion and the antagonist is its aesthetic.⁹

Although Digitalization in dentistry is not new concept, but its usage had just started in Pediatric Dentistry. Three-dimensional (3D) printing also called as additive manufacturing or rapid prototyping.¹⁰ It is a procedure in which 3D objects are made from a digital file. The digital 3D model is saved in 'Standard Tessellation Language' (STL) format which is made into a 3D object with the help of layer by layer design format.

A pediatric dentist is usually the primary person to notice the effects of premature loss of primary teeth. Thus, the pediatric dentist should diagnose at the earliest and take necessary measures to prevent the harmful effects on erupting dentition, psychology and overall wellbeing of the child.

Hence, Pediatric Dentist should have an active approach that may decrease loss of arch length and reduce complex orthodontic treatment in the future. Considering all the pitfall of conventional space maintainers, this chapter focuses on the digital space maintainers in pediatric dentistry.

II. DEFINITIONS AND TERMINOLOGIES

1. **Wright and Kennedy¹¹** stated that space maintenance and space control are not necessarily synonymous.
2. **J.C. Brauer (1959)** the term 'space maintainer' indicates to an appliance designed to retain a given area or space, generally in the primary and mixed dentitions.¹²
3. **Martinez and Elsbach (1984)** 'space maintainers' are the orthodontic appliances used to prevent loss of arch length.¹³
4. **SPACE CONTROL; Gainsforth in 1955** defined it as careful supervision of the developing dentition; it reflects an understanding of the dynamic nature of occlusal development.¹⁴
5. **Keith J. Ryan (1964)**, space maintenance is the process of maintaining a space in a given arch previously occupied by a tooth or a group of teeth.¹⁵
6. **Boucher's clinical dental terminology**, SPACE MAINTAINER is a fixed or removable appliance designed to preserve the space created by the premature loss of a tooth.¹⁶
7. **FIXED SPACE MAINTAINER** is a space maintainer not intended to be removable by the patient.
8. **REMOVABLE SPACE MAINTAINER** is a space maintainer which can be easy to remove for cleansing and /or adjustment according to patient's requirement.

9. The term interceptive orthodontics means timely and orderly management of adverse events of a developing occlusion.
10. According to **Graber**, Interceptive orthodontics refers to the “Measures undertaken to intercept a malocclusion that has already developed or is developing, and the goal is to restore a normal function”.¹⁷
11. According to **Ackerman and Proffit (1980)**, Interceptive orthodontics can be defined as, “Elimination of existing interferences with the key factors involved in the development of the
12. dentition”¹⁷
13. **American Association of Orthodontists (1969)** defined it as that phase of science and art of orthodontics employed to recognize and eliminate the potential irregularities and mal positions in the developing dentofacial complex.¹⁸

III. OBJECTIVES OF SPACE MAINTAINER

1. To prevent loss of arch length, width, perimeter by not affecting the already existing dentition
2. To preserve normal occlusal plane and primate spaces.
3. Preservation of integrity of dental arches.
4. Anteriorly it aids in phonetics, esthetics and posteriorly it helps in mastication in some cases.
5. To promote appropriate transition of the primary, mixed, and permanent dentitions.

IV. INDICATIONS AND CONTRAINDICATIONS OF SPACE MAINTAINERS: INDICATIONS: (FINN)¹⁹

1. In cases of early loss of anterior primary teeth.
2. To prevent emergence to deleterious habits like tongue thrusting due to premature exfoliation of anterior teeth.
3. To maintain esthetics anteriorly and to reduce psychological trauma.
4. To prevent supra-eruption of opposing arch tooth into space loss during to premature loss of tooth.
5. If the space maintainer would lessen the future orthodontic treatment.
6. To improve and restore physiology of child’s masticatory and dental health optimally.
7. When a supernumerary tooth prevents eruption of a permanent central incisor, the space may be held before operation and while the tooth moves into position.

CONTRAINDICATIONS OF SPACE MAINTAINERS: (FINN)¹⁹

1. If the radiograph of the extraction region shows that one-third of the root of succedaneous tooth is already calcified.
2. When the space left by the prematurely lost primary tooth is greater than the space needed for the permanent successor as indicated radiographically.
3. If the space shows no signs of closing.

4. When there is general lack of sufficient arch length and where space maintainer would further complicate existing malocclusion.
5. When succedaneous tooth is absent.
6. When the radiograph shows no bone coverage over the erupting permanent tooth, which means that the tooth is about to erupt in few months.
7. When space available after premature loss of deciduous tooth is more for alignment of permanent teeth.
8. When reduction of tooth units aids orthodontic treatment and lead to a more acceptable occlusion.
9. When some or all the permanent teeth are missing children who have high caries risk.
10. Children who fail to cooperate.
11. Children who have poor oral hygiene

V. PLANNING OF SPACE MAINTENANCE:²

The following considerations are important when space maintenance is considered after the untimely loss of primary teeth.

1. Time elapsed since loss of tooth/ teeth
2. Dental age of the patient
3. Amount of bone that is above the unerupted tooth in the radiograph
4. Eruption sequence of teeth
5. Delayed eruption of the permanent tooth
6. If the permanent teeth in the same area of the opposing dentition have erupted, it is advisable to incorporate an occlusal stop in the appliance to prevent supra-eruption in the opposing arch during the space maintenance period.
7. Presentation of problems to parents

VI. CLASSIFICATION OF SPACE MAINTAINERS

According to **Hitchcock**²⁰ in 1963, space maintainers may be classified in various ways:

- Removable or fixed or semifixed.
- With bands or without bands.
- Functional or non-functional.
- Active or passive.
- Certain combinations of the above.

Space maintainers are classified by **Raymond C. Thurow**²¹ in 1970 as:

- Removable
 - Complete arch
 - Lingual arch
 - Extra oral anchorage
- Individual tooth

Hinrichsen (1962)²² classified space maintainers as follows:

1. Fixed Appliances

Class-I

- Non-functional types
 - Bar type
 - ii. Loop type
- **Functional Types**
 - Pontic type
 - Lingual arch type

Class-II Cantilever type (Distal shoe, Band & loop).

2. Removable

Acrylic partial dentures.

R.J. Andlaw and W.P. Rock (1987)²³

- Band / crown and loop
- Palatal arch
- Lingual arch
- Stainless steel wire and composite
- Removable space maintainers

Graber (1994)¹⁷ mentioned by **Bratu E et al. (2005)**

- Fixed space maintainers:
 - Functional
 - Non-functional Space maintainer with extension
 - Fixed lingual arch
 - Semi-fixed lingual arch
- Removable space maintainers

VII. DIGITAL SPACE MAINTAINERS

Space maintainers that are made using CAD-CAM or 3Dimensional print method with newer and biocompatible materials are regarded as “Digital Space Maintainers”. Digital impressions have increased efficiency, more comfortable to the patient, and low cost. Digital impressions are commonly used in Dentistry, but their use in Pediatric Dentistry has started now and is helpful for both patient and Dentist. Digital scans can also be done by auxiliary team members if state laws allow, giving time for dentists to work on other procedures. Wherever there are lack of dental laboratory facilities nearby, digital impression are more convenient to transfer quickly lab anywhere in across the country. It is highly economical, reduces distortion of impressions/models, and minimizes turnaround time for each case.²⁴

Materials used for fabrication of digital space maintainers

1. **PEEK Polymer:** Polyetheretherketone material has good mechanical properties. Material is rigid and biocompatible. They are resistant to chemicals, stable at high-temperature,

good dimensional stability, and PEEK also has a wide range of processing possibilities. Patients allergic to metals or dislike the appearance, taste or heavy weight of metal, can use PEEK because it appears more natural and is tooth-coloured.

According to a 2015 study, PEEK has many advantages in orthodontics, thus it is considered as a suitable material for fabrication of metal-free orthodontic wire.²⁵ PEEK is used to make the framework and prosthetic teeth in the same design module for detachable, functional varieties of space maintainers releasing a fully integrated design. Thus, this technique is preferable to others where they use self-cure resin and artificial teeth.

A 9- month follow-up study using PEEK polymer was done by Ierardo et al on three patients for making a CAD-CAM space maintainer.²⁶ They fabricated a lingual arch, a band and loop, and a removable space maintainer and obtained satisfactory results. Digital band and loop space maintainers made of PEEK polymer were assessed by Kun et al.²⁷ in children with unilateral loss of either the first or second molars and were found to be 75% lighter than conventional space maintainers. In an *in vitro* investigation, Guo et al.²⁸ compared digitally made Removable Space Maintainers made with PEEK polymer to conventional Removable Space Maintainers (RSMs). Study results showed removable space maintainers made by digital method showed better fit, thus indicating that the technique can be used in various clinical applications.²⁸ This is mainly because the conventional technique of making has many steps which can bring about faults during polymerization shrinkage of self-curing resin and there is a need to grind and polish removable space maintainers, which is not needed in case of digitally made removable space maintainers.

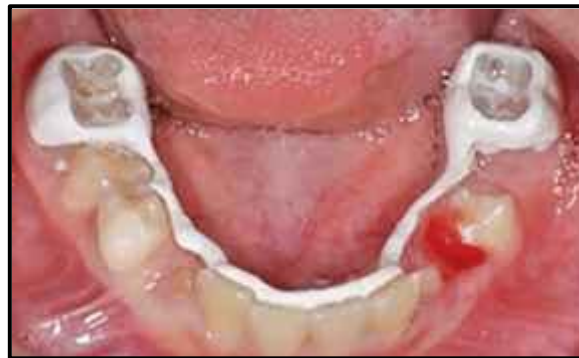

Figure 1: Case report, Gaetano Ierardo using PEEK as a space maintainer²⁶

- BruxZir:** Fracture toughness of BruxZir is three to five times that of standard zirconia, and it has a flexural strength of up to 1,465 MPa.²⁹ These properties impart the material an excellent property to resist masticatory forces in the mouth. The material has got minimal thermal expansion, which will allow it to stay in the mouth without changing shape or becoming loose in the teeth. Soni et al was the first person to publish paper by using digital method to make a space maintainer. He used BruxZir for fabrication of appliance to treat a 6-year old female patient. To prevent distortion of space maintainer, the space maintainer was made in such a way that it was supported by both canine and primary second molar. This gave better retention to appliance, prevented tooth tipping,

and helped in even distribution of masticatory forces delivered across the extracted tooth area. Six months follow up results were satisfactory.

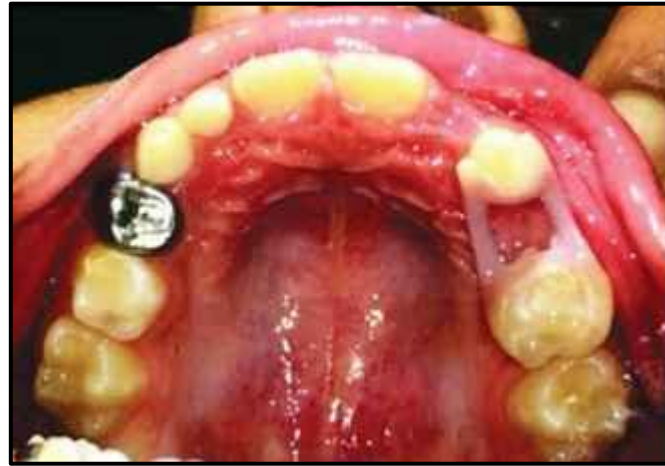

Figure 2: Six month follow-up of appliance, by HK Soni³⁴

- 3. Trilor:** Trilor is a CAD/CAM made fiber-reinforced composite (FRC) resin. This is a metal-free, biocompatible alternative material. Main advantages include its longevity, elastic property, light weight, biocompatibility, and fixability. Beretta and Cirulli³⁰ introduced a metal-free CAD-CAM device to fabricate relatively safe appliances for patients with special health care needs, who undergo magnetic resonance imaging (MRI) scans routinely in the head and neck region. Authors made a Nance palatal arch space maintainer using Trilor and bonded it directly on the palatal surface of the first primary molar.

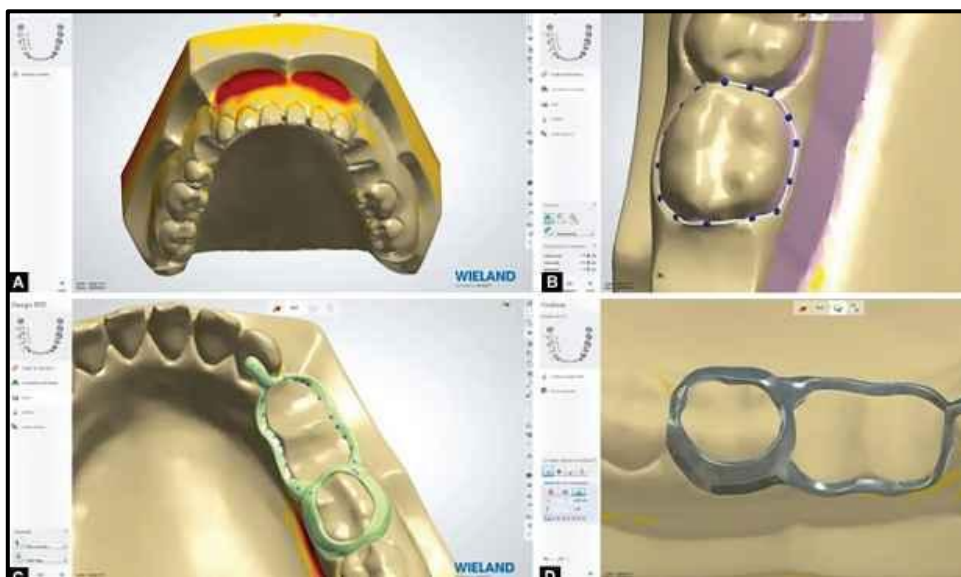


Figure 3: Digital pattern, by Gaetano Ierardo²⁶

- **Steps in Fabrication Using CAD/CAM Technology:** CAD-CAM processing starts with impression taking from the dentist, either digital or conventional method. Sirona was first person to introduce the chairside CAD-CAM technology, the CEREC system, it benefits dentists to make and fabricate restorations chair side in dental office.³¹ Chairside and laboratory CAD-CAM manufacturing technique makes restorations/ appliances fabrication quicker and hassle free.

There are 3 routine steps in digital restoration workflow:

Step 1: Take impression, make models, digitalization of models is done using an oral scanner or direct intra-oral impression are made and models are obtained.

Step 2: Scanned object is subjected to light beam from all direction, and minute cameras film it. Its outcome looks like a cloud of points since the scans are multiple and detected across the entire model. The virtual model is made by connecting the dots and reconstructing a pattern of tiny polygons.

Step 3: After procuring a digital model, it is uploaded into the CAD (computer-aided design) software system. Using different tools, the model can be viewed from different angles and magnifications, which makes it easier to analyze and helps in developing a personalized device. This technology helps in making devices and to determine different parameters like material thickness, its retention, undercuts to be made, and space needed for cementation.

Step 4: After this, the file is sent to CAM, here milling is started for fabrication of the device. It is a type of fabrication method that it involved in subtracting a block of chosen material from a previously specified form using CAD software (requires about 1 hour).

4. **Three-dimensional (3D) Printing Technology for Space Maintainers:** In this technology, a digital file is used to build a layer-by-layer design for a 3D object of any shape or geometry. The digital 3D model is saved in STL format and then sent to the 3D printer where the layer by layer design of an entire 3D object is made. 3D-printed object is obtained by addition process. Each layer is seen as a thin sliced horizontal cross-section of an eventual object.

These layers are seen combined together to form a final object. Pawar³³ was the first person to use digital 3D printing to fabricate space maintainers, one was titanium-based powdered metal and other one was clear photopolymer resin. He highlighted the importance of 3D printing technology in pediatric dentistry.

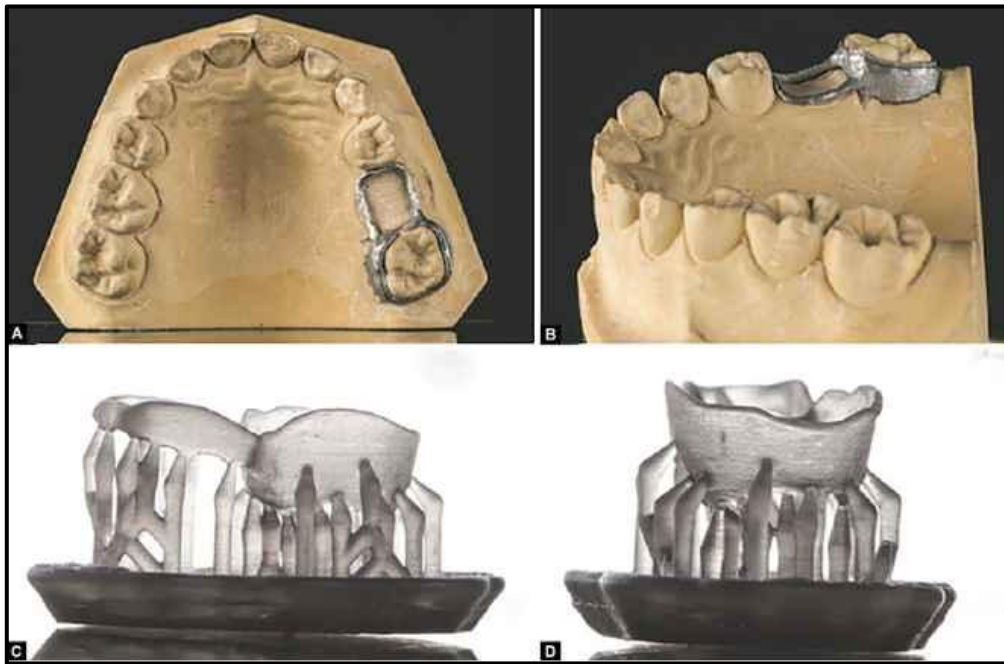


Figure 4: A & B shows metallic 3D-printed space maintainer of ti-based powdered metal material and C & D shows a clear photopolymer resin” by Pawar³³

Advantages²⁶⁻²⁹ of digitally fabricated space maintainer devices and its success outcome

Advantages	Success outcome
1. Esthetic	High patient acceptance
2. Metal-free	Good for patients having metal allergy, nickel allergy and special health care needs patient who need to undergo MRI routinely.
3. Accurate and precise	Minimal deformation and errors, breakage and de-cementation
4. Less fabrication time	Fewer appointment needed hence improved patient compliance
5. Single unit appliance	Improved strength of appliance prevents fracture and reduces failure rate.
6. Smooth surface	Makes cleaning easier which causes lesser plaque deposition and overall improvised oral health
7. Lightweight	Makes patient feel comfortable
8. No band pinching required	No harm to the gingiva

Disadvantages³⁴

- Overall expensive treatment.
- Laboratory is mandatory. Cannot be done chair side.
- Expertise to fabricate appliance is needed.

VIII. FUTURE PERSPECTIVE

Further studies are needed to evaluate the longevity, its effect on gingival health, patient and parent compliance, economy and wide acceptability of digitally manufactured space maintainers. Clinical and comparative research are required. Future research should focus more on low-cost materials. Furthermore, research on 3D print space maintainers in pediatric dentistry has yet to be done on larger samples. Usage of 3D print improves the accuracy and perfection making work less time consuming and hassle free .

IX. CONCLUSION

Pediatric dentistry's space maintainers have advanced towards custom orthodontics. Appliances fabricated using digital techniques are accurate and long-lasting. Thanks to recent technology for eliminating time-consuming manual fabrication stages. With the arrival of digital age, more 'CLINICIANS' will likely begin to use it in their daily practices.

REFERENCES

- [1] Ngan PW et al. Orthodontic treatment in the primary dentition. *Am Dent Assoc.* 1988; 116:336-40.
- [2] Dean JA, McDonald RE, Avery DR. Management of the developing occlusion. In: McDonald RE, Avery DR, Dean JA, eds. *Dentistry for the Child and Adolescent.* 8th ed. St. Louis, Mo: Mosby; 2004:631-68.
- [3] McNamara J. A. Jr. and Brudon W. L.: *Orthodontic and Orthopaedic Treatment in the Mixed Dentition* 3rd edition, Michigan: Needham Press. 1-7p (1993).
- [4] Lahcen O. and Laila L.: Early Treatments in Orthodontics, *Principles in Contemporary P-251-276.* (2011)
- [5] Brothwell DJ. Guidelines on the use of space maintainers following premature loss of primary teeth. *J Can Dent Assoc.* 1997;63(10):753-66.
- [6] Kuroi J. and Koch G.: "The deciduous dentition and occlusion" In: Shaw W. C. *Orthodontics and Occlusal Management* Oxford: Wright, Butterworth-Heinemann Ltd. 39-41p. (1993).
- [7] Mathewson RJ. *Fundamentals of Pediatric Dentistry.* 3rd Edition. Quintessence Publishing Co., Inc;1995:326-39
- [8] Hinrichsen C.F.L. Space Maintenance in Pedodontics. *Australian Dent J.* 1962;7:451-456. In *Year Book of Dentistry*, p.169-173, 1963-64.
- [9] Agrawal N, Kundu D, Agrawal K, Singhal A. Comparison of longitudinal changes in clinical periodontal parameters of canines and first molars treated with fixed orthodontic appliances. *Am J Orthod Dento facial Orthop.* 2016;149:325–30.
- [10] Dawood A, Marti BM, Sauret-Jackson V, Darwood A. 3D printing in dentistry. *Br Dent J* 219(11):521-529, 2015.
- [11] Wright GZ, Kennedy DB. Space control in the primary and mixed dentitions. *Dent Clin North Am.* 1978;22:579-601.
- [12] Brauer J.C et al. *Dentistry for children*, fourth edition. McGraw-Hill Book Company Inc; 1959:396-435.
- [13] Martinez, Norman P, Elsbach, Henry G. Functional maintenance of arch length. *J. Dent. Child* 1984;51:190-3.
- [14] Gainsforth. Quoted in Brauer, J.C, Demerit, W.W, Higley L.B. et al *Dentistry for children* fourth edition. Mc Graw Hill Book Company, Inc; 1956:396-435.
- [15] Ryan Keith J. Understanding and use of space maintenance procedures. *J Dent Child.* 1964;3:21-25. In *Year Book of Dentistry.*
- [16] Muthu. *Pediatric dentistry: principles and practice.* 2nd edition. Elsevier.2011.
- [17] Graber T. M &Swain. *Orthodontics, current principles and techniques.* St. Louis: C.V. Mosby Co. 1985. 6th edition.
- [18] Fields HW. Treatment of non skeletal problems in Preadolescent children. In:Proffit WR, Fields HW, Sarver DM. *Contemporary Orthodontics.* 4th ed. St Louis, Mosby; 2006:433-94.
- [19] Sidney Finn. *Clinical pedodontics.* 2nd edition. 1958.
- [20] Hitchcock H.F. Preventive Orthodontics. In Finn S.B, edited: *Clinical Pedodontics*, 4th edition,W.B. Saunders Company, p.342-69,1973.
- [21] Thurow Raymond C. *Atlas of Orthodontic principles.* C.V. Mosby Company, p.194-197,1970.

- [22] Hinrichsen C.F.L. Space Maintenance in Pedodontics. *Australian Dent J.* 1962;7:451-456. In Year Book of Dentistry, p.169-173, 1963-64.
- [23] R.J Andlaw. A manual of Pediatric dentistry. 4th edition. Churchill living stone. 1995
- [24] Lin W-S, Chou J-C, Metz MJ, Harris BT, Morton D. Use of intraoral digital scanning for a CAD/CAM-fabricated milled bar and superstructure framework for an implant-supported, removable complete dental prosthesis. *J Prosthet Dent* 113(6):509-515, 2015.
- [25] Maekawa M, Kanno Z, Wada T, et al. Mechanical properties of orthodontic wires made of super engineering plastic. *Dent Mater J.* 2015;34(1):114–119.
- [26] Ierardo G, Luzzi V, Lesti M, et al. PEEK polymer in orthodontics: a pilot study on children. *J Clin Exp Dent.* 2017;9(10):e1271–e1275.
- [27] Kun J, Dinggui Z, Wei L, et al. Clinical application of digital space maintainer fabricated by polyetherketoneketone for premature loss of deciduous teeth [J/CD]. *Chin J Stomatol.* 2019;13:368–372.
- [28] Guo H, Wang Y, Zhao Y, et al. Computer-aided design of polyetheretherketone for application to removable pediatric space maintainers. *BMC Oral Health.* 2020;20(1)
- [29] What is BruxZir Solid Zirconia? View Technical Information. [Internet]. *BruxZir.* 2021.
- [30] Beretta M, Cirulli N. Metal free space maintainer for special needs patients. *Adv Dentis Oral Health.* 2017;6(2)
- [31] Fasbinder DJ. The CEREC system: 25 years of chairside CAD/CAM dentistry. *J Am Dent Assoc.* 2010;141
- [32] Beuer F, Schweiger J, Edelhofer FD. Digital dentistry; an overview of recent developments for CAD/CAM generated restorations. *Br Dent J.* 2008;204(9):505–511.
- [33] Pawar B. Maintenance of space by innovative three-dimensional-printed band and loop space maintainer. *J Indian Soc Pedod Prevent Dentis.* 2019;37(2):205.
- [34] Soni HK. Application of CAD-CAM for fabrication of metal-free band and loop space maintainer. *J Clin Diagn Res.* 2017;11(2):ZD14–ZD16.