

# ORAL BIOPSY: AN IRREPLACEABLE DIAGNOSTIC TOOL

## Abstract

A clinician frequently encounters oral mucosal lesions. Many of these lesions can be diagnosed simply on the patient's medical history and physical evaluation, but for some, histological examinations are required to confirm the presumptive clinical diagnosis, in which case an oral biopsy procedure is unavoidable. A good biopsy procedure performed decides the histopathological interpretation of a lesion. This article aims to shed some light upon Oral biopsy as an efficient diagnostic tool, the various techniques involved and some potential difficulties encountered.

**Keywords:** Oral lesions, Biopsy procedure, diagnostic tool,

## Authors

### **Anjali Ravi**

Student  
Clinical Dentistry and Comprehensive Care  
Rutgers School of Dental Medicine  
Newark, New jersey

### **Prasanna Kumar Rao**

Professor  
Oral Medicine & Radiology  
A. J Institute of Dental Sciences  
Kuntikana, Mangaluru, India  
drjpkrao@gmail.com

### **Priyanka Shetty**

Assistant Professor  
Oral Pathology and Microbiology  
A. J Institute of Dental Sciences  
Kuntikana, Mangalore, India  
drpshetty77@gmail.com

### **Priyal . G**

Assistant Professor  
Oral Pathology and Microbiology  
A.J Institute of Dental Sciences  
Kuntikana, Mangalore, India  
dr.priyalrohan@gmail.com

## I. INTRODUCTION

Biopsy means “vision of life”. The Greek terms bios(life) and opsy(vision of life) together constitute the term biopsy [1] In 1879, Ernest Besnier coined the term biopsy. [2, 3] The process of obtaining a tissue sample from the living body for examination under a microscope is defined as a biopsy. A biopsy is performed for diagnostic purposes. [4] Biopsy has four major goals. The first is to identify a lesion and make a certain diagnosis as soon as possible so that the right course of action can be determined without delay. The second goal is to assess the prognosis of the lesion. Thirdly, to ascertain whether the lesion was entirely eliminated, and fourthly, to serve as a medical-legal record. [1, 4] Oral biopsies are helpful in both detecting cancers and identifying the many types of oral lesions. [5, 6] Immediate diagnosis of an oral lesion is mandatory for appropriate treatment planning and establishing a prognosis. Thus, the cornerstone of obtaining an early diagnosis is a well-organized biopsy procedure. [4] Detailed history taking followed by a robust clinical examination result in a proper biopsy technique [7, 8, 9]

## II. INDICATION AND CONTRAINDICATIONS OF BIOPSY

The majority of lesions are diagnosed solely on the basis of microscopic analysis. [2] Biopsy is used for all bodily tissues, including the oral cavity where a range of diseases is manifested. [10] Any tissue sample obtained from the oral and maxillofacial region should be handed over to an oral and maxillofacial pathologist, as per the American Academy of Oral and Maxillofacial pathology.[2]

1. Any lesion suspected as neoplasm, with characteristic features such as an expanding mass, persistent ulceration, tissue that is indurated and friable on palpation, or unusual chronic mucosal changes. [11, 12, 13]
2. New, enlarging homogeneously pigmented lesions with irregular border.[ 10]
3. Idiopathic lesions accompanied by pain, anesthesia, and paresthesia.[1]
4. Inflammatory lesions that are still unresponsive to treatment 2 weeks later. [1]
5. Autoimmune disease which presents with widespread mucosal erythema and ulceration.[10]
6. Bony lesions accompanied by pain and altered sensations that is radiographically undiagnosed.[6]

Although there are no absolute contraindications for performing a biopsy, there are a few instances where the decision to proceed with a biopsy is crucial.[2]:

1. A vascular lesion: Significant hemorrhage may occur post-biopsy. Therefore extra caution must be adopted while performing a biopsy of any lesions that is red, blue, or purple in color.[10]
2. Location of lesion: Although the vermilion border of the lip is an esthetic region they are not strict contraindications but require referral to a specialist. It might be difficult to achieve hemostasis at some oral sites such as the floor of the mouth and has the potential to harm adjacent anatomic structures.[10]
3. Risk of osteoradionecrosis in a patient undergoing radiotherapy or bisphosphonate therapy if the bone is exposed.[14]

4. Multiple neurofibromatoses owing to the probability of neurosacromatous transformation.[6]
5. Poor general condition of the patient: Patients with uncontrolled systemic diseases and immunocompromised individuals require modification in the standard biopsy procedures. Such patients also require consulting the general physician before performing a biopsy.[1,10]
6. Clinically normal tissue, carious teeth devoid of attached keratinized tissue, and exostosis.[2]

### III. GENERAL GUIDELINES FOR ORAL BIOPSY

A biopsy is a preferred method of sampling diseased tissue in order to diagnose lesions of uncertain significance or etiology. Cautious handling of the tissue and pertinent fixation of the same is important. [2]Certain guidelines are expected to be followed during a biopsy procedure. [Table 1]

<b>Table 1: General Guidelines For Oral Biopsy</b>
<ul style="list-style-type: none"><li>• Consent</li><li>• Significance Of History Taking And Clinical Evaluation</li><li>• Local Anesthesia</li><li>• Selection Of Tissue Sample</li><li>• Size And Depth Of The Tissue</li><li>• Preparation Of Surgical Field</li><li>• The Biopsy Techniques</li><li>• Handling Of Specimen</li><li>• Hemostasis</li><li>• Submission Of The Biopsy Specimen.</li></ul>

- 1. Patient consent:** Prior to performing any biopsy, verbal and written informed consent is required. The patient should be informed of the specifics of the procedure and any potential problems or complications. The patient needs to be made aware of the possibility of recurrence of reactive lesions and that further excision may be necessary.[10]

2. **Significance of history taking and clinical evaluation:** In a biopsy procedure, the part of history taking and clinical examination cannot be underestimated. These represent the initial phase of a diagnostic biopsy. Collecting information regarding previous surgical experience and hospital admissions, the current medication, and habits like smoking and alcohol consumption are essential for an accurate diagnosis of a lesion. Past surgical history reveals the recurrent nature of the lesion. It is mandatory to obtain a drug history as medications affect the oral mucosa drastically. A thorough clinical examination involves visual and tactile palpation of the oral cavity. It is important to note down the lesion's color, consistency, size, and site of the lesion. Recording the systemic history is also required. All the above information documented should be sent to the pathologist along with the specimen to diagnose the lesion immediately. [5, 7]
  
3. **Local anaesthesia:** Injecting local anesthetic solution into the lesional tissue to be sampled results in distortion of the specimen. Regional block local anesthesia rather than infiltration with local anesthesia is preferred. A needle insertion at the biopsy site should be avoided as it can produce bleeding which can mask the normal cell architecture. [5,15]
  
4. **Selection of tissue sample:** A biopsy sample that does not represent the lesion is undiagnostic and will necessitate repeating the biopsy procedure. Thus, the meticulous selection of the tissue sample is the most important and first step toward the biopsy procedure. Representative sites including full epithelial thickness with supporting connective tissue are recommended in carcinomas and invasive carcinoma cases. [10] Necrotic tissues have no diagnostic values thus the middle area of large tumors should not be sampled. [5, 16] Erosive areas of mucocutaneous lesions such as lichen planus show inflammatory changes and it will not confirm the diagnosis. Therefore, obtaining a sample from a non- erosive lesional area should be appropriate for the diagnosis of lichen planus. [17] The most appropriate site to take a biopsy for vesiculobullous lesions is adjacent to the bulla where the epithelium is still intact. [4,18] Labial salivary gland biopsy on the lower lip is indicated for the diagnosis of Sjogren's syndrome. [6, 7, 19] The blockage and rupture of minor salivary gland ducts result in the formation of mucoceles. So excisional biopsy along with the feeder minor salivary gland is preferred.[7] Biopsy is avoided in the major salivary gland. Parotid gland biopsy often leads to scarring due to its increased vascularity. In addition, the preservation of facial nerves will be difficult. For diagnosis of Oral candidiasis oral rinses, smears and swabs are the preferred specimens. Biopsy specimens are usually preferred in case of chronic hyperplastic candidiasis [Table 2]. [20, 21] If suspicious lumps are clinically detected, a fine needle aspiration biopsy is indicated. [6]

<b>Table 2: Selection Of Tissue Sample</b>	
Red or white epithelial lesion	full epithelial thickness with some supporting connective tissue
Lichen planus	non- erosive lesional area
Vesiculobullous lesion	adjacent the bulla where the epithelium is intact
Sjogren's syndrome	Lower lip labial salivary gland biopsy
Mucoceles	Excisional biopsy along with the feeder

	minor salivary gland
Oral candidiasis	oral rinses, smears and swabs are the preferred specimens

5. **Size and depth of the tissue:** There are no specific criteria for size, but small-sized samples pose a difficulty in processing and interpretation. An insufficient sample is undiagnostic. Additionally, shrinkage that takes place during fixation results in an even smaller-sized tissue sample. The tissue sample for biopsy should be of adequate depth. [5,22,23].
6. **Surgical field preparation:** A quaternary ammonium compound is used to disinfect the surgical area. Antiseptics containing iodine stain the tissues thus not preferred. The accepted antiseptics is a 0.12- 0.20 % chlorhexidine solution. [24]
7. **The biopsy techniques:** The final diagnosis relies on the quantity and nature of the tissue specimen obtained. Biopsy techniques are classified on the basis of location, size, and other features.[Table 3& 4]

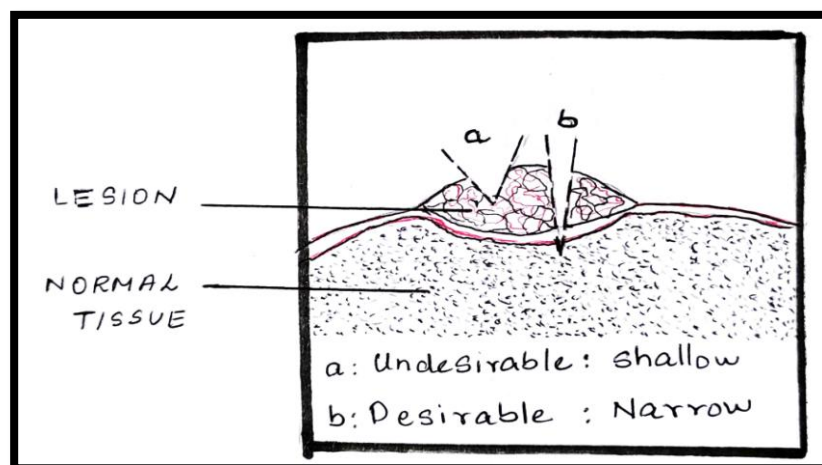
Characteristic	Classification
1. Characteristics of the target lesion	<ul style="list-style-type: none"> <li>• Direct (superficially located)</li> <li>• Indirect (Deeply located lesion with overlying normal mucosa or tissue)</li> </ul>
2. Techniques used	<ul style="list-style-type: none"> <li>• Incisional biopsy</li> <li>• Excisional biopsy</li> </ul>
3. Material employed	<ul style="list-style-type: none"> <li>• A conventional scalpel</li> <li>• A punch</li> <li>• Electro scalpels</li> <li>• CO2 Laser</li> </ul>
4. Processing of the sample	<ul style="list-style-type: none"> <li>• Paraffin-embedded</li> <li>• Analyzed frozen</li> <li>• Embedding in methacrylate</li> </ul>
5. Location of the target lesion.	<ul style="list-style-type: none"> <li>• salivary gland</li> <li>• Bone</li> <li>• Lymph nodes</li> <li>• Other head and neck tissues</li> </ul>
6. Time of the biopsy performed	<ul style="list-style-type: none"> <li>• Pre-operative</li> <li>• Intra-operative</li> <li>• Post-operative</li> </ul>
7. Purpose of the biopsy	<ul style="list-style-type: none"> <li>• Diagnostic</li> <li>• Experimental</li> </ul>

Excisional	Complete removal of the tissue with surrounding normal tissue so that it can be examined. Indicated in small lesions.
Incisional	Excision of a portion of the lesion for the purpose of diagnosing. Indicated in a large lesion.

Punch	Removal of a cylinder of the lesional tissue using a disposable instrument designed for this purpose
Brush	Uses an entire transepithelial biopsy specimen that includes cells from all three layers of the lesion.
Exfoliative cytology	Obtaining a sample of cells using a cytobrush for microscopic examination.
Fine needle aspiration	Involves inserting a thin gauge needle (22 - 26 G) into the mass and through the skin to obtain a sample. The sample is then prepared into thin smears on glass slides

#### Different biopsy techniques

- Incisional biopsy:** An Incisional biopsy is a type of biopsy that samples only a specific area of a lesion. It is of use when the lesion is large to be excised. [6]. Incisional biopsy does not allow evaluation of the whole lesion. [4]. If the lesion is large it is advised to take multiple samples and place each one in its own container with clear identification. [6] A sample should be obtained from the most significant affected area of the lesion. [4,6,25]
- Technique:** Using a 15-scalpel blade with a length-to-width ratio of 3:1, an elliptical incision is produced. The elliptical incision enables healing with primary intention. First, the inferior incision is made to prevent bleeding from obstructing the operative field. With tissue forceps, the anterior portion of the ellipse is gently lifted, and the base is cut off. A part of the neighboring intact epithelium should be included in the specimen if the lesion is ulcerated. [10] [FIGURE 1]



**Figure 1**

#### Advantages

- Small fragment of tissue is obtained. [11,25]
- Preferred method when malignancy is included in the differential diagnosis. [10]

#### Disadvantages

- Avoid performing an incisional biopsy of vascular lesions due to the risk of bleeding. [14]
- Increases the risk of metastasis of malignant lesions. [26]
- **Excisional biopsy :** An excisional biopsy entails completely removing the lesion in order to confirm the clinical diagnosis and for functional and cosmetic reasons. Only if the lesion is nearly certainly benign, this method is appropriate. It is necessary to take into consideration the lesion's size, accessibility, and regional anatomy. [7, 10]
- **Technique:** With the blade oriented toward the lesion's center, an ellipse is drawn around the affected area. This causes a wound that is convenient to close and creates a wedge-shaped sample that is deepest under the core of the lesion. [FIGURE 2]




Figure 2

**Advantages:**

- ✓ Removal of the whole lesion. [10,27]
- ✓ Preferred biopsy method for less enlarged peripheral benign lesions. [4,28]

**Disadvantages:**

- ✓ Contraindicated for large lesions.[10]
- ✓ Not performed in cases of suspected malignancy.[14]
- **Punch biopsy:** A full-thickness and diagnostic skin sample are conveniently obtained with a punch biopsy. For minor lesions at an accessible site, a punch biopsy is preferred over incisional or excisional biopsies. A punch biopsy is suitable for lesions at the lateral tongue and buccal mucosa, as it allows the device to approach these sites perpendicularly. [10]

- **Technique:** It is carried out with a circular blade or trephine affixed to a handle resembling a pencil. The lesion is touched with the device, which is rotated downward through the epidermis and dermis to reach the subcutaneous fat. The cylindrical core of tissue obtained from the punch biopsy must be treated carefully. Next, using a pair of curved scissors, the tissue core is cut off at the base. It is more difficult to approximate the borders of a circular wound compared to an elliptical lesion. [29] [FIGURE3]

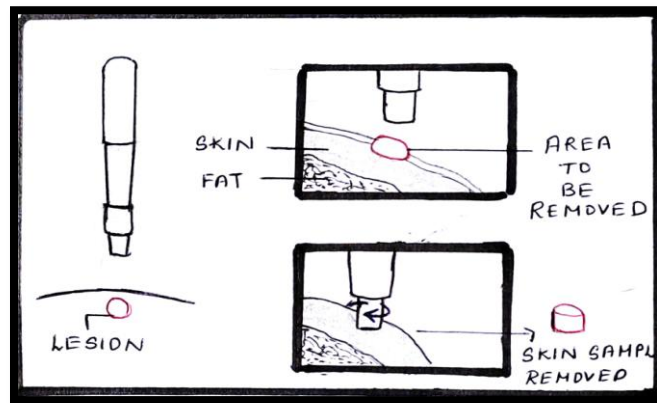


Figure 3

### Advantages

- Rapid, simple, safe, and inexpensive technique.
- Esthetic results which are attributed to better and fast wound healing.[6]
- Punch biopsy allows the collection of multiple samples from different sites simultaneously, generating less patient anxiety than scalpel biopsy.[30]

### Disadvantages

- The twisting motion can detach the epithelium and hinder the interpretation of the epithelium-connective tissue interface, thus punch biopsy is not indicated for the vesiculobullous disease. [10,30]
  - They cannot be performed on deep lesions and large lesions.[6]
  - Punch biopsy is not performed in vascular lesions.[31]
- **B- forceps:** Bermejo created this tool to aid in measuring the depth of the samples in order to enable better sectioning. Two cusps, one of which has a window to facilitate compression of the target tissue between them, are present on the forceps. As a result of the cusp's compressive impact and the target zone's exposed position within the window, we are able to work in an ischemic field. The sectioned component, free from its peripheral connective tissue attachments, propels out the window as a result of forceps compression. Good cosmetics outcomes as a result of quicker and better wound healing. [32]



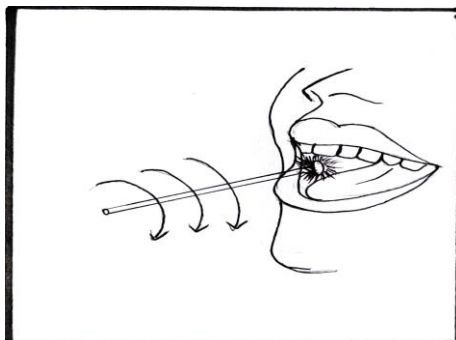
- **Frozen section biopsy:** Mainly used for diagnosis during intra-operative period. [31,33]
- **Technique:** During surgery, a part of the tissue mass is cut out in a frozen section procedure and immediately given to a pathologist. The tissue is cut with a microtome, frozen in a cryostat and then stained with various dyes so that it can be viewed under the microscope. This process typically takes few minutes. [34]

### Advantages

- The surgeon can take an extra sample if extra tissue is required to provide a precise diagnosis, preventing the need for a second procedure.[34]
- If the tissue obtained from frozen section biopsy is found to be malignant and indicated to be surgically removed, the mass can be removed at that time.[34]
- The pathologist and surgeon can work together to render adequate care to the patient. [34]

### Disadvantages

- In some cases, the final diagnosis may differ from the frozen section diagnosis.[35]
- **Brush biopsy:** It is a non-invasive technique to assess lesions on the oral mucosal. Originally brush biopsy was developed for cervical smears in gynecological lesions. Later modified for oral smears too. [36]
- **Technique:** This technique makes use of an upgraded brush biopsy instrument with two cutting surfaces: the brush's flat end and its circular border. The biopsy sample can be obtained from either surface. The brush biopsy method uses an entire transepithelial biopsy specimen that includes cells from all three layers of the lesion. [37] [FIGURE 4]



**Figure 4**

### Advantages

- The brush biopsy, as opposed to, exfoliative cytology, gathers cells from the entire thickness of the oral epithelium.
- Simple and convenient technique

### Disadvantages

- Significant false positive or false negative results. [31,33]
  - Cannot substitute scalpel biopsy. [31]
- **Fine needle aspiration biopsy [ FNA biopsy]:** This technique was first described by Kun in 1847. It is considered inferior to histologic examination, as the biological specimen collected does not represent the cellular details. The advantage of the fine needle aspirational biopsy technique is that it can obtain samples from numerous lesional sites.
  - **Technique:** In order to determine the depth of a mass, the region of interest is localized and palpated. This evaluation is crucial because fine needle aspiration may fail if the needle is inserted too deep or too superficially. This biopsy technique is painless, therefore local anesthetic is not necessary; nevertheless, this depends on the patient's tolerance for pain. In essence, aspiration biopsy entails inserting a fine-gauge needle (22-26 G) into the mass via the skin, collecting a sample, and then withdrawing the needle. The sample thus obtained is evenly smeared onto a glass slide. [39]

### Advantages

- Simple, accurate, fast and economic procedure.[40]
- The technique is relatively painless.[38]
- Reduced risk of complications.[38]
- It works well for multiple lesions, is easily reproducible, and technique of choice for debilitated patients.[38]

### Disadvantages

- Inadequate sampling and potential loss of cellular details renders the sample obtained poorly diagnostic.[41]

8. **Handling of Biopsy Specimen:** Biopsy specimens are vulnerable to artifacts. Most of the artifacts are due to improper handling of the specimen. [2] First and foremost the specimen should be grasped carefully with forceps. Blunt forceps are preferred over toothed forceps.[2] Orientation of the biopsy specimen is important as they are small in size and have limited morphological characteristics. It is accompanied by placing one/multiple sutures on the known margin. Ensure that the specimen and the suture both are described in writing. If the specimen is excessively thin, it must be laid flat during fixation for at least a minute by placing the connective tissue side down on a piece of paper. If more than one specimen is obtained, they must be clearly differentiated from one another either by putting them in separate containers or by attaching identifying sutures. [2,4,10,42,]. When tissue is removed from the patient, fixation prevents autolysis of the

tissue. To prevent inappropriate fixation, the biopsy sample must be immersed in 10% formalin which is at least 15 to 20 times the volume of the sample. By creating intermolecular bridges and cross-links between protein end groups, formalin fixes specimens [7, 42]

- 9. Submission of Biopsy Specimen:** It is recommended that the specimen is placed in a container with a wide opening to avoid rough handling. The specimen should always be sent out with certain information which includes patient details, the clinical presentation of the lesion, and relevant medical history. The specimen should be sent as soon as possible to avoid any sort of delay. [10]

#### **IV. VARIOUS PITFALLS AND ARTIFACTS ENCOUNTERED DURING ORAL BIOPSY**

The proper handling of the biopsy specimen removed from the oral cavity is inevitable. Since these biopsy samples are often small the chances of an artifact are high. Additionally, routine processing procedures distort cellular features. Other factors that can cause artifacts are mistakes made by the surgeon or an assistant while handling the tissue sample, and improper processing of the specimen. [15,43]

- 1. Forceps artifacts:** If a toothed forceps is used to hold the specimen it might result in the formation of voids/ tear/compression of the surrounding tissues. This results in the loss of cytological details with the loss of the nucleus. [45]
- 2. Injection artifacts:** Swelling of the tissue sample is caused by administering a large amount of anesthetic solution into the region to be sampled for biopsy. It may also result in excessive bleeding causing cellular distortion. There will be subepithelial separation due to vacuole formation. [6, 46]
- 3. Crush artifacts:** Even a slight compression of the biopsy sample can cause distortion of the tissue which is referred to as crush artifacts. It results from improper usage of tissue forceps and usage of scalpel blades that are dull. The artifact causes tissue distortion and forces the chromatin out. The use of non-toothed forceps while handling the specimen avoids a crushed artifact. [47].
- 4. Fulguration Artefacts:** Heat generated from a surgical electrical – cautery instrument or laser distorts the biopsy sample. This is called a Fulguration artifact or Heat artifact. The nuclei of epithelial cells take on a spindled, palisading form and the cells appear separated. Subepithelial separation was noticed. [47,48].
- 5. Fixation artifacts:** Excessive fixation in formalin results in tissue separation, secondary shrinkage, and hardening. The cellular features are disintegrated. [50]
- 6. Suction Artifacts:** It is induced by the vacuum effect of surgical suction tips. It displays tissue that is highly vascularized and has connective tissue vacuoles that resemble damaged adipose tissue.

#### **V. CONCLUSION**

Biopsy has been used for more than 150 years for establishing a diagnosis of various medical conditions. Biopsy is one of the oldest and most reliable methods currently available to obtain a definite diagnosis and remains the gold standard procedure. A biopsy performed with proper planning and appropriate technique has proved to have high diagnostic value. Thus, a dental practitioner must be well aware about the various techniques of biopsy and the expected pitfalls to be encountered and the methods to overcome the same.

## REFERENCES

- [1] Ali FM, Prasant MC, Patil A, Ahere V, Tahasildar S, Patil K, Deshpande R. Oral biopsy in general dental practice: a review. *International Journal of Medicine and Public Health*. 2012;2(1).
- [2] Kumaraswamy KL, Vidhya M, Rao PK, Mukunda A. Oral biopsy: Oral pathologist's perspective. *Journal of cancer research and therapeutics*. 2012 Apr 1;8(2):192.
- [3] Zerbino DD. Biopsy: its history, current and future outlook. *Likars' ka sprava*. 1994 Mar 1(3-4):1-9.
- [4] Rosebush MS, Mark Anderson K, Rawal SY, Mincer HH, Rawal YB. The oral biopsy: indications, techniques and special considerations. *Journal of the tennessee dental association*. 2010 Jan 1;90(2):17.
- [5] Masthan KM, Sankari SL, Babu NA, Rajguru JP. How to help the oral pathologist in making an accurate diagnosis. *Journal of clinical and diagnostic research: JCDR*. 2013 Jan;7(1):181.
- [6] Mota-Ramírez A, Silvestre FJ, Simó JM. Oral biopsy in dental practice. *Medicina Oral, Patología Oral y Cirugía Bucal* (Internet). 2007 Nov;12(7):504-10.
- [7] Oliver RJ, Sloan P, Pemberton MN. Oral biopsies: methods and applications. *British Dental Journal*. 2004 Mar;196(6):329-33.
- [8] Parkin DM, Bray F, Ferlay J, Pisani P. Global cancer statistics, 2002. *CA: a cancer journal for clinicians*. 2005 Mar;55(2):74-108.
- [9] Sciubba JJ. Oral cancer. *American journal of clinical dermatology*. 2001 Aug;2(4):239-51.
- [10] Sylvie-Louise Avon DM, Klieb H. Oral soft-tissue biopsy: an overview. *J Can Dent Assoc*. 2012;78:c75.
- [11] Mashberg A, Samit A. Early diagnosis of asymptomatic oral and oropharyngeal squamous cancers. *CA: a cancer journal for clinicians*. 1995 Nov;45(6):328-51.
- [12] Driemel O, Kunkel M, Hullmann M, Eggeling FV, Müller- Richter U, Kosmehl H, Reichert TE. Diagnosis of oral squamous cell carcinoma and its precursor lesions. *JDDG: Journal der Deutschen Dermatologischen Gesellschaft*. 2007 Dec;5(12):1095-100.
- [13] Rawat M, Saxena S, Sireesha SK. A Comparative Study of Diode Laser and Conventional (Scalpel) Technique for Biopsy of Soft Tissue Oral Lesions.
- [14] Shklar G. The effect of manipulation and incision on experimental carcinoma of hamster buccal pouch. *Cancer research*. 1968 Nov 1;28(11):2180-2.
- [15] Margarone JE, Natiella JR, Vaughan CD. Artifacts in oral biopsy specimens. *Journal of oral and maxillofacial surgery*. 1985 Mar 1;43(3):163-72.
- [16] Khoo SP. Oral biopsy in dental practice-The pathologist's perspective. *Annals of Dentistry University of Malaya*. 1995 Dec 29;2(1):29-32.
- [17] Canto AM, Müller H, Freitas RR, Santos PS. Oral lichen planus (OLP): clinical and complementary diagnosis. *Anais brasileiros de dermatologia*. 2010 Oct;85(5):669-75.
- [18] Arisawa EA, Almeida JD, Carvalho YR, Cabral LA. Clinicopathological analysis of oral mucous autoimmune disease: A 27-year study.

- [19] Stewart CM, Bhattacharyya I, Berg K, Cohen DM, Orlando C, Drew P, Islam NM, Ojha J, Reeves W. Labial salivary gland biopsies in Sjögren's syndrome: still the gold standard?. *Oral Surgery, Oral Medicine, Oral Pathology, Oral Radiology, and Endodontology*. 2008 Sep 1;106(3):392-402.
- [20] Olsen I, Stenderup A. Clinical-mycologic diagnosis of oral yeast infections. *Acta Odontologica Scandinavica*. 1990 Jan 1;48(1):11-8.
- [21] Silverman Jr S, Migliorati CA, Epstein JB, Samaranayake LP. Laboratory diagnosis of oral candidosis. *Laboratory diagnosis of oral candidosis*. 1990:213-37.
- [22] Ficarra G, McClintock B, Hansen LS. Artefacts created during oral biopsy procedures. *Journal of Cranio-Maxillofacial Surgery*. 1987 Jan 1;15:34-7.
- [23] Meghana SM, Ahmedmujib BR. Surgical artefacts in oral biopsy specimens: Punch biopsy compared to conventional scalpel biopsy. *Journal of Oral and Maxillofacial Pathology*. 2007 Jan 1;11(1):11.
- [24] McAndrew PG. Oral cancer biopsy in general practice. *British dental journal*. 1998 Nov 14;185(9):428.
- [25] Poh CF, Samson Ng, Berean KW, Williams PM, Rosin MP, Zhang L. Biopsy and histopathologic diagnosis of oral premalignant and malignant lesions. *J Can Dent Assoc*. 2008;74(3):283-8.
- [26] Shyamala K, Girish HC, Murgod S. Risk of tumor cell seeding through biopsy and aspiration cytology. *Journal of International Society of Preventive & Community Dentistry*. 2014 Jan;4(1):5.
- [27] Khajuria N, Anjum R. Attitude and Practices of General Dental Practitioners Towards Oral Biopsy. *Int J Res Health Allied Sci*. 2019;5(1):10-2.
- [28] Mehrotra R, Gupta DK. Exciting new advances in oral cancer diagnosis: avenues to early detection. *Head & neck oncology*. 2011 Dec;3(1):1-9.
- [29] Zuber TJ. Punch biopsy of the skin. *American family physician*. 2002 Mar 15;65(6):1155.
- [30] Eisen D. The oral mucosal punch biopsy: a report of 140 cases. *Archives of dermatology*. 1992 Jun 1;128(6):815-7.
- [31] Hershita Singh, Shalini, Nancy charaya, Monika Poonia, Supreet Kaur Sidhu, Sandeep Singh Sihmar, Monika. Biopsy- A vision of life. *International Journal of Contemporary Medical Research* 2016;3(6):1734-1737.
- [32] Bermejo-Fenoll A, Lopez-Jornet P. Instrument for biopsy of oral lesions: an improved chalazion forceps. *Dermatologic surgery*. 2006 Dec 1;32(12):1493-5.
- [33] Hall DL. Oral brush biopsy technique instruction outcomes for senior dental students. *Journal of dental education*. 2006 Aug;70(8):820-4.
- [34] Brender E, Burke A, Glass RM. Frozen section biopsy. *Jama*. 2005 Dec 28;294(24):3200-.
- [35] MacLeod CB, Branton P, Bruzzi C, Dow N, Katz R, Martin E. Addressing: Molecular testing for indeterminate thyroid FNA biopsy.
- [36] Sciubba JJ, US Collaborative OralCDx Study Group. Improving detection of precancerous and cancerous oral lesions: computer-assisted analysis of the oral brush biopsy. *The Journal of the American Dental Association*. 1999 Oct 1;130(10):1445-57.
- [37] Ehtisham M, Nissar S. Oral brush biopsy: Pros and Cons. *Heal talk*. 2015;8(2):29-30.
- [38] Jacob A, Zazgyva A, Ormenişan A, Mezei T, Sin A, Tulinca M. Effectiveness of fine-needle aspiration cytology in the diagnosis of lateral cervical nonthyroid tumors. *Medicine*. 2016 Aug;95(31).
- [39] Weydert JA, Cohen MB. Fine needle aspiration: current practice and recent developments. *Laboratory Medicine*. 2003 Dec 1;34(12):851-4.
- [40] Grohs HK. Starting Out: The Interventional Cytopathologist: A New Clinician/Pathologist Hybrid. *American journal of clinical pathology*. 1988 Sep 1;90(3):351-4.
- [41] Martin HE, Ellis EB. Biopsy by needle puncture and aspiration. *Annals of surgery*. 1930 Aug;92(2):169.
- [42] Melrose RJ, Handlers JP, Kerpel S, Summerlin DJ, Tomich CJ. The use of biopsy in dental practice. The position of the American Academy of Oral and Maxillofacial Pathology. *General dentistry*. 2007 Sep 1;55(5):457-61.

- [43] Bancroft JD, Gamble M, editors. Theory and practice of histological techniques. Elsevier health sciences; 2008.
- [44] Zegarelli DJ. Common problems in biopsy procedure. Journal of Oral Surgery (American Dental Association: 1965). 1978 Aug 1;36(8):644-7.
- [45] Rastogi V, Puri N, Arora S, Kaur G, Yadav L, Sharma R. Artefacts: a diagnostic dilemma—a review. Journal of clinical and diagnostic research: JCDR. 2013 Oct;7(10):2408.
- [46] Takahashi K, Iwase S. On artifacts appearing in the histochemical fixation of glycogen. The Journal of Cell Biology. 1955 Sep 25;1(5):391-8.
- [47] Chatterjee S. Artefacts in histopathology. Journal of oral and maxillofacial pathology: JOMFP. 2014 Sep;18(Suppl 1):S111.
- [48] Krishnanand PS, Kamath VV, Nagaraja A, Badni M. Artefacts in oral mucosal biopsies—A review. Journal of Orofacial Sciences. 2010 Jan 1;2(1):57.