

ARTIFICIAL SKIN- A SKIN SUBSTITUTE

Pavan kumar Krosuri*¹, G. Tejaswini¹, D. Karishma Banu¹, P. Bhavya sree¹, K. Kiranmai¹.

1. Department of Pharmaceutics, Santhiram college of pharmacy, Nandyal, Andhrapradesh, India.

Corresponding author mail: pavankumarmph@gmail.com

Abstract:

According to gift approaches, the focus on changed skin is regenerative medicine, including burned skin, which can be transplanted utilising a constructs and biomolecules. Extracellular matrix is currently being employed with biologically active scaffolds, which may promote the development various organs and tissues. Scaffold is crucial as the recovery with tissue function both its regeneration, as it serves as a temporary a matrix for cell growth and the deposition of matrix extracellular. In a variety of fields, such as artificial intelligence, human-computer interfaces, and other fields, scaffolds are used for tissue engineering, including the creation of cartilage and bone, ligaments, cutaneous, vascular, neuronal, and muscular tissues. They are also used as a means of delivering drugs, proteins, and DNA covering. This essay gives an overview of the human body's the skin, types with burns, scaffolding used to cover wounds, properties of the material used to cure burn scars, and its application.

KEY WORDS: cuticle freeze drying, grafting, death tissue scaffold, collagen, and ECM.

Introduction

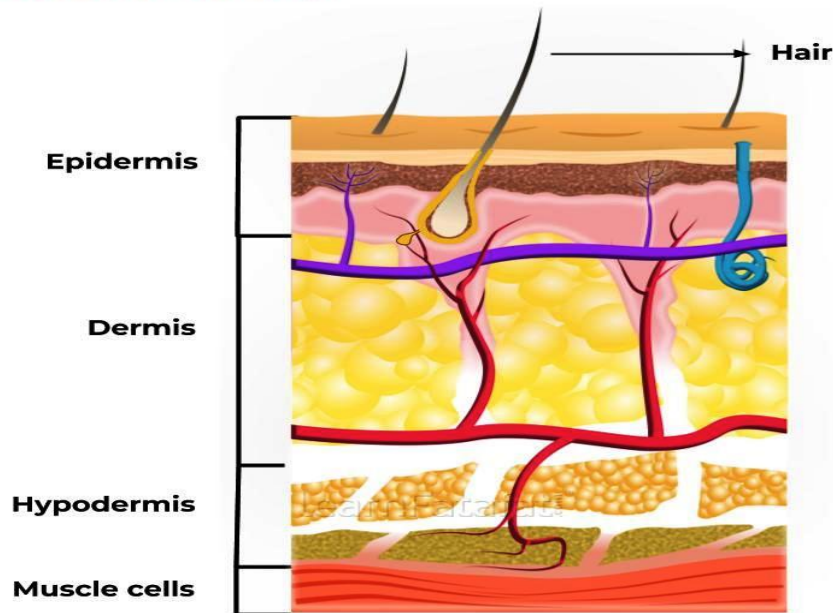
The largest organ in the body is the skin. The cuticle, dermis, and fat layer make up the skin., which are referred to as the layer as a whole. The cuticle is the top layer of skin., protects the body from harmful microorganisms. The dermis, the skin's deepest layer, contains blood vessels, nerves, hair follicles, oil glands, and sweat glands.. Massive skin wounds expose the body to potentially lethal infections and dehydration.

The conventional treatments for healing substantial skin losses include skin grafts from the patient (autografts), an unrelated donor, or a corpse. The first method's drawback is the second procedure increases the risk of infection or rejection, whereas the first method suggests that there might not be enough skin available. The patient's own skin was used to generate skin grafts prior to the 20th century. Once the skin had sustained significant damage, this became a concern, making it hard to fully treat patients with severely injured skin using autografts.

Skin covers the outside of the human body. The human body's most important organ is this one. The skin protects the underlying muscles, bones, ligaments, and internal organs with up to seven layers of ectodermic tissue. The bulk of other animals' pig skin and skin are similar to human skin in certain ways. Despite the fact that The majority of hair follicles on human skin make it appear depilatory. Bushy skin and hairless skin are the two most common forms of skin. The Latin word for skin, cutaneous, literally translates to "of the skin" in English. Skin has a crucial immunological role in the body's defense against infections and excessive water loss because it interacts with the environment. Insulation, temperature control, feeling, cholecalciferol production, and vitamin B folate protection are just a few of its numerous activities. Skin that has sustained significant injury

may attempt to repair itself by producing connective tissue. Frequently, this is discoloured and depigmented. Human skin comes in a variety of colours and textures, from dry to greasy, depending on the population. The almost On human skin, 1000 types of bacteria from 19 phyla exist. benefit from the rich and diverse environments provided by these various skin types.

Structure of skin



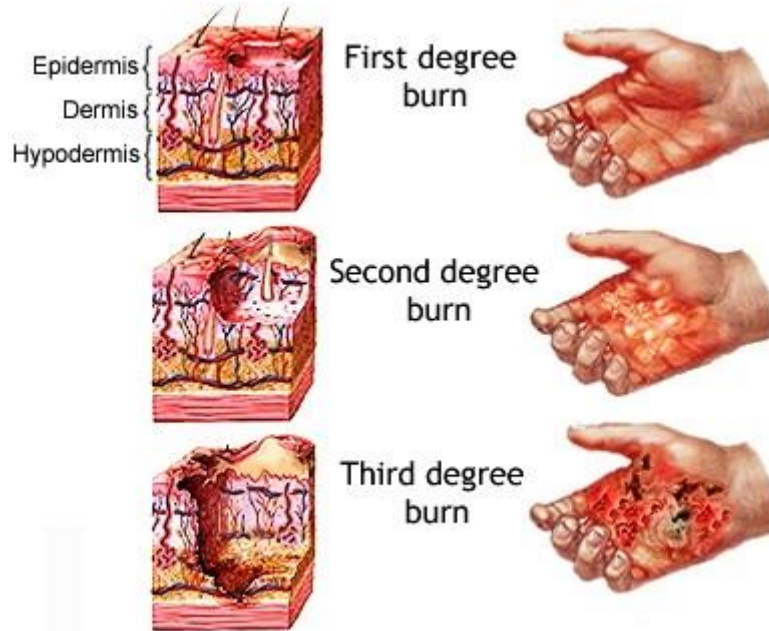
The skin performs crucial roles in maintaining the body's optimal levels of physiology and organic chemistry. The skin's primary requirements include:

1. Controls blood heat.
2. Prevents nephrotoxic chemicals from penetrating and the loss of vital body fluids.
3. Defence against the damaging effects of radiation and the sun.
4. Sweats out nephrotoxic chemicals.
5. Mechanical assistance.
6. immune system function mediated by Langerhans cells.
7. Organ of perception for touch, cold, heat, sociosexual, and emotional feelings.
8. The synthesis of cholecalciferol from its precursors when steroid introversion and light are present.

Burns

Burns are among the most frequent injuries at home, particularly for kids. The word "burn" describes the burning sensation that is associated with this harm. A burn is characterized by a serious skin damage that results in the death of the impacted skin cells. Depending on where the harm came from and how bad it was, the majority of persons who suffer burns will recover without suffering any serious health consequences. In order to prevent complications and death, more severe burns require immediate emergency care.

Pictures of burns



Burn levels

Burns come in three main categories: first-, second-, and third-degree. The intensity of the skin injury determines each degree, whereas third-degree injuries are the most severe and first-degree injuries are the most minor serious. injury consists of:

1. Burns of the first degree red skin that isn't scorching
2. Blisters are present in second-degree burns , some thinning of the skin.
3. Burns of the third degree are thick and seem white and leathery. Then there are burns of the fourth class. A burn of this nature encompasses all burn signs and also penetrates tendons and bones beyond the skin's surface.

Burns can be caused by a variety of things, such as hot, boiling liquids, chemicals, electricity, fires, and flames from candles, lighters, and matches, too much using the sun.

The justification for it does not support the type of burn. For instance, Depending on the temperature and duration of the liquid remains when in proximity to the skin, scaling can result in all three burns. Whether or not the skin injury is mild, chemical and electrical burns require rapid medical attention since they will affect the body's internal organs.

First-degree burn

Burns of the first degree only slightly harm the skin. Those are additionally referred to as "superficial burns" since they only have an impact on the epidermis. Burn symptoms include:

- Pain; mild swelling, inflammation, or redness
- The skin becomes dry and peels while the burn heals.

The signs and symptoms of severe burn, which damages the epidermis of the skin, go away after skin cells exfoliate. Burned first-degree normally recover without in seven to ten days leaving any scars.

Despite the burn, you should still visit a doctor. involves a significant joint, such as your knee, ankle, foot, spine, shoulder, elbow, or forearm, or if it covers a substantial region of skin, such as 3 inches.

Usually, home care is used to treat burns of the first degree.

The following should be done to treat a burn: Apply Xylocaine (an anaesthetic) with aloe gel or cream to calm the skin; wash the wound in cool water for at least five minutes; take Panadol or Nuprin Use an antibiotic for pain relief cream Use loose gauze to cover the area that is afflicted.

Second-degree burn:

Second-degree burns are more severe because the harm extends deeper than the epidermis. deadly. The skin will scab over, turn incredibly red The burn is visible wet, and hurt from this kind of burn or weeping when some blisters rupture. Protein exudate, a thick, mushy substance that looks like a scab, might develop more than incision over time.

Because those wounds are so delicate, keeping the wound clean and correctly bound is essential to preventing a disease. This contributes to the healing of the flames.

The majority of second-degree burns heal within three weeks, however some recover in 2 to a few weeks without any scars but with pigment changes to the skin.

Third-degree burn

Aside from The most severe burns are those of the fourth and third degrees. dangerous. It is they who first to cause harm, penetrating all of the skin's layers.

The most painful burns are said to be third-degree burns. However, due to nerve damage from such a severe burn, there might not be any discomfort.

Third-degree burns will exhibit the following symptoms, depending on the cause:

- White and waxy appearance
- char
- colour: dark brown
- textured elevated and leathery
- Bruises that don't heal form

These wounds won't heal without surgery close up with significant muscle stiffness and scarring. Full spontaneous recovery of fourth-degree burns cannot be predicted.

Never try to treat a burn yourself; instead, elevate the wound just before you whilst await medical assistance. But Don't remove your clothing.

Compared to first- and second-degree burns, third-degree burns carry a higher risk of complications, including shock, blood loss, and infections, all of which could be fatal. Additionally, since bacteria can infiltrate skin that has been broken, all burns should be treated immediately have a danger of contamination.

When treated appropriately and promptly, first- and second-degree burns have a good prognosis. These burns rarely scar, although they can cause a change in the colour of the injured skin. The key is to minimise any harm and illness. Burns of the second and third degrees will be very severe extensive damage to internal organs, bones, and skin tissues.

Surgery includes the use of skin grafts, which are used to cover burnt skin in situ.

- The coating could be a scleroprotein scaffold that promotes skin renewal in mammals such as humans.

Burns will impact deep skin tissues, bones, and organs. The was utilized to describe an in the late 1970s and early 1980s. revolutionary therapy for severe burns. In the future shown that using this scaffold to heal thick skin lesions and in mature animals people stimulates derma regeneration .It has been commercially produced beneath the brand Integra™ is employed in severely burn victims while aesthetic skin grafting, and in the management of persistent skinwounds.

- Instead, the phrase "artificial skin" means commonly is a term for tissue that resembles skin generated in an experiment, Even now, this technology is far from suitable for use in medicine industry. 'Man-made skin'



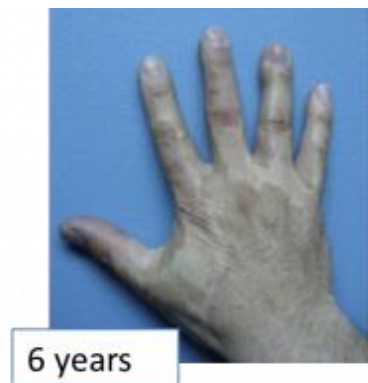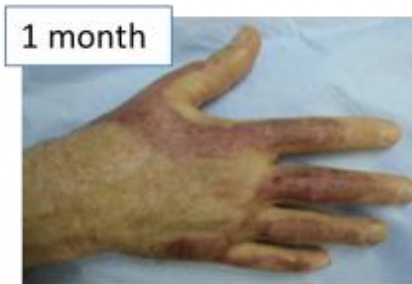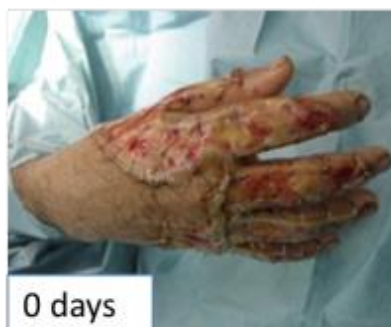Artificial skin is commonly used for burn sufferers and other skin-related illnesses, and it is not utilised as a permanent replacement, but rather to conceal until normal skin regeneration occurs.

AREAS OF APPLICATION:

Particularly for skin loss or injury on burn patients, artificial skins are employed.

Treatment of individuals with skin conditions including diabetic foot ulcers and extensive scarring is one application for artificial skin.

Plastic surgery and cosmetics.



The body is unable to produce the necessary replacement cells in time the skin is when severely damaged by illness or burns. If wounds, like the skin ulcers that diabetics frequently get, do not heal, limbs may need to be amputated. Infection and plasma loss are also potential causes of death for burn sufferers. Skin grafts were created as a means of preventing such effects from worsening

the defects they were intended to repair. Hindu surgeons were involved in nose beginning in the sixth century B.C., grafting skin flaps from the nose of the patient. The method was in the case of Western medicine sixteenth a. by an Italian physician named Gaspare Tagliacozzo.

Skin transplants were traditionally made (autografts) from the patient's own skin or the skin of a deceased person (allografts) until the late 20th century. or, in the case of a corpse, infection.

The retrieved fibroblasts are placed on top of scleroprotein, a fibrous supermolecule present in animal tissue, in a version of this technique created by other researchers. Scleroprotein gels and traps the fibroblasts after the compound is heated; the fibroblasts then organise themselves centered on scleroprotein, becoming fibrous, thick, and compact. Keratinocytes are also taken using the provided foreskins and where they produce new skin tissue after being planted onto it. a dermal layer, once every few weeks.

Compared to skin from cadavers and patients, artificial skin has many advantages. It does away with the need for diagnostic tests.

For long-term use and transportation, artificial skin can be created in enormous numbers and frozen. Each society is examined as a pathogen, greatly lowering the possibility of contamination. due to synthetic skin lacks inflammatory cells like It is not rejected by the body despite including capillary endothelial cells and dendritic cells. Finally, the duration of therapy is drastically cut down.

components for creating synthetic skin:

The biological elements, as well as the appropriate laboratory apparatus are two types of the raw materials needed to assemble the covering. The majority of the skin tissue donated originates from infant foreskins that are removed during circumcision. Four acres of graft material may be created from one foreskin's worth of cells. the skin's dermal layer selected tissue is separated from the fibrocytes. While being examined for viruses, other infectious pathogens like hepatitis B and C, and real bacteria, the fibroblasts are not fully integrated. The case history of the mother is documented. Glass vials containing the fibroblasts are kept in an atomic 7 freezer at -94°F (-70°C). before fibroblasts are required to develop the cultures vials are kept intact and frozen. Keratinocytes are also removed, examined, and frozen from the foreskin as part of the scleroprotein approach.

To create a chemical that will allow the fibroblasts to fully develop on the mesh system, molecules of carboxylic acid and hydroxyacetic acid are combined. These two acids are that same ones utilized to create removing stitches. The component goes through an elemental transformation that creates an expanded molecule with recurring structural components.

A little amount of bovine scleroprotein is isolated using the scleroprotein approach from the connective tissue of young calves' extensor muscles. At 39.2°F (4°C), It is the scleroprotein combined with an acidic food source and stored in a bright white substance.

Roller bottles, tubing, glass vials, and graft cartridges, moulds, plus freezers are examples of laboratory equipment.

Manufacturing Process:

The production procedure seems to be very straightforward. The primary goal of this substance is to deceive the removed fibroblasts into thinking they are still a part of the human body, allowing them to connect with one another in a healthy manner and produce fresh skin.

scaffolding made of mesh:

1. frozen and dilated fibroblasts: In the fibroblasts, moved within the vials onto Coke bottles known as roller bottles with a cubic decimeter capacity. between three and four weeks, the On their sides, bottles are turned. The expansion process requires the movement of O₂, which the rolling movement makes possible.

2. The transfer of cells to a culture system: A nutrient-rich solution is added to the cells once they have been removed from the roller bottles. The mixture is then pumped via tubes into bioreactors that resemble thin cassettes and have a perishable mesh system. Finally, the bioreactors are sterilised using an e-beam. The cells cling to the mesh and begin to develop because they flow into the cassettes. For three to four weeks, the cells are flowing back and forth. Every day, old cell suspension is taken out and new nutrition is added. The culture system regulates temperature, oxygen flow, pH, and nutrient flow. The substance breaks down given that the additional cells create a dermal skin layer.

3 Completion of growth cycle: Following the completion of cell development on the mesh since the tissue washed with more nutritious foods liquid.

The the cryoprotectant placed on top. The labelled, individually stored, and frozen cassettes.

Collagen methodology :

- A culture system receives the cells: The fibroblasts receive a small amount the scleroprotein cold and nutritional medium, some mixed twelve-tone scheme response. The liquid is poured into the moulds and allowed to rewarm because as the scleroprotein it heats and gels and binds to it's the fibroblasts, stimulating the development of fresh skin cells .A keratinocyte layered on top: The removed the thawing of keratinocytes and sown upon the developing facial skin after the

scleroprotein has been overlaid to the fibroblasts. Those are left to expand for many days before being uncovered to air, which causes the formation of keratinocytes dermal layers. The fresh body is kept until in sterilized containers. it is needed.

Applications:

1. carcinoma : interactions between cells and with matrices may play a variety of roles in the development and progression of cancer. Due to these factors, using 3D culture models in research of tumour biology has been steadily increasing.

2.Skin conditions and therapeutic uses Skin: For several skin disorders, Currently, reconstructions are being investigated used in hospitals. Among the situations that can enjoy the occurrence of analogues to human skin are skin disorders, xeroderma pigmentosum, keloids, mar, and genodermatoses like vitiligo. The treatment of serious burns and skin conditions makes the most use of homologous skin grafts. Skin loss, surgical wounds, and genodermatoses make up the majority of the most recent clinical indications for skin allografts. the capacity for generate in vitro keratinocytes and the rising practise early wound closure in severely burned patients are two major elements considered required for the usage of skin substitutes in therapeutic applications.

3. pharmacological applications : Drug discovery in the medical field typically depends on the prognosticative power of cell-based tests. During the first stages of drug development and discovery, second monolayer cells refined on plates are the most common way to test the efficacy of anti-cancer medications. Once these medications are evaluated in vivo, however, differences are found. These changes may also be caused by fundamentally distinct cell surface receptors, proliferative dynamics, Cellular density, ECM components, both metabolic processes 2D-maintained cell population. Cadaver body was previously used to transfer drugs research, but its restricted accessibility and substantial variation among specimens there boosted the usefulness models for reconstructing skin. A 3D model is crucial for assessments of irritation, toxicity, and keratinocyte differentiation since it resembles native skin in terms of porosity characteristics and metabolic activity. Some drugs' porosity may be impacted by metabolic activity. The skin reconstruct model has a number of issues, including the absence of sweat glandshair follicles, pilose baceous units, and skin appendages. As a result deficit this kind has much worse barrier qualities other those seen in entire skin. The skin reconstruction model is as a result preferred a monolayer model, but the skin permeation's kinetic parameters learned from these research should the same taken into consideration.

Future scope:

To pioneer organ reconstruction, the medical profession is abusing technology. It is hoped that

someday this dubious engineered skeletal tissue would take the place of prosthetics made of Metal and plastic that are present-day replacement shattered bones and joints. Gristle cells are seeded onto compound mesh to recreate the appearance of ears and noses.

Current laboratory research focuses on the regeneration of breast and channel tissues. Future full-grown kidneys, hearts, and even livers could be made using human tissues thanks to this technology.

CONCLUSION :

Artificial derma allows for early wound closure in patients with severe burns almost as well as moreover, once covered the use of a dermal graft delivers a constant cover which is sufficient as opposed to currently used grafting skin methods. It is a cost-effective procedure because it utilizes grafts from donors that are efficient and left donor areas that recover more quickly.

Contributions from the authors are equal for each.

The authors state that they have no conflicts of interest..

References:

1. Randall M.J., Jünger A., Rimann M., Wuertz-Kozak K. Advances in the biofabrication of 3D skin in vitro: Healthy and pathological models. *Front. Bioeng. Biotechnol.* 2018;6:154. doi: 10.3389/fbioe.2018.00154.
2. Sood A., Granick M.S., Tomaselli N.L. Wound Dressings and Comparative Effectiveness Data. *Adv. Wound Care.* 2014;3:511–529. doi: 10.1089/wound.2012.0401.
3. Dhivya S., Padma V.V., Santhini E. Wound dressing—A review. *BioMedicine.* 2015;5:24–28. doi: 10.7603/s40681-015-0022-9.
4. Laurens N., Koolwijk P., de Maat M.P. Fibrin structure and wound healing. *J. Thromb. Haemost.* 2006;4:932–939.
5. Larouche J., Sheoran S., Maruyama K., Martino M.M. Immune regulation of skin wound healing: Mechanisms and novel therapeutic targets. *Adv. Wound Care.* 2018;7:209–231. doi: 10.1089/wound.2017.0761.
6. Frykberg R.G.C., Banks J. Challenges in the Treatment of Chronic Wounds. *Adv. Wound Care.* 2015;4:560–582. doi: 10.1089/wound.2015.0635.
7. Jaller J.A., Herskovitz I., Borda L.J., Mervis J., Darwin E., Hirt P.A., Lev-Tov H., Kirsner R.S. Evaluation of Donor Site Pain after Fractional Autologous Full-Thickness Skin Grafting. *Adv. Wound Care.* 2018;7:309–314.

8. I. V. Yannas, J. F. Burke, P. L. Gordon, and C. Huang, "Multilayer membrane useful as synthetic skin," US patent
9. McGrath J.A, Eady R.A, Pope F.M. (2004). Rook's Textbook of Dermatology (7th ed.). Blackwell Publishing. pp. 3.1–3.6. ISBN 978-0- 632-06429-8.
10. Godin, B., and Touitou, E. (2007). Transdermal skin delivery: Predictions for humans from in vivo, ex vivo and animal models. *Adv. Drug Deliv. Rev.* 59, 1152– 1161.
11. Sheridan RL, Moreno C. Skin substitutes in burns. *Burns*. 2001.
12. Victoria Tang, Thomas Mak, Louise Tsang, Zero Wong, Iris Ting .Artificial skin.2010.